



National
Comprehensive
Cancer
Network®

NCCN Clinical Practice Guidelines in Oncology (NCCN Guidelines®)

Central Nervous System Cancers

Version 2.2018 — November 26, 2018

NCCN.org

Continue



NCCN Guidelines Version 2.2018

Central Nervous System Cancers

***Louis Burt Nabors, MD** Ψ/Chair
University of Alabama at Birmingham
Comprehensive Cancer Center

***Jana Portnow, MD** † Ψ/Vice-chair
City of Hope Comprehensive Cancer Center

Joachim Baehring, MD Ψ
Yale Cancer Center/Smilow Cancer Hospital

Henry Brem, MD ¶ Ψ
The Sidney Kimmel Comprehensive
Cancer Center at Johns Hopkins

Nicholas Butowski, MD Ψ †
UCSF Helen Diller Family
Comprehensive Cancer Center

Peter Forsyth, MD Ψ
Moffitt Cancer Center

Jona Hattangadi-Gluth, MD §
UC San Diego Moores Cancer Center

Matthias Holdhoff, MD, PhD †
The Sidney Kimmel Comprehensive
Cancer Center at Johns Hopkins

Craig Horbinski, MD, PhD ≠
Robert H. Lurie Comprehensive Cancer
Center of Northwestern University

Steven Howard, MD §
University of Wisconsin Carbone Cancer Center

Larry Junck, MD Ψ
University of Michigan
Comprehensive Cancer Center

Thomas Kaley, MD Ψ
Memorial Sloan Kettering Cancer Center

Priya Kumthekar, MD Ψ
Robert H. Lurie Comprehensive Cancer Center of
Northwestern University

Jay S. Loeffler, MD § Ψ
Dana-Farber/Brigham and Women's Cancer Center/
Massachusetts General Hospital Cancer Center

Paul L. Moots, MD Ψ
Vanderbilt-Ingram Cancer Center

Maciej M. Mrugala, MD, PhD, MPH Ψ †
Mayo Clinic Cancer Center

Seema Nagpal, MD †
Stanford Cancer Institute

Manjari Pandey, MD †
St. Jude Children's Research Hospital/
The University of Tennessee Health Science Center

Ian Parney, MD, PhD Ψ ¶
Mayo Clinic Cancer Center

Katherine Peters, MD, PhD Ψ
Duke Cancer Institute

Dheerendra Prasad, MD Ψ § ¶
Roswell Park Comprehensive Cancer Center

Vinay K. Puduvalli, MD Ψ
The Ohio State University Comprehensive Cancer
Center - James Cancer Hospital and Solove
Research Institute

John Ragsdale, III, MD ¶
Duke Cancer Institute

Jason Rockhill, MD, PhD §
Fred Hutchinson Cancer Research Center/
Seattle Cancer Care Alliance

Lisa Rogers, DO Ψ
Case Comprehensive Cancer Center/
University Hospitals Seidman Cancer Center
and Cleveland Clinic Taussig Cancer Institute

Chad Rusthoven, MD §
University of Colorado Cancer Center

Nicole Shonka, MD † Ψ
Fred & Pamela Buffet Cancer Center

Dennis C. Shrieve, MD, PhD §
Huntsman Cancer Institute at the University of
Utah

Allen K. Sills, Jr., MD ¶
Vanderbilt-Ingram Cancer Center

Lode J. Swinnen, MB, ChB ‡
The Sidney Kimmel Comprehensive Cancer
Center at Johns Hopkins

Christina Tsien §
Siteman Cancer Center at Barnes-Jewish
Hospital and Washington University School of
Medicine

Stephanie Weiss, MD §
Fox Chase Cancer Center

Patrick Yung Wen, MD Ψ
Dana-Farber/Brigham and Women's Cancer
Center

Nicole Willmarth, PhD ¥
American Brain Tumor Association

NCCN
Mary Anne Bergman
Susan Darlow, PhD

[NCCN Guidelines Panel Disclosures](#)

Continue

† Medical oncology	¶ Surgery/Surgical oncology
‡ Hematology/Hematology oncology	≠ Pathology
§ Radiotherapy/Radiation oncology	Ⓟ Internal medicine/Primary care
Ψ Neurology/Neuro-oncology	¥ Patient Advocacy
	* Discussion Section Writing Committee



NCCN Guidelines Version 2.2018 Central Nervous System Cancers

Meningiomas

Thomas Kaley, MD/Lead †
Memorial Sloan Kettering Cancer Center

Henry Brem, MD † ‡
The Sidney Kimmel Comprehensive
Cancer Center at Johns Hopkins

Larry Junck, MD †
University of Michigan Comprehensive
Cancer Center

Jay S. Loeffler, MD § †
Dana-Farber/Brigham and Women's Cancer
Center/Massachusetts General Hospital
Cancer Center

Paul L. Moots, MD †
Vanderbilt-Ingram Cancer Center

Allen K. Sills, Jr., MD † ‡
Vanderbilt-Ingram Cancer Center

Metastatic Spine Tumors

Dennis C. Shrieve, MD, PhD §
Huntsman Cancer Institute
at the University of Utah

Jona Hattangadi-Gluth, MD §
UC San Diego Moores Cancer Center

Allen K. Sills, Jr., MD † ‡
Vanderbilt-Ingram Cancer Center

PCNSL Review

Maciej Mrugala, MD, PhD, MPH/Lead † ‡
Mayo Clinic Cancer Center

Lode J. Swinnen, MB, ChB ‡
The Sidney Kimmel Comprehensive
Cancer Center at Johns Hopkins

Thomas Kaley, MD †
Memorial Sloan Kettering Cancer Center

Matthias Holdhoff, MD, PhD †
The Sidney Kimmel Comprehensive
Cancer Center at Johns Hopkins

Adult Medulloblastoma

Maciej Mrugala, MD, PhD, MPH † ‡
Mayo Clinic Cancer Center

Jana Portnow, MD † ‡
City of Hope Comprehensive
Cancer Center



NCCN Guidelines Version 2.2018 Central Nervous System Cancers

[NCCN Guidelines Index](#)
[Table of Contents](#)
[Discussion](#)

Principles of Imaging

Larry Junck, MD Ψ
University of Michigan
Comprehensive Cancer Center

Louis Burt Nabors, MD Ψ
University of Alabama at Birmingham
Comprehensive Cancer Center

Principles of Brain Tumor Pathology

Craig Horbinski, MD, PhD ≠
Robert H. Lurie Comprehensive
Cancer Center of Northwestern
University

Allen K. Sills, Jr., MD ¶¶
Vanderbilt-Ingram Cancer Center

Principles of Systemic Therapy

Louis Burt Nabors, MD/Lead Ψ
University of Alabama at Birmingham
Comprehensive Cancer Center

Matthias Holdhoff, MD PhD †
The Sidney Kimmel Comprehensive
Cancer Center at Johns Hopkins

Larry Junck, MD Ψ
University of Michigan
Comprehensive Cancer Center

Maciej Mrugala, MD, PhD, MPH Ψ †
Mayo Clinic Cancer Center

Jana Portnow, MD † Ψ
City of Hope Comprehensive Cancer
Center

Lode J. Swinnen, MB, ChB ‡
The Sidney Kimmel Comprehensive
Cancer Center at Johns Hopkins

Patrick Yung Wen, MD Ψ
Dana-Farber/Brigham and Women's
Cancer Center

Principles of Radiation Therapy

Christina Tsien, MD §
Siteman Cancer Center at Barnes-
Jewish Hospital and Washington
University School of Medicine

Larry Junck, MD Ψ
University of Michigan
Comprehensive Cancer Center

Jay J. Loeffler, MD § Ψ
Dana-Farber/Brigham and Women's
Cancer Center | Massachusetts
General Hospital Cancer Center

Dennis C. Shrieve, MD, PhD §
Huntsman Cancer Institute
at the University of Utah

Allen K. Sills, Jr., MD ¶¶
Vanderbilt-Ingram Cancer Center

[NCCN Guidelines Panel Disclosures](#)

Continue

† Medical oncology
‡ Hematology/Hematology oncology
§ Radiotherapy/Radiation oncology
Ψ Neurology/neuro-oncology
¶¶ Surgery/Surgical oncology
≠ Pathology
¥ Patient advocacy



[NCCN Central Nervous System Cancers Panel Members](#)
[NCCN Central Nervous System Cancer Sub-Committee Members](#)
[Summary of the Guidelines Updates](#)

[Adult Low-Grade \(WHO Grade II\) Infiltrative Supratentorial Astrocytoma/
Oligodendroglioma \(ASTR-1\)](#)
[Anaplastic Gliomas/Glioblastoma \(GLIO-1\)](#)
[Adult Intracranial and Spinal Ependymoma \(Excluding Subependymoma\) \(EPEN-1\)](#)
[Adult Medulloblastoma \(AMED-1\)](#)
[Primary CNS Lymphoma \(PCNS-1\)](#)
[Primary Spinal Cord Tumors \(PSCT-1\)](#)
[Meningiomas \(MENI-1\)](#)
[Limited Brain Metastases \(LTD-1\)](#)
[Extensive Brain Metastases \(MU-1\)](#)
[Leptomeningeal Metastases \(LEPT-1\)](#)
[Metastatic Spine Tumors \(SPINE-1\)](#)

Principles of:

- [Brain and Spine Tumor Imaging \(BRAIN-A\)](#)
- [Brain Tumor Surgery \(BRAIN-B\)](#)
- [Brain and Spinal Cord Tumor Radiation Therapy \(BRAIN-C\)](#)
- [Brain and Spinal Cord Tumor Systemic Therapy \(BRAIN-D\)](#)
- [Brain and Spine Tumor Management \(BRAIN-E\)](#)
- [Brain Tumor Pathology \(BRAIN-F\)](#)

Clinical Trials: NCCN believes that the best management for any patient with cancer is in a clinical trial. Participation in clinical trials is especially encouraged.

To find clinical trials online at NCCN Member Institutions, [click here: nccn.org/clinical_trials/clinicians.aspx](#).

NCCN Categories of Evidence and Consensus: All recommendations are category 2A unless otherwise indicated.

See [NCCN Categories of Evidence and Consensus](#).

The NCCN Guidelines® are a statement of evidence and consensus of the authors regarding their views of currently accepted approaches to treatment. Any clinician seeking to apply or consult the NCCN Guidelines is expected to use independent medical judgment in the context of individual clinical circumstances to determine any patient's care or treatment. The National Comprehensive Cancer Network® (NCCN®) makes no representations or warranties of any kind regarding their content, use or application and disclaims any responsibility for their application or use in any way. The NCCN Guidelines are copyrighted by National Comprehensive Cancer Network®. All rights reserved. The NCCN Guidelines and the illustrations herein may not be reproduced in any form without the express written permission of NCCN. ©2018.



NCCN Guidelines Version 2.2018

Central Nervous System Cancers

Updates in Version 2.2018 of the NCCN Guidelines for Central Nervous System Cancers from Version 1.2018 include:

[MS-1](#)

- The Overview and Gliomas sections of the Discussion have been updated to reflect the changes in the algorithm.

Updates in Version 1.2018 of the NCCN Guidelines for Central Nervous System Cancers from Version 1.2017 include:

GLOBAL: "*Consider clinical trial (preferred for eligible patients)*" has been included throughout the guideline.

[ASTR-1](#)

Title Page

- Modified: "Adult Low-Grade (*WHO Grade II*) Infiltrative Supratentorial Astrocytoma/Oligodendroglioma (*Excluding Pilocytic Astrocytoma*).¹" Also for (ASTRA-2).

Clinical Impression

- "Observation" has been deleted as an option for management.

Surgery

- Removed footnote "a" from "Subtotal resection" and added to column title.

Adjuvant Treatment

- Low-risk arm: Deleted "Fractionated external beam RT (category 2B) or Chemotherapy (category 2B)"
- High-risk arm: "*in highly select patients*" has been added to "Observe."

Footnotes

- "*In the event that other risk factors are considered and treatment is warranted, treat as high-risk. There may also be rare circumstances in which treating a patient with fractionated external beam RT alone (category 2B) or chemotherapy alone (category 2B) may be considered. See Principles of Brain and Spinal Cord Tumor Radiation (BRAIN-C) or Principles of Brain and Spinal Cord Tumor Systemic Therapy (BRAIN-D)*" is a new footnote corresponding to "observe"
- "Surgery is generally recommended, but serial observations are appropriate for selected patients" has been removed from "MRI compatible with low-grade glioma."
- "f" modified to include, "*Recommended molecular diagnostics include 1p19q chromosomal status and IDH1/2 mutation status, See Principles of Brain Tumor Pathology (BRAIN-F)*." Also for (ASTRA-2).
- "i" modified as follows, "High-risk features: >40 y or subtotal resection (STR). *Other high-risk factors that are sometimes taken into consideration are tumor size, neurologic deficits and presence of sequencing verified IDH wild type.*"
- Removed footnote from "Observe" in the low-risk pathway: "If GTR is achieved, consider further observation."

[ASTR-2](#)

Footnotes

- "o": Last sentence has been modified as follows, "For *treatment* of patients with transformation to high-grade disease, [see GLIO-1](#)."

[GLIO-1](#)

Surgery

- Removed "± carmustine (BCNU) wafer (category 2B)" from "Maximal safe resection" pathway.

Footnotes

- "h" modified: "*Consider carmustine (BCNU) wafer implant during maximal safe resection (category 2B)*. Treatment with carmustine wafer may impact enrollment in adjuvant clinical trials."
- "k": "NOS *The 2016 WHO Classification of Tumors of the CNS* has deleted *oligoastrocytoma* as a category, although it *'anaplastic oligoastrocytoma, NOS'* may continue to be used for ~~some patients~~ *1) patients with mixed histology and no available molecular data (ie, no tissue available for analysis) for determining whether to classify as oligodendroglioma versus astrocytoma; or 2) rare instances in which the tumor has regions with histologic features of oligoastrocytoma with 1p19q-codeletion, and distinct regions with histologic features of astrocytoma without 1p19q-codeletion.* (Also for GLIO-2 and GLIO-5A).

[Continued](#)



NCCN Guidelines Version 2.2018

Central Nervous System Cancers

Updates in Version 1.2018 of the NCCN Guidelines for Central Nervous System Cancers from Version 1.2017 include:

GLIO-2

Pathology, modified as follows:

- Anaplastic astrocytoma, Anaplastic oligoastrocytoma, NOS (Also for GLIO-5)

Adjuvant Treatment, modified as follows:

- Anaplastic oligodendroglioma (1p19q codeleted):
 - ▶ Fractionated external beam RT with neoadjuvant and adjuvant PCV chemotherapy (category 1)
 - ▶ Fractionated external beam RT with concurrent and adjuvant temozolomide chemotherapy
- Anaplastic astrocytoma, Anaplastic oligoastrocytoma, NOS:
 - ▶ Fractionated external beam RT followed by adjuvant temozolomide
 - ▶ Fractionated external beam RT with concurrent and adjuvant temozolomide chemotherapy
 - ▶ Fractionated external beam RT
- Anaplastic gliomas Poor performance status (KPS <60):
 - ▶ PCV or Temozolomide chemotherapy (category 2B)

Footnotes

- "Consider temozolomide if tumor is MGMT promoter methylated" is a new footnote corresponding to "Temozolomide (category 2B)" for Anaplastic gliomas Poor performance status (KPS <60).

GLIO-3

Glioblastoma Pathology

- Modified: "Age >70 y Glioblastoma ± carmustine (BCNU) wafer"

Adjuvant Treatment

- For MGMT promoter methylated and unmethylated or indeterminate: Standard brain RT + concurrent temozolomide and adjuvant temozolomide + alternating electric field therapy are *category 1* designations. (Also for GLIO-4)
- Poor performance status (KPS <60)
 - ▶ Removed "Standard Brain RT"
 - ▶ Amended the option: "Hypofractionated RT (*preferred*) ± concurrent or adjuvant TMZ"

Footnotes

- "q": Removed: "Treatment with carmustine wafer, reirradiation, or multiple prior systemic therapies may impact enrollment in some adjuvant clinical trials." (Also for GLIO-4A)
- "s" modified: "Benefit of treatment with temozolomide for glioblastomas beyond 6 months is unknown. The optimal duration of treatment with temozolomide for anaplastic astrocytoma is unknown." (Also for GLIO-4A)
- "o" modified: "Consider temozolomide monotherapy is only recommended if tumor is MGMT promoter methylated." (Also for GLIO-4A)

GLIO-4

Glioblastoma Pathology

- Modified: "Age >70 y Glioblastoma ± carmustine (BCNU) wafer"

Adjuvant Treatment

- For MGMT promoter methylated and unmethylated or indeterminate: the (category 1) designation for Hypofractionated brain RT alone has been deleted.
- MGMT promoter methylated arm: Hypofractionated brain RT + concurrent and adjuvant temozolomide is a category 1 designation.
- MGMT promoter unmethylated or indeterminate: "Hypofractionated brain RT + concurrent and adjuvant temozolomide" is new to this pathway.

Follow-up

- Modified: "Brain MRI 2–6 wk after RT, then every 2–4 mo for 3 y, then every 6 mo through 5 y post-treatment, then yearly indefinitely."

GLIO-5

Recurrence

- Local resectable, modified as follows: the following upper and lower pathways have been deleted: "Resection + carmustine (BCNU) wafer" and "Resection without carmustine (BCNU) wafer"
- For local resectable, options now include "Consider clinical trial or Resection"

Footnotes

- To "Resection" for local resectable, added: "Consider carmustine (BCNU) wafer implant during resection. Treatment with carmustine wafer may impact enrollment in clinical trials."
- "w" modified: "The efficacy of standard-of-care treatment for recurrent glioblastoma is suboptimal, so for eligible patients consideration of clinical trials is highly encouraged. Prior treatment may impact enrollment in the majority of clinical trials options."

EPEN-1

Pathology

- Intracranial ependymoma modified to include, "(supratentorial, posterior fossa)"

EPEN-4

Follow-up

- 2nd bullet modified as follows: "Imaging of neuroaxis of tumor site (brain or spine MRI) every 3–4 mo for 1 y, then every 4–6 mo for year 2, then every 6–12 mo for 5–10 y, then as clinically indicated indefinitely"

[Continued](#)



NCCN Guidelines Version 2.2018

Central Nervous System Cancers

Updates in Version 1.2018 of the NCCN Guidelines for Central Nervous System Cancers from Version 1.2017 include:

AMED-1

Footnotes

- "a": "Excluding esthesioneuroblastoma" (corresponding to the title of the page, Adult Medulloblastoma) deleted on AMED-1, AMED-2, and AMED-3.

AMED-2

Postoperative Staging

- Statement modified: "Brain and spine MRI and CSF analysis, *and molecular analysis*"
- Definition of "High risk for recurrence" modified: "Supratentorial location" deleted.

Footnotes

- "*Molecular profiling to identify clinically relevant subtypes is recommended to encourage opportunities for clinical trial involvement. See Principles of Pathology (BRAIN-F)*" is new to the page, corresponding to *molecular analysis*.

AMED-3

Follow-up

- Brain MRI modified: "every 3 mo for 2 y; then every 6–12 mo for 5–10 y; then as *clinically indicated at least yearly indefinitely*. For patients with previous spine disease, concurrent spine imaging as clinically indicated."

Clinical Staging

- Modified as follows: "Brain and spine MRI, CSF analysis, ~~Bone scan, Contrast-enhanced CT scans of chest, abdomen, and pelvis, Bone marrow biopsy~~"

Footnotes

- "r" modified: "If As clinically indicated, *consider bone scan; contrast-enhanced CT scans of chest, abdomen, and pelvis; and/or bone marrow biopsy. If patient was treated with radiation only at diagnosis, then a bone scan should be part of restaging imaging at time of recurrence, even if patient is asymptomatic.*"

PCNS-1

Footnotes

- "*For additional guidance on management of transplant recipients, see NCCN Guidelines for Diffuse Large B-Cell Lymphoma, sub-algorithm for Post-Transplant Lymphoproliferative Disorders*" is a new footnote corresponding to the title, Primary CNS Lymphoma.
- "e" modified, "*Brain biopsy is recommended as the primary procedure to obtain diagnosis. CSF should be obtained promptly. CSF analysis should include flow cytometry and CSF cytology and possibly gene rearrangements. If there is unequivocal evidence of PCNS lymphoma based on CSF and imaging, then brain biopsy may not be needed. Otherwise*

PCNS-2

Induction Therapy

- Under "High-dose methotrexate-based regimen", 1st bullet deleted: "If CSF positive or spinal MRI positive, and not responding to systemic chemotherapy, consider intra-CSF chemotherapy (category 2B)"
- Under "High-dose methotrexate-based regimen", 2nd bullet modified: "If eye exam shows vitreous involvement and *disease is not responding to systemic chemotherapy, consider RT to globe or and refer to neuro-ophthalmology for intraocular chemotherapy (category 2B).*"

Consolidation Therapy

- 1st pathway modified: "If complete response *or complete response unconfirmed (CRu)* consider:"

PCNS-2

Footnotes

- "o" modified, "*If CSF positive or spinal MRI positive, consider alternative systemic chemotherapy regimens and/or intra-CSF chemotherapy (category 2B), especially for patients who cannot tolerate systemic methotrexate ≥ 3 g/m².*"
- "q": "*For CRu criteria, see: Abrey LE, et al. Report of an international workshop to standardize baseline evaluation and response criteria for primary CNS lymphoma. J Clin Oncol 2005;23:5034-5043.*"

PCNS-3

Relapsed or Refractory Primary CNS Lymphoma

- A new pathway was added: "*Any type of treatment history*" leading to "*Consider clinical trial.*"

Treatment

- 1st treatment option for patients with, "Prior high-dose methotrexate-based regimen without prior RT", "Previous response with long duration (≥ 12 mo)", modified: "Re-treat with high-dose methotrexate \pm *other chemotherapy.*"

PSCT-1

Surgery

- MRI well-defined/circumscribed, asymptomatic/symptomatic, "spine MRI has been modified to include "*Postoperative*" spine MRI." (Also for PSCT-3).

PSCT-2

Pathology

- The following has been deleted: "Infiltrative glioma [See Adult Low-Grade Infiltrative Supratentorial Astrocytoma Oligodendroglioma \(ASTR-1\)](#) and Anaplastic Gliomas/Glioblastoma (GLIO-1)"



NCCN Guidelines Version 2.2018

Central Nervous System Cancers

Updates in Version 1.2018 of the NCCN Guidelines for Central Nervous System Cancers from Version 1.2017 include:

[MENI-1](#)

- This page has been extensively revised.

[MENI-2](#)

[Follow-Up](#)

- Modified: "WHO Grade I and II or unresected meningiomas: Brain MRI at 3, 6, and 12 mo, then every 6–12 mo for 5 y, then every 1–3 y *as clinically indicated indefinitely*"

[Footnotes](#)

- Footnote associated with f/u imaging was deleted: "Recommend imaging if cause/symptomatic change at any time."

[LTD-1](#)

- This page has been extensively revised.
- The title of this section has been revised, "Limited (~~4-3~~) Brain Metastases."

[Footnotes](#)

- New footnote "c" to define "Limited brain metastases": "*Limited' brain metastases defines a group of patients for whom SRS is equally effective and offers significant cognitive protection compared with WBRT. The definition of "limited" brain metastases in terms of number of metastases or total intracranial disease volume is evolving and may depend on the specific clinical situation. (Yamamoto M, et al. Stereotactic radiosurgery for patients with multiple brain metastases (JLJK0901):...*" (Also for LTD-3)

[LTD-2](#)

[Clinical Presentation](#)

- The pathway for "Newly diagnosed or stable systemic disease or Reasonable systemic treatment options exist" was significantly revised.

[Footnotes](#)

- Due to changes on LTD-1, "c" was deleted: "Consider surgery to relieve mass effect."
- "g": If an active agent exists (eg, cytotoxic, targeted, or immune modulating), trial of systemic therapy with good CNS penetration may be considered in select patients (eg, *for patients with small asymptomatic brain metastases from melanoma or ALK rearrangement positive NSCLC*); *it is reasonable to hold on treating with radiation to see if systemic therapy can control the brain metastases. See Principles of Brain and Spinal cord Tumor Systemic Therapy (BRAIN-D).*
- "i": Modified the first sentence: "SRS is preferred when safe, especially for low tumor volume, *to both the resection cavity and any other non-resected brain metastases.*" WBRT is generally.....
- "j": Modified the first sentence: "*For brain metastases not managed with resection, SRS + WBRT is generally not recommended but may be appropriate in some rare clinical circumstances.*"

[LTD-3](#)

[Recurrence](#)

- Bottom pathway modified: "~~4-3 lesions~~ *Limited brain metastases* and ~~>3 lesions~~ *Extensive brain metastases.*"

[Treatment](#)

- Pathway off "Previous surgery only" modified: "WBRT for large volumes (eg, ~~diameter >3cm~~)." (Also for "Limited brain metastases" pathway).

[MU-1](#)

- This page has been extensively revised.
- The title of this section has been revised, "~~Multiple (>3)~~ *Extensive Brain Metastases.*"

[Footnotes](#)

- New footnote "c" to define "Extensive brain metastases": "Includes all cases that do not fit the definition of "limited brain metastases" on LTD-1."

[LEPT-1](#)

[Footnotes](#)

- "d" modified: "CSF analysis should include: cell count, differential, glucose, and protein. For solid malignancies, order cytopathology. *When available, assessment of circulating tumor cells (CTC), increases sensitivity of tumor cell detection and assessment of response to treatment.* For hematologic malignancies, use flow cytometry."

[LEPT-2](#)

[Treatment](#)

- Top pathway modified: "Consider involved-field RT to *neurologically symptomatic or painful sites for palliation (including spine and intracranial disease)*"
- Bottom pathway modified: "WBRT and/or involved-field RT to bulky disease and *neurologically symptomatic or painful sites (including spine and intracranial disease)*"

[LEPT-3](#)

- 1st column modified: "~~Strongly~~ Consider CSF flow scan."

[Footnotes](#)

- "i" modified: "Highly recommended *if symptoms or conventional imaging suggests CSF flow blockage.* ~~to ensure patency of CSF flow if intraventricular catheter was placed.~~"

[Continued](#)

Updates in Version 1.2018 of the NCCN Guidelines for Central Nervous System Cancers from Version 1.2017 include:

[LEPT-4](#)

Treatment

- Modified recommendation for CSF cytology negative pathway: "Continue on current regimen and re-evaluate CSF cytology every 4–8 weeks on a monthly basis"
- Modified top pathway: "Maintenance intrathecal chemotherapy and Monitor CSF cytology every 4–8 weeks."

[SPINE-2](#)

Footnotes

- Deleted footnote to "Surgery": "Postoperative brain MRI within 24–72 hours. (See [BRAIN-A](#))."
- "m" modified: "Postoperative spine MRI should be delayed by at least 2–3 weeks to avoid post-surgical artifacts. See [Principles of Brain Tumor Surgery \(BRAIN-B\)](#)" (Also for SPINE-3).

[BRAIN-C \(1 of 4\)](#)

Low-Grade Gliomas (Grades I/II)

- 1st bullet modified: "Tumor volumes are best defined using pre- and postoperative imaging, usually fluid-attenuated inversion recovery (FLAIR) and/or T2 signal abnormality on MRI for gross tumor volume (GTV). Clinical target volume (CTV) (GTV plus 1–2 cm margin) should receive 45–54 Gy in 1.8–2.0 Gy fractions. Consider RT dose escalation to 59.4–60 Gy for IDH-wildtype low-grade gliomas, as these patients may have a more aggressive course of disease."

High-Grade Gliomas (Grades III/IV)

- 1st bullet modified: "The GTV is best defined using pre- and postoperative MRI imaging using enhanced T1 and FLAIR/T2. To account for sub-diagnostic tumor infiltration, the GTV is expanded 1–2 cm (CTV) for grade III, and up to 2–2.5 cm (CTV) for grade IV. Although trials in GBM have historically used CTV expansion in the range of 2 cm, smaller CTV expansions are supported in the literature and can be appropriate. A PTV of margin of 3–5 mm is typically added to the CTV to account for daily setup errors and image registration. Daily image guidance is required if smaller PTV margins are used. When edema as assessed by T2/FLAIR is included in an initial phase of treatment, fields are usually reduced for the last phase of the treatment (boost). The boost target volume will typically encompass only the gross residual tumor and the resection cavity. A range of acceptable clinical target volume margins exists. Both strategies appear to produce similar outcomes."

[Ependymoma](#)

- 2nd bullet modified: "Craniospinal: To reduce toxicity from craniospinal irradiation in adults, consider the use of intensity-modulated radiotherapy or protons if available. Whole brain and spine (to bottom of thecal sac) receive 36 Gy in 1.8 Gy fractions, followed by limited field to spine lesions to 45 Gy. (Gross metastatic lesions below the conus could receive higher doses of 54–60 Gy). Primary intracranial site should receive total dose of 54–59.4 Gy in 1.8–2.0 Gy fractions. Consider boosting any gross intracranial metastatic sites to a higher dose while respecting normal tissue tolerances."

[BRAIN-C \(3 of 4\)](#)

Brain Metastases

- 1st bullet modified: "Whole brain radiotherapy (WBRT): Doses vary between 20 and 40 Gy delivered in 5–20 fractions. The standard regimens include 30 Gy in 10 fractions or 37.5 Gy in 15 fractions. Nevertheless 20 Gy in 5 fractions is a good option in poor performers. For better prognosis patients consider memantine during and after WBRT for a total of 6 months."

Metastatic Spine

- 2nd bullet new to the page: "Stereotactic radiation approaches (SRS/SBRT) for spinal cases may be preferred for patients with oligometastatic disease where tumor ablation is a goal of treatment and in tumors considered radioresistant (eg, renal cell, melanoma, sarcoma, hepatocellular, and some colorectal and NSCLC cases). Stereotactic radiation may also be preferred in the setting of tumor recurrence after prior radiation as a strategy to limit radiation dose to the spinal cord or other critical structures. Careful adherence to consensus guidelines for radiosurgery planning and delivery is recommended."

[Continued](#)



NCCN Guidelines Version 2.2018

Central Nervous System Cancers

Updates in Version 1.2018 of the NCCN Guidelines for Central Nervous System Cancers from Version 1.2017 include:

[BRAIN-D \(1 of 8\)](#)

Adult Low-Grade Infiltrative Supratentorial Astrocytoma/Oligodendroglioma (excluding pilocytic astrocytoma)

- Adjuvant Treatment: For low-risk patients:
 - ▶ Modified: "Combination PCV (procarbazine + lomustine + vincristine) (category 1)"

Anaplastic Gliomas (Changes in this section were made to match GLIO-2)

- Adjuvant Treatment
 - ▶ *Anaplastic Oligodendroglioma (1p19q co-deleted) (KPS ≥60)*
 - ◊ RT with neoadjuvant PCV
 - ◊ RT with adjuvant PCV
 - ◊ RT with concurrent TMZ (75 mg/m² daily) and adjuvant TMZ
 - ▶ *Anaplastic astrocytoma/anaplastic oligoastrocytoma, NOS (KPS ≥60)*
 - ◊ RT followed by adjuvant TMZ (12 cycles)
 - ◊ RT with concurrent TMZ and adjuvant TMZ
 - ◊ RT with neoadjuvant PCV
 - ◊ RT with adjuvant PCV
 - ▶ *Anaplastic gliomas (KPS <60):*
 - ◊ Temozolomide (category 2B)

[BRAIN-D \(2 of 8\)](#)

Meningiomas

- Added: "Bevacizumab + everolimus" (category 2B)

[BRAIN-D \(3 of 8\)](#)

Primary CNS Lymphoma

- Induction Therapy, modified as follows:
 - ▶ Systemic therapy
 - ◊ High-dose methotrexate 8 g/m² combined with the following: ~~plus~~ deferred RT
 - Rituximab
 - Rituximab and temozolomide
 - ▶ Consider urgent glucarpidase (carboxypeptidase G2) for prolonged methotrexate clearance due to methotrexate-induced renal toxicity, is now a footnote.
 - ◊ High-dose methotrexate 3.5 g/m² combined with the following, *and consider plus WBRT:*
 - Vincristine, procarbazine, ~~cytarabine ±~~ and rituximab (R-MPV)
 - Temozolomide + rituximab followed by post RT temozolomide

Primary CNS Lymphoma, continued

- Induction Therapy, modified as follows:
 - Cytarabine
 - Ifosfamide ± RT
- Intra-CSF therapy, modified as follows:
 - ▶ Methotrexate
 - ▶ Liposomal ara-c—Cytarabine
 - ▶ Thiotepa
 - ▶ Rituximab
- Consolidation Therapy
 - ▶ High-dose chemotherapy with stem cell rescue
 - ◊ Carmustine + thiotepa
 - ◊ Thiotepa, busulfan, and cyclophosphamide) (TBC)
 - ▶ High-dose cytarabine ± etoposide (EA)
 - ▶ High-dose cytarabine
- Relapsed or Refractory Disease, modified as follows:
 - ▶ Retreat with high-dose methotrexate *with or without rituximab*
 - ▶ Ibrutinib
 - ▶ Lenalidomide *with or without rituximab*
 - ▶ Consider high-dose chemotherapy with autologous stem cell reinfusion in ~~eligible patients who achieve a CR with conventional doses of~~ chemotherapy

[BRAIN-D \(4 of 8\)](#)

Brain Metastases, modified as follows:

- Newly Diagnosed
 - ▶ BRAF/MEK inhibitor combination (melanoma):
 - ◊ Vemurafenib/cobimetinib (category 2B)
 - ◊ Dabrafenib/trametinib
 - ▶ Ipilimumab + nivolumab (melanoma)
 - ▶ Pembrolizumab (melanoma or non-small cell lung cancer)
 - ▶ Alectinib (ALK rearrangement-positive NSCLC)

[Continued](#)

Updates in Version 1.2018 of the NCCN Guidelines for Central Nervous System Cancers from Version 1.2017 include:

BRAIN-D (4 of 8)

• Recurrent Disease

- ▶ Treatment as per the regimens of the primary tumor
- ▶ *Capecitabine + Neratinib (breast)*
- ▶ *Paclitaxel + Neratinib (breast) (category 2B)*
- ▶ *BRAF/MEK inhibitor combination therapy (melanoma):*
 - ◊ *Vemurafenib/cobimetinib*
 - ◊ *Dabrafenib/trametinib*

• Ceritinib, alectinib, *brigatinib* (ALK rearrangement-positive NSCLC)

Footnote: corresponding to vemurafenib/cobimetinib new to page.

- *Although there are no published prospective studies on the combination of vemurafenib and cobimetinib for melanoma patients with brain metastases, there is high-quality evidence that for melanoma with distant metastasis combination therapy with vemurafenib and cobimetinib is associated with improved outcomes and safety compared with single-agent vemurafenib.*

Leptomeningeal Metastases, modified as follows:

• Treatment

- ▶ *Systemic therapy specific to primary cancer type; emphasizing drugs with good CNS penetration*
- ▶ Intra-CSF chemotherapy
 - ◊ ~~Liposomal~~ cytarabine (lymphoma/leukemias)

BRAIN-E (1 of 3)

Multidisciplinary Care

- 1st bullet modified: "During the course of their treatment, most patients will be seen by *multiple subspecialists*. *Close and regular communication among all providers across disciplines is essential. Utilization of brain tumor board or multidisciplinary clinic care models facilitates interactions among multiple subspecialists, ideally including allied health services (physical, occupational and speech therapies, nursing, psychology, social work) for optimizing treatment plan recommendations. physicians from more than one specialty. Where possible, use of a local brain tumor board, or multidisciplinary clinic, facilitates these interactions and allows for input from each of the major neuro-oncology disciplines, as well as allied services (eg, physical/occupational therapy, social work, psychology, nursing) when available, in formulating a plan of care for the patient. When not possible in a single clinic or institution, close and regular communication between the various disciplines involved becomes essential.*"

BRAIN-E (1 of 3)

Multidisciplinary Care, (continued)

- 4th bullet modified: "~~Throughout treatment the patient's quality of life should remain the highest priority and guide clinical decision-making. As the patient's treatment unfolds, their quality of life is the highest priority and should guide clinical decisions.~~ While responses on imaging are benchmarks of *successful successive* therapy, other indicators of success such as overall well-being, function in day-to-day activities, social and family interactions, nutrition, pain control, long-term consequences of treatment, and psychological issues must be considered."
- 6th bullet is new to the page: *For patients with spine tumors, it is important to assemble a multidisciplinary team to integrate diagnosis, treatment, symptom management, and rehabilitation. Patients with spine tumors have complex physical, psychological, and social care needs and optimal management requires a multidisciplinary team including the following expertise: medical and radiation oncology, surgical specialties (ie, neurosurgery, orthopedic surgery, surgical oncology), radiology, interventionalists, pain specialists, bowel and bladder care, back care, and ambulatory support, physical therapy, psychological and/or social services, nutritional support. Early integration of palliative care and pain management is strongly recommended. [See NCCN Guidelines for Palliative Care and NCCN Guidelines for Adult Cancer Pain.](#)*

[Continued](#)



NCCN Guidelines Version 2.2018

Central Nervous System Cancers

Updates in Version 1.2018 of the NCCN Guidelines for Central Nervous System Cancers from Version 1.2017 include:

[BRAIN-E \(2 of 3\)](#)

Medical Management

- New sub-title: *Mass Effect, Brain Edema, Radiation Necrosis Corticosteroids*
- 10th sentence new to page: "*Consider short-course bevacizumab for management of symptoms driven by RT necrosis, poorly controlled vasogenic edema, or mass effect in patients with brain metastases and primary brain tumors, particularly those with deep-seated unresectable tumors, as it may allow overall quality-of-life improvements by reducing steroid dose and improving functional status.*"
- ~~Seizures Antiepileptic Drugs (AEDs)~~
 - ▶ 1st bullet modified: "Seizures are frequent in patients with primary or metastatic brain tumors. Despite this, studies have shown that the use of older, "traditional" *antiepileptic drugs (AEDs)*..."

[BRAIN-E \(3 of 3\)](#)

Psychiatric Disorders

- ▶ 1st bullet modified: "*Depression and/or anxiety is common in brain tumor neuro-oncology patients...See Andersen BL, et al. Screening, assessment, and care of anxiety and depressive symptoms in adults with cancer: an American Society of Clinical Oncology guideline adaptation. J Clin Oncol 2014;32:1605-1619.*"
- ▶ 2nd bullet modified: "AEDs, anxiolytics, some chemotherapy agents, antiemetics, and other agents used directly in cancer therapy may affect mental status, alertness, and mood. Alterations in thought processes should trigger an investigation for any reversible *treatable* causes, including endocrine disorders, infection, side effects of medication, or tumor progression."

Allied Services

- 2nd bullet modified: "Practitioners are encouraged to serve as a resource *and to refer patients to social services, support groups, and cancer patient advocacy organizations.* ~~for referrals to social service, tumor support, and educational agencies for their patients."~~
- 4th bullet modified to include the following: "*Palliative care should be integrated into patient management of neuro-oncology patients early in the course of their treatment. See NCCN Guidelines for Palliative Care and Ferrell BR, et al. Integration of Palliative Care Into Standard Oncology Care: American Society of Clinical Oncology Clinical Practice Guideline Update. J Clin Oncol 2017;35:96-112.*"

[BRAIN-F](#)

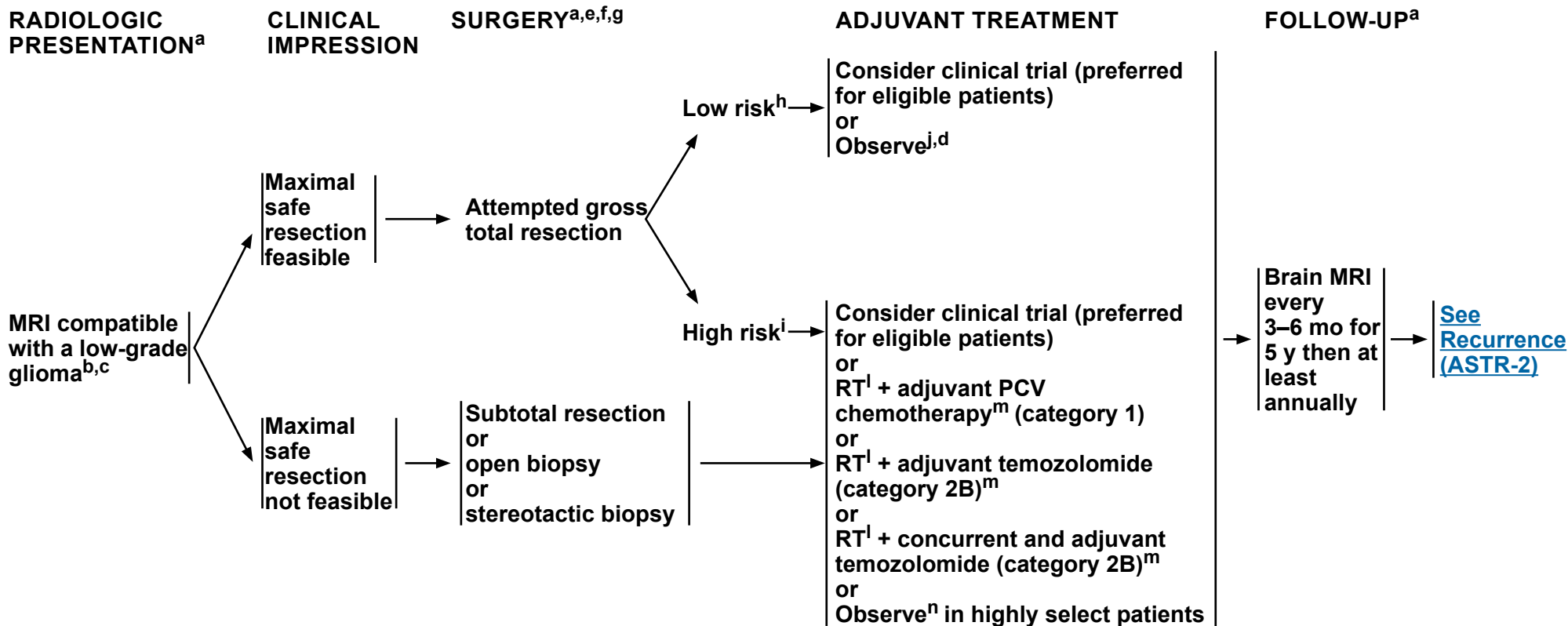
Principles of Brain Tumor Pathology

- This section of the guidelines has been extensively revised.



NCCN Guidelines Version 2.2018

Adult Low-Grade (WHO Grade II) Infiltrative Supratentorial Astrocytoma/Oligodendoglioma



^aSee Principles of Brain and Spine Tumor Imaging (BRAIN-A).

^bConsider a multidisciplinary review in treatment planning, especially once pathology is available (See Principles of Brain and Spine Tumor Management (BRAIN-E)).

^cIf radiographically the tumor appears to be a high-grade glioma, see GLIO-1.

^dIn the event that other risk factors are considered and treatment is warranted, treat as high risk. There may also be rare circumstances in which treating a patient with fractionated external beam RT alone (category 2B) or chemotherapy alone (category 2B) may be considered. See Principles of Brain and Spinal Cord Tumor Radiation (BRAIN-C) or Principles of Brain and Spinal Cord Tumor Systemic Therapy (BRAIN-D).

^eSee Principles of Brain Tumor Surgery (BRAIN-B).

^fRecommended molecular diagnostics include 1p19q chromosomal status and IDH1/2 mutation status. See Principles of Brain Tumor Pathology (BRAIN-F).

^gPostoperative brain MRI within 24–72 hours after surgery.

^hLow-risk features: ≤40 y and gross total resection (GTR).

ⁱHigh-risk features: >40 y or subtotal resection (STR). Other high-risk factors that are sometimes taken into consideration are tumor size, neurological deficits and presence of sequencing verified IDH wild type.

^jRegular follow-up is essential for patients receiving observation alone after resection.

^lFor low-grade gliomas, See Principles of Brain and Spinal Cord Tumor Radiation Therapy (BRAIN-C).

^mSee Principles of Brain and Spinal Cord Tumor Systemic Therapy (BRAIN-D).

ⁿThe results of RTOG 9802 showed that there was a significant improvement in median overall survival in high-risk low-grade glioma patients treated with RT followed by PCV x 6 cycles compared with RT alone after a tissue diagnosis was made. However, this important study did not address whether all of these patients should be treated right away. Observation after diagnosis may be a reasonable option for a high-risk low-grade glioma patient who is neurologically asymptomatic or stable. Close monitoring with brain MRIs is important.

Note: All recommendations are category 2A unless otherwise indicated.

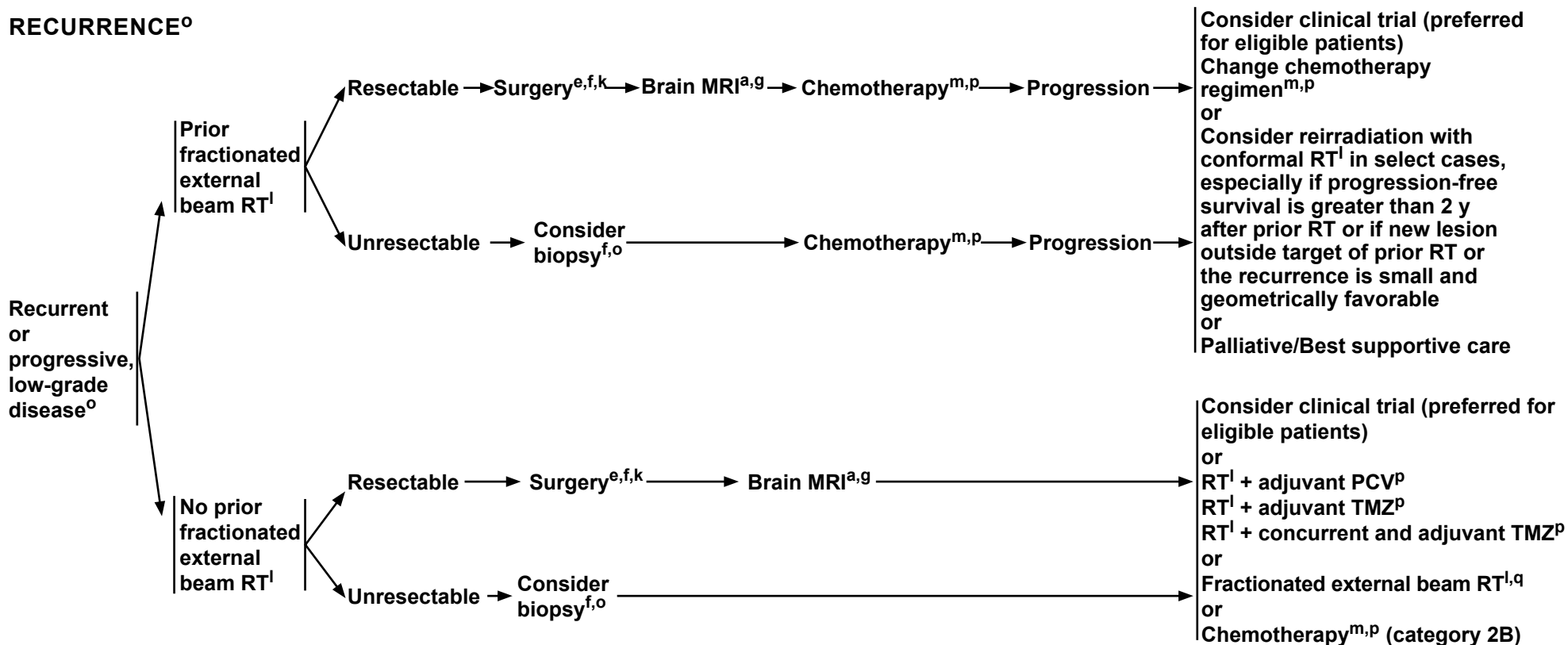
Clinical Trials: NCCN believes that the best management of any patient with cancer is in a clinical trial. Participation in clinical trials is especially encouraged.



NCCN Guidelines Version 2.2018

Adult Low-Grade (WHO Grade II) Infiltrative Supratentorial Astrocytoma/Oligodendoglioma

RECURRENCE^o



^aSee [Principles of Brain and Spine Tumor Imaging \(BRAIN-A\)](#).

^eSee [Principles of Brain Tumor Surgery \(BRAIN-B\)](#).

^fRecommended molecular diagnostics include 1p19q chromosomal status and IDH1/2 mutation status, [See Principles of Brain Tumor Pathology \(BRAIN-F\)](#).

^gPostoperative brain MRI within 24–72 hours after surgery.

^kIf GTR is achieved, consider further observation.

^lFor low-grade gliomas, [See Principles of Brain and Spinal Cord Tumor Radiation Therapy \(BRAIN-C\)](#).

^mSee [Principles of Brain and Spinal Cord Tumor Systemic Therapy \(BRAIN-D\)](#).

^oRecurrence on neuroimaging can be confounded by treatment effects. To confirm tumor recurrence and assess for possible transformation of tumor to higher

grade, strongly consider tumor tissue sampling (biopsy at minimum) if there is a high index of suspicion of recurrence. Sixty percent or more of astrocytomas and 40%–50% of oligodendrogliomas will eventually undergo transformation to a higher grade. For treatment of patients with transformation to high-grade disease, [see GLIO-1](#).

^pBrain MRI every 2–3 months while on treatment, then every 6 months indefinitely, to assess disease recurrence/progression during treatment with chemotherapy. [\(See BRAIN-A\)](#).

^qRT alone is not encouraged, but may be appropriate for select cases (eg, poor performance status).

Note: All recommendations are category 2A unless otherwise indicated.

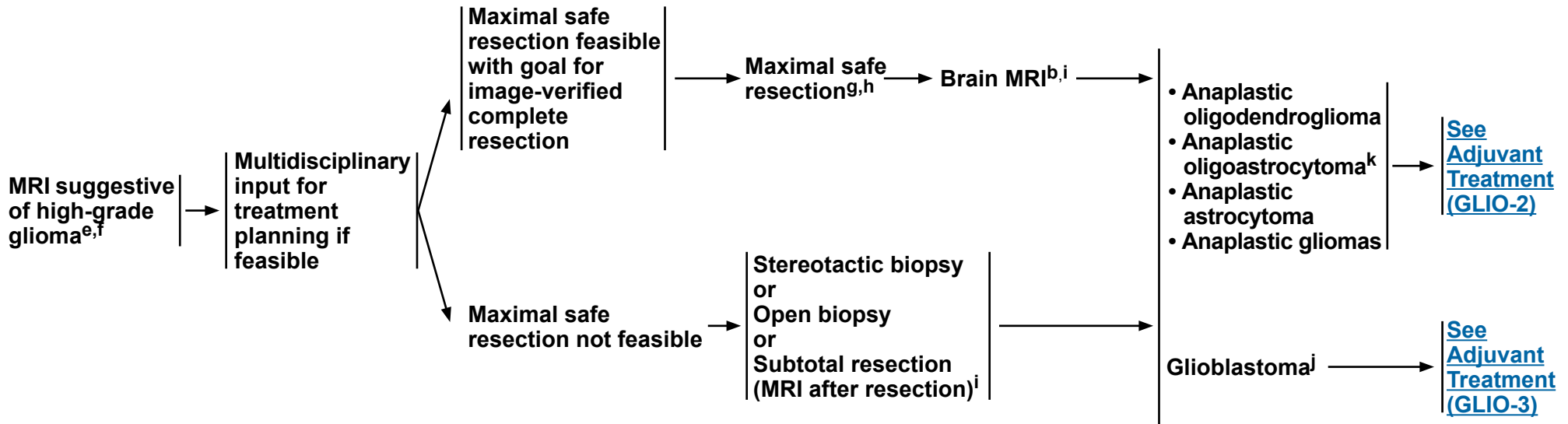
Clinical Trials: NCCN believes that the best management of any patient with cancer is in a clinical trial. Participation in clinical trials is especially encouraged.

**RADIOLOGIC
PRESENTATION^b**

**CLINICAL
IMPRESSION**

SURGERY^c

PATHOLOGY^d



^aThis pathway includes the classification of mixed anaplastic oligoastrocytoma (AOA), anaplastic astrocytoma (AA), anaplastic oligodendroglioma (AO), and other rare anaplastic gliomas.

^bSee [Principles of Brain and Spine Tumor Imaging \(BRAIN-A\)](#).

^cSee [Principles of Brain Tumor Surgery \(BRAIN-B\)](#).

^dSee [Principles of Brain Tumor Pathology \(BRAIN-F\)](#).

^eBiopsy first if MRI compatible with CNS lymphoma.

^fConsider a multidisciplinary review in treatment planning, especially once pathology is available ([See Principles of Brain and Spine Tumor Management \(BRAIN-E\)](#)).

^gIf frozen section diagnosis supports high-grade glioma.

^hConsider carmustine (BCNU) wafer implant during maximal safe resection (category 2B). Treatment with carmustine wafer may impact enrollment in adjuvant clinical trials.

ⁱPostoperative brain MRI within 24–72 hours after surgery.

^jThis pathway also includes gliosarcoma.

^kThe 2016 WHO Classification of Tumors of the CNS has deleted oligoastrocytoma as a category, although “anaplastic oligoastrocytoma, NOS” may continue to be used for 1) patients with mixed histology and no available molecular data (ie, no tissue available for analysis) for determining whether to classify as oligodendroglioma versus astrocytoma; or 2) rare instances in which the tumor has regions with histologic features of oligoastrocytoma with 1p19q-codeletion, and distinct regions with histologic features of astrocytoma without 1p19q-codeletion.

Note: All recommendations are category 2A unless otherwise indicated.

Clinical Trials: NCCN believes that the best management of any patient with cancer is in a clinical trial. Participation in clinical trials is especially encouraged.

ANAPLASTIC GLIOMAS (SEE [GLIO-3/GLIO-4](#) FOR GBM)

PATHOLOGY^d

Anaplastic oligodendroglioma (1p19q codeleted)



ADJUVANT TREATMENT

Consider clinical trial (preferred for eligible patients)
or
Fractionated external beam RT^l and neoadjuvant or adjuvant^m PCV (category 1)ⁿ
or
Fractionated external beam RT^l with concurrent and adjuvant temozolomideⁿ

Anaplastic astrocytoma, Anaplastic oligoastrocytoma, NOS^k



Consider clinical trial (preferred for eligible patients)
or
Fractionated external beam RT followed by adjuvant temozolomideⁿ
or
Fractionated external beam RT^l with concurrent and adjuvant temozolomideⁿ
or
Fractionated external beam RT^l + neoadjuvant or adjuvant^m PCV

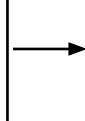
Anaplastic gliomas^a Poor performance status (KPS <60)



Fractionated external beam RT^l (hypofractionated [preferred] or standard)
or
Temozolomide (category 2B)^{n,o}
or
Palliative/Best supportive care

FOLLOW-UP^b

Brain MRI 2–6 wks after RT,^p then every 2–4 mo for 3 y, then every 6 months indefinitely



[See Recurrence \(GLIO-5\)](#)

^aThis pathway includes the classification of mixed AOA, AA, AO, and other rare anaplastic gliomas.

^bSee [Principles of Brain and Spine Tumor Imaging \(BRAIN-A\)](#).

^dSee [Principles of Brain Tumor Pathology \(BRAIN-F\)](#).

^kThe 2016 WHO Classification of Tumors of the CNS has deleted oligoastrocytoma as a category, although “anaplastic oligoastrocytoma, NOS” may continue to be used for 1) patients with mixed histology and no available molecular data (ie, no tissue available for analysis) for determining whether to classify as oligodendroglioma versus astrocytoma; or 2) rare instances in which the tumor has regions with histologic features of oligoastrocytoma with 1p19q-codeletion, and distinct regions with

histologic features of astrocytoma without 1p19q-codeletion.

^lSee [Principles of Brain and Spinal Cord Tumor Radiation Therapy \(BRAIN-C\)](#).

^mThe panel recommends that PCV be administered after RT (as per EORTC 26951) since the intensive PCV regimen given prior to RT (RTOG 9402) was not tolerated as well.

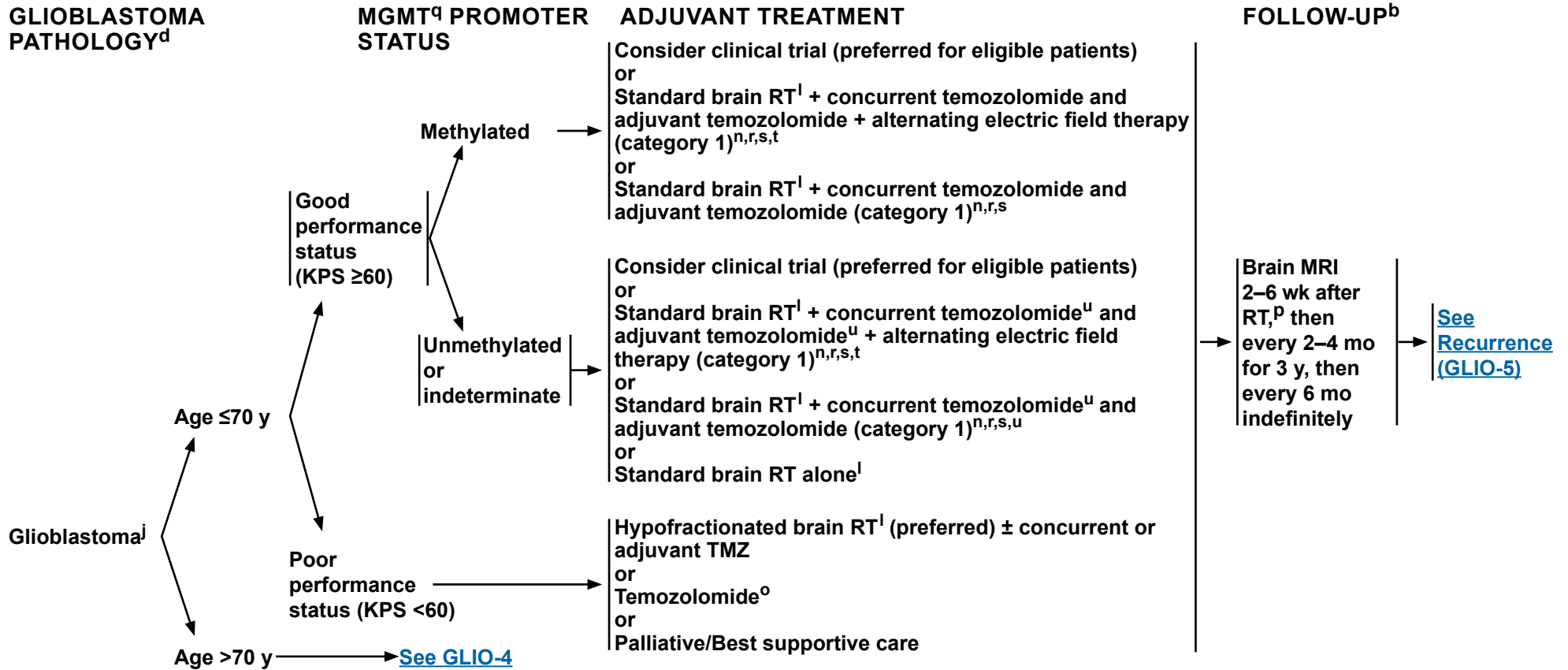
ⁿSee [Principles of Brain and Spinal Cord Tumor Systemic Therapy \(BRAIN-D\)](#).

^oConsider temozolomide if tumor is MGMT promoter methylated.

^pWithin the first 3 months after completion of RT and concomitant temozolomide, diagnosis of recurrence can be indistinguishable from pseudoprogression on neuroimaging.

Note: All recommendations are category 2A unless otherwise indicated.

Clinical Trials: NCCN believes that the best management of any patient with cancer is in a clinical trial. Participation in clinical trials is especially encouraged.



^aThis pathway includes the classification of mixed AOA, AA, AO, and other rare anaplastic gliomas.

^b[See Principles of Brain and Spine Tumor Imaging \(BRAIN-A\).](#)

^d[See Principles of Brain Tumor Pathology \(BRAIN-F\).](#)

^jThis pathway also includes gliosarcoma.

^l[See Principles of Brain and Spinal Cord Tumor Radiation Therapy \(BRAIN-C\).](#)

ⁿ[See Principles of Brain and Spinal Cord Tumor Systemic Therapy \(BRAIN-D\).](#)

^oConsider temozolomide if tumor is MGMT promoter methylated.

^pWithin the first 3 months after completion of RT and concomitant temozolomide, diagnosis of recurrence can be indistinguishable from pseudoprogression on neuroimaging.

^qMGMT= O6-methylguanine-DNA methyltransferase.

^rCombination of agents may lead to increased toxicity or radiographic changes.

^sBenefit of treatment with temozolomide for glioblastomas beyond 6 months is unknown

^tAlternating electric field therapy is only an option for patients with supratentorial disease.

^uClinical benefit from temozolomide is likely to be lower in patients whose tumors lack MGMT promoter methylation.

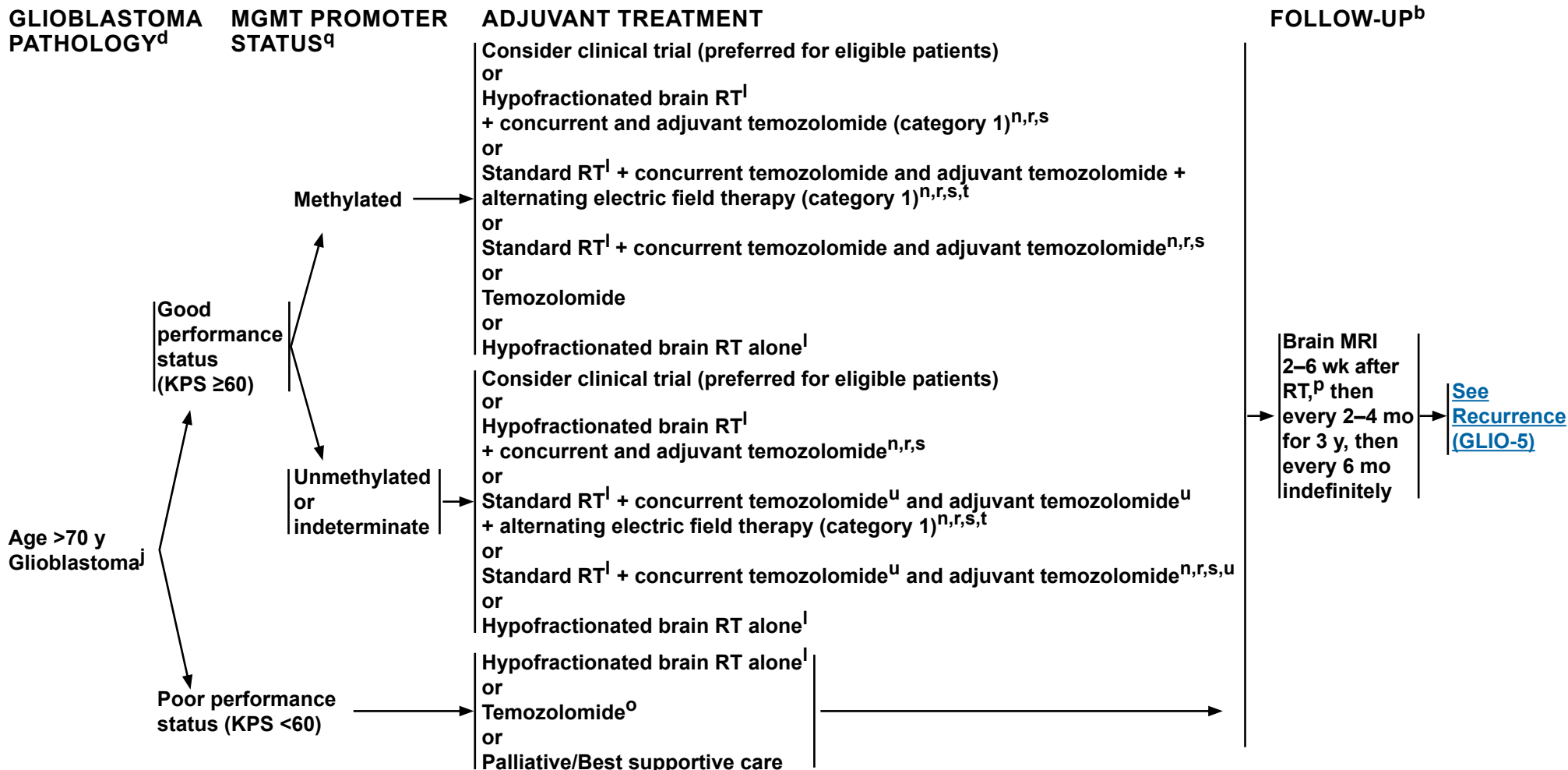
Note: All recommendations are category 2A unless otherwise indicated.

Clinical Trials: NCCN believes that the best management of any patient with cancer is in a clinical trial. Participation in clinical trials is especially encouraged.



NCCN Guidelines Version 2.2018

Anaplastic Gliomas^a/Glioblastoma



^aThis pathway includes the classification of mixed AOA, AA, AO, and other rare anaplastic gliomas.

^bSee [Principles of Brain and Spine Tumor Imaging \(BRAIN-A\)](#).

^dSee [Principles of Brain Tumor Pathology \(BRAIN-F\)](#).

^jThis pathway also includes gliosarcoma.

^lSee [Principles of Brain and Spinal Cord Tumor Radiation Therapy \(BRAIN-C\)](#).

ⁿSee [Principles of Brain and Spinal Cord Tumor Systemic Therapy \(BRAIN-D\)](#).

^oConsider temozolomide if tumor is MGMT promoter methylated.

^pWithin the first 3 months after completion of RT and concomitant temozolomide, diagnosis of recurrence can be indistinguishable from pseudoprogression on neuroimaging.

^qMGMT= O6-methylguanine-DNA methyltransferase.

^rCombination of agents may lead to increased toxicity or radiographic changes.

^sBenefit of treatment with temozolomide for glioblastomas beyond 6 months is unknown.

^tAlternating electric field therapy is only an option for patients with supratentorial disease.

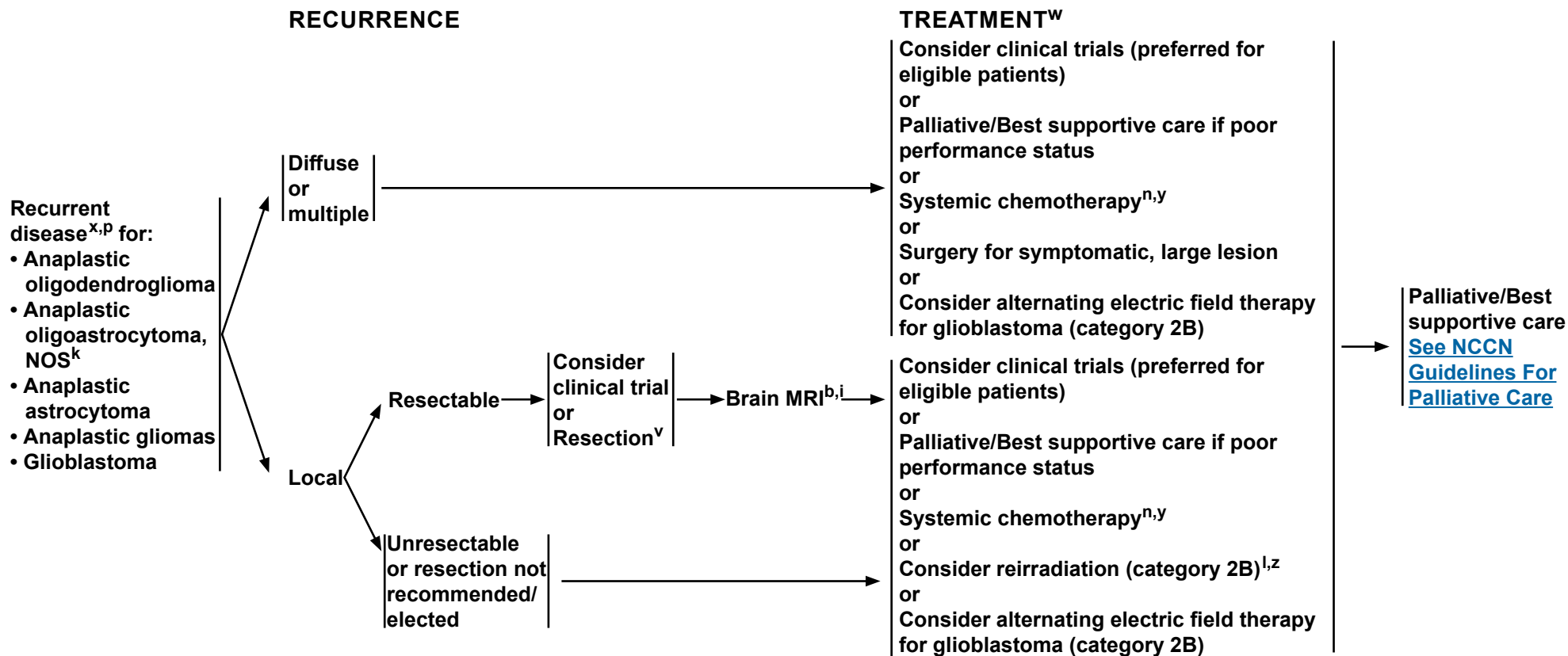
^uClinical benefit from temozolomide is likely to be lower in patients whose tumors lack MGMT promoter methylation.

Note: All recommendations are category 2A unless otherwise indicated.

Clinical Trials: NCCN believes that the best management of any patient with cancer is in a clinical trial. Participation in clinical trials is especially encouraged.



NCCN Guidelines Version 2.2018 Anaplastic Gliomas^a/Glioblastoma



^aThis pathway includes the classification of mixed AOA, AA, AO, and other rare anaplastic gliomas.

^bSee [Principles of Brain and Spine Tumor Imaging \(BRAIN-A\)](#).

ⁱPostoperative brain MRI within 24–72 hours after surgery.

^kThe 2016 WHO Classification of Tumors of the CNS has deleted oligoastrocytoma as a category, although “anaplastic oligoastrocytoma, NOS” may continue to be used for 1) patients with mixed histology and no available molecular data (ie, no tissue available for analysis) for determining whether to classify as oligodendroglioma versus astrocytoma; or 2) rare instances in which the tumor has regions with histologic features of oligoastrocytoma with 1p19q-codeletion, and distinct regions with histologic features of astrocytoma without 1p19q-codeletion.

^lSee [Principles of Brain and Spinal Cord Tumor Radiation Therapy \(BRAIN-C\)](#).

ⁿSee [Principles of Brain and Spinal Cord Tumor Systemic Therapy \(BRAIN-D\)](#).

^PWithin the first 3 months after completion of RT and concomitant temozolomide, diagnosis of recurrence can be indistinguishable from pseudoprogression on neuroimaging.

^YConsider carmustine (BCNU) wafer implant during resection. Treatment with carmustine wafer may impact enrollment in clinical trials.

^WThe efficacy of standard-of-care treatment for recurrent glioblastoma is suboptimal, so for eligible patients consideration of clinical trials is highly encouraged. Prior treatment may impact enrollment in clinical trials.

^XConsider biopsy, MR spectroscopy, MR perfusion, brain PET/CT, or brain PET/MRI, or re-image to follow changes that may be due to progression versus radionecrosis.

^YAnaplastic oligodendrogliomas have been reported to be especially sensitive to chemotherapy. Chemotherapy using temozolomide or nitrosourea-based regimens may be appropriate.

^ZEspecially if long interval since prior RT and/or if there was a good response to prior RT.

Note: All recommendations are category 2A unless otherwise indicated.

Clinical Trials: NCCN believes that the best management of any patient with cancer is in a clinical trial. Participation in clinical trials is especially encouraged.



NCCN Guidelines Version 2.2018

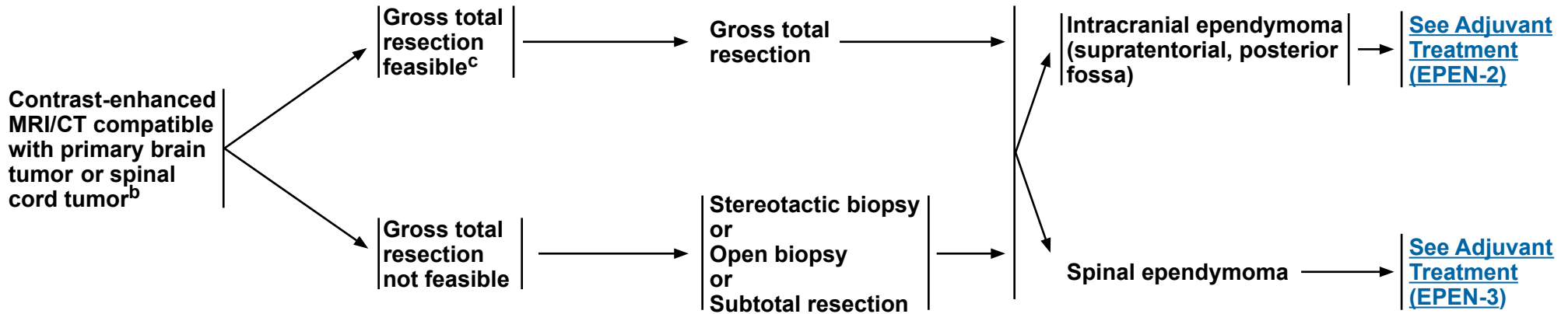
Adult Intracranial and Spinal Ependymoma (Excluding Subependymoma)

RADIOLOGIC PRESENTATION^a

CLINICAL IMPRESSION

SURGERY^d

PATHOLOGY



^aSee [Principles of Brain and Spine Tumor Imaging \(BRAIN-A\)](#).

^bConsider a multidisciplinary review in treatment planning, especially once pathology is available. See [Principles of Brain and Spine Tumor Management \(BRAIN-E\)](#).

^cIf image-confirmed GTR not achieved, consider multidisciplinary review and resection.

^dSee [Principles of Brain Tumor Surgery \(BRAIN-B\)](#).

Note: All recommendations are category 2A unless otherwise indicated.
Clinical Trials: NCCN believes that the best management of any patient with cancer is in a clinical trial. Participation in clinical trials is especially encouraged.



NCCN Guidelines Version 2.2018

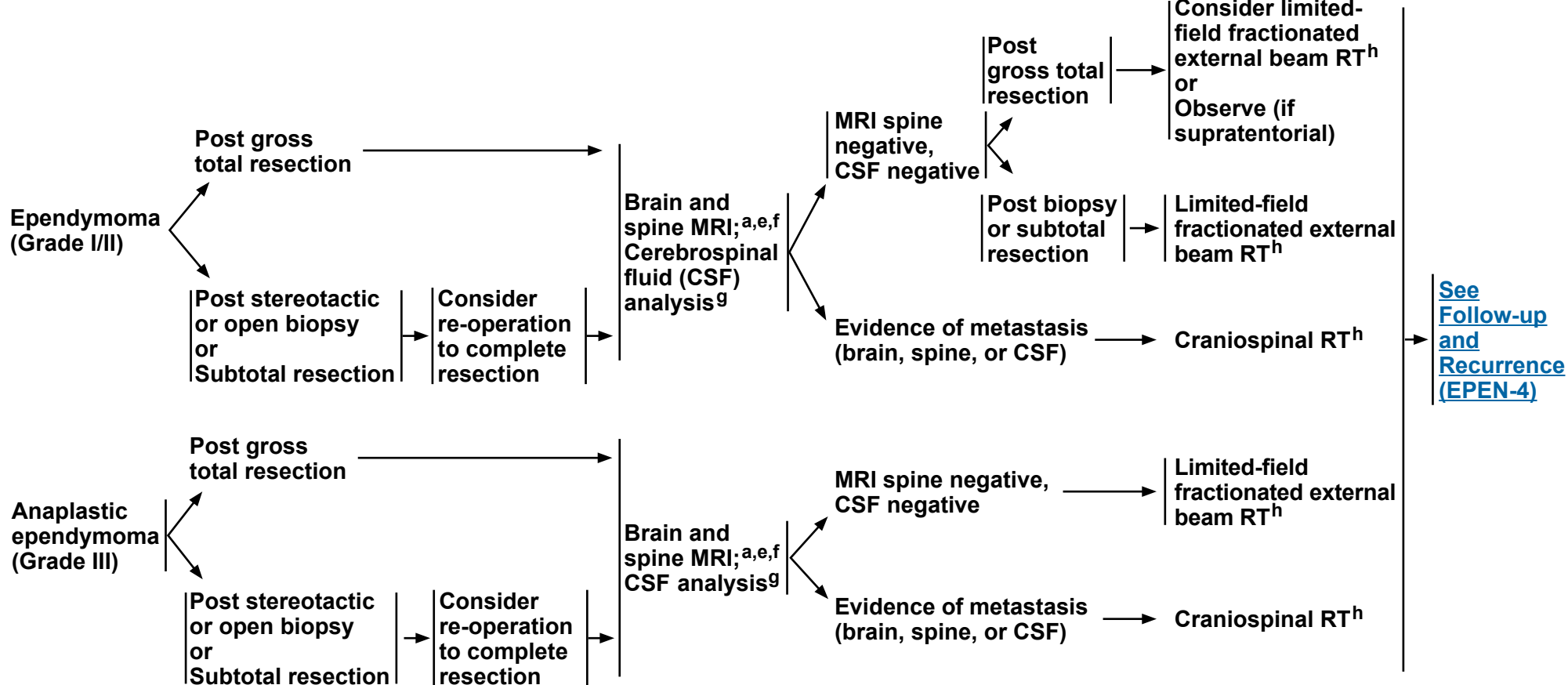
Adult Intracranial and Spinal Ependymoma (Excluding Subependymoma)

INTRACRANIAL EPENDYMOMA

PATHOLOGY

POSTOPERATIVE STAGING

ADJUVANT TREATMENT^h



^aSee Principles of Brain and Spine Tumor Imaging (BRAIN-A).

^ePostoperative brain MRI within 24–72 hours after surgery.

^fIf not done preoperatively, spine MRI should be delayed by at least 2–3 weeks post surgery to avoid post-surgical artifacts.

^gLumbar puncture should be done after MRI of spine is performed to avoid a false-positive imaging result. Lumbar puncture for CSF should be delayed at least 2 weeks after surgery to avoid possible false-positive cytology. Lumbar puncture may be contraindicated (eg, posterior fossa mass).

^hSee Principles of Brain and Spinal Cord Tumor Radiation Therapy (BRAIN-C).

Note: All recommendations are category 2A unless otherwise indicated.

Clinical Trials: NCCN believes that the best management of any patient with cancer is in a clinical trial. Participation in clinical trials is especially encouraged.

NCCN Guidelines Version 2.2018

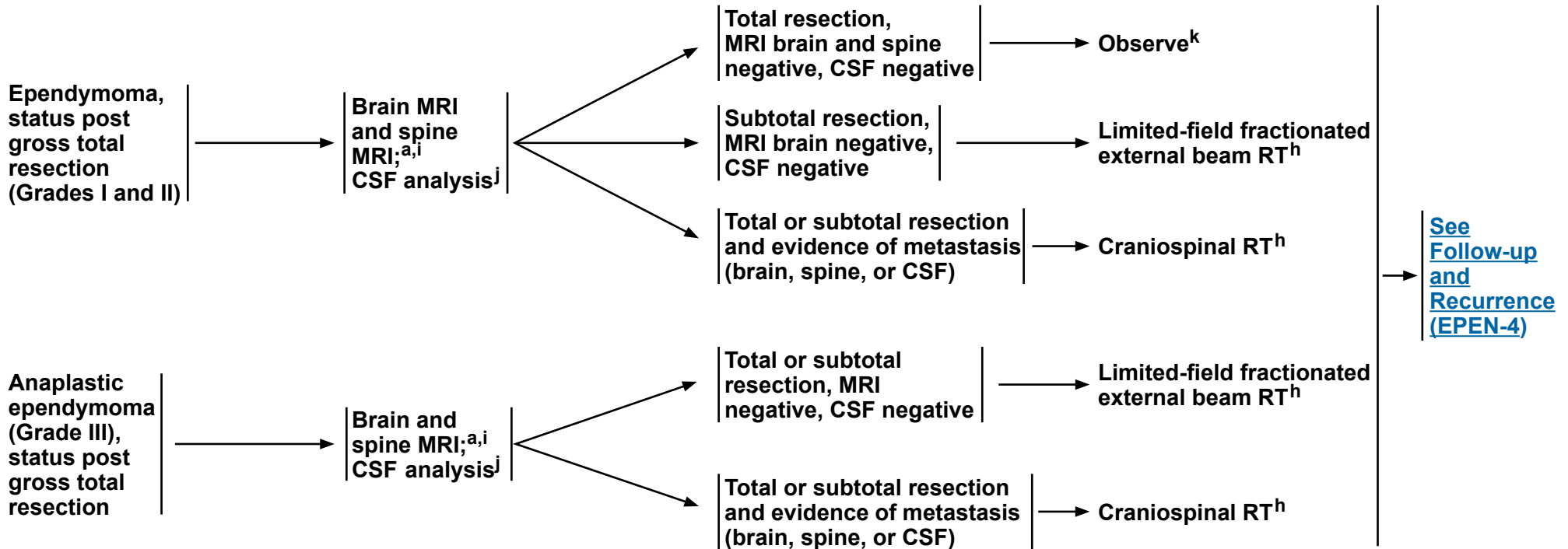
Adult Intracranial and Spinal Ependymoma (Excluding Subependymoma)

SPINAL EPENDYMOMA

PATHOLOGY

POSTOPERATIVE STAGING

ADJUVANT TREATMENT^h



^aSee Principles of Brain and Spine Tumor Imaging (BRAIN-A).

^hSee Principles of Brain and Spinal Cord Tumor Radiation Therapy (BRAIN-C).

ⁱIf not done preoperatively, spine MRI should be performed 24–72 h post surgery.

^jLumbar puncture for CSF should be delayed at least 2 weeks after surgery to avoid possible false-positive cytology. Lumbar puncture may be contraindicated (eg, posterior fossa mass).

^kConsider limited-field fractionated external beam if myxopapillary ependymoma.

Note: All recommendations are category 2A unless otherwise indicated.

Clinical Trials: NCCN believes that the best management of any patient with cancer is in a clinical trial. Participation in clinical trials is especially encouraged.



NCCN Guidelines Version 2.2018

Adult Intracranial and Spinal Ependymoma (Excluding Subependymoma)

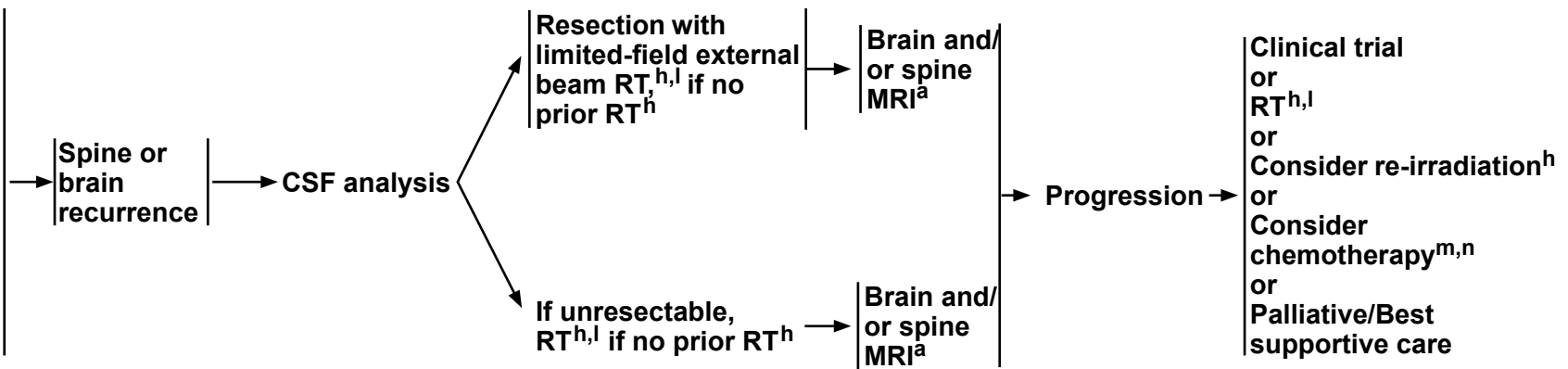
FOLLOW-UP^a

RECURRENCE

CLINICAL STAGING

TREATMENT FOR PROGRESSION

- Imaging in the event of emergent signs or symptoms (brain and/or spine MRI)
- Imaging of tumor site (brain or spine MRI) every 3–4 mo for 1 y, then every 4–6 mo for year 2, then every 6–12 mo for 5–10 y, then as clinically indicated



^aSee Principles of Brain and Spine Tumor Imaging (BRAIN-A).

^hSee Principles of Brain and Spinal Cord Tumor Radiation Therapy (BRAIN-C).

^lConsider stereotactic radiosurgery (SRS) if geometrically favorable.

^mChemotherapy should be reserved for patients who are refractory to surgery or radiation.

ⁿSee Principles of Brain and Spinal Cord Tumor Systemic Therapy (BRAIN-D).

Note: All recommendations are category 2A unless otherwise indicated.

Clinical Trials: NCCN believes that the best management of any patient with cancer is in a clinical trial. Participation in clinical trials is especially encouraged.



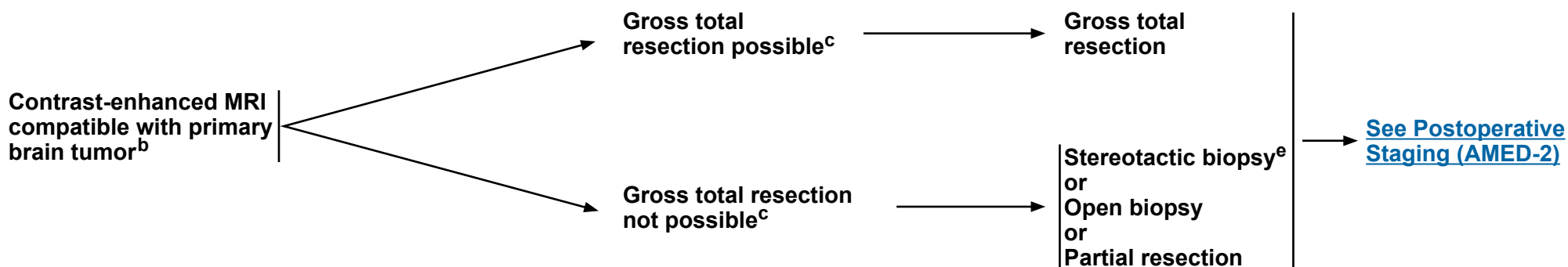
NCCN Guidelines Version 2.2018

Adult Medulloblastoma

RADIOLOGIC PRESENTATION^a

CLINICAL IMPRESSION

SURGERY^d



^aSee [Principles of Brain and Spine Tumor Imaging \(BRAIN-A\)](#).

^bConsider a multidisciplinary review in treatment planning, before surgery and once pathology is available (See [Principles of Brain and Spine Tumor Management \(BRAIN-E\)](#)).

^cPlacement of ventriculoperitoneal (VP) shunt for management of hydrocephalus is acceptable if needed.

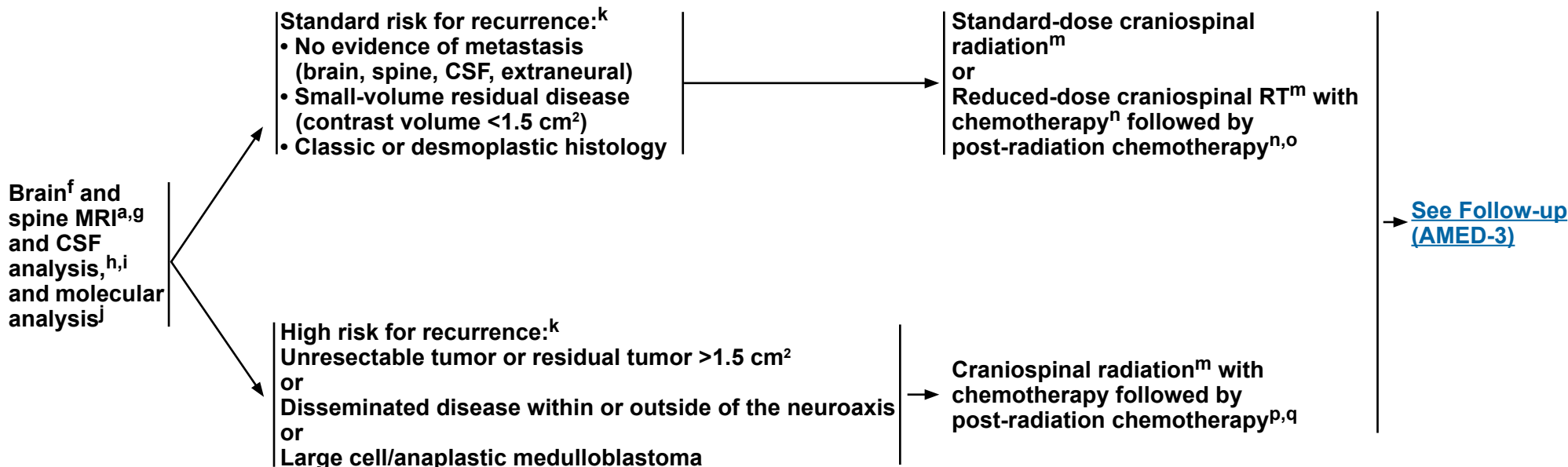
^dSee [Principles of Brain Tumor Surgery \(BRAIN-B\)](#).

^eStrongly recommend referring patient to a brain tumor center to be evaluated for possible further, more complete surgical resection.

Note: All recommendations are category 2A unless otherwise indicated.
Clinical Trials: NCCN believes that the best management of any patient with cancer is in a clinical trial. Participation in clinical trials is especially encouraged.



POSTOPERATIVE STAGING



^aSee [Principles of Brain and Spine Tumor Imaging \(BRAIN-A\)](#).

^fPostoperative brain MRI within 24–72 hours after surgery.

^gSpine MRI should be delayed by at least 2–3 weeks post surgery to avoid post-surgical artifacts.

^hLumbar puncture should be done after spine MRI. Lumbar puncture for CSF should be delayed at least 2 weeks after surgery to avoid possible false-positive cytology.

ⁱBone scan; CT with contrast of chest, abdomen, and pelvis or whole body PET/CT; and bone marrow biopsy only if clinically indicated.

^jMolecular profiling to identify clinically relevant subtypes is recommended to encourage opportunities for clinical trial involvement. See [Principles of Pathology \(BRAIN-F\)](#).

^kSee the modified Chang system for staging medulloblastoma. (Chang CH, Housepain EM, Herbert, C. Radiology 1969;93:1351 and Cohen ME, Duffner PK (Eds). Brain Tumors in children, 2nd ed, McGraw-Hill, New York, 1994, p. 187.)

^lIf only biopsy is possible, consider pre-irradiation chemotherapy followed by an attempt at resection at a center that specializes in the treatment of brain tumors.

^mSee [Principles of Brain and Spinal Cord Tumor Radiation Therapy \(BRAIN-C\)](#).

ⁿOmission of vincristine during radiotherapy phase of therapy or dose modification may be required for adults because they do not tolerate this regimen as well. Data supporting vincristine's use have been found in pediatric trials only. Patients should be closely monitored for neurologic toxicity with periodic exams. (Packer RJ, Gajjar A, Vezina G, et al. Phase III study of craniospinal radiation therapy followed by adjuvant chemotherapy for newly diagnosed average-risk medulloblastoma. J Clin Oncol 2006;24:4202-4208.)

^oSee [Principles of Brain and Spinal Cord Tumor Systemic Therapy \(BRAIN-D\)](#).

^pRecommend a platinum-based chemotherapy regimen such as either of the treatment arms used in the Children's Oncology Group study referenced in footnote "n."

^qConsider collecting stem cells before craniospinal radiation.

Note: All recommendations are category 2A unless otherwise indicated.

Clinical Trials: NCCN believes that the best management of any patient with cancer is in a clinical trial. Participation in clinical trials is especially encouraged.

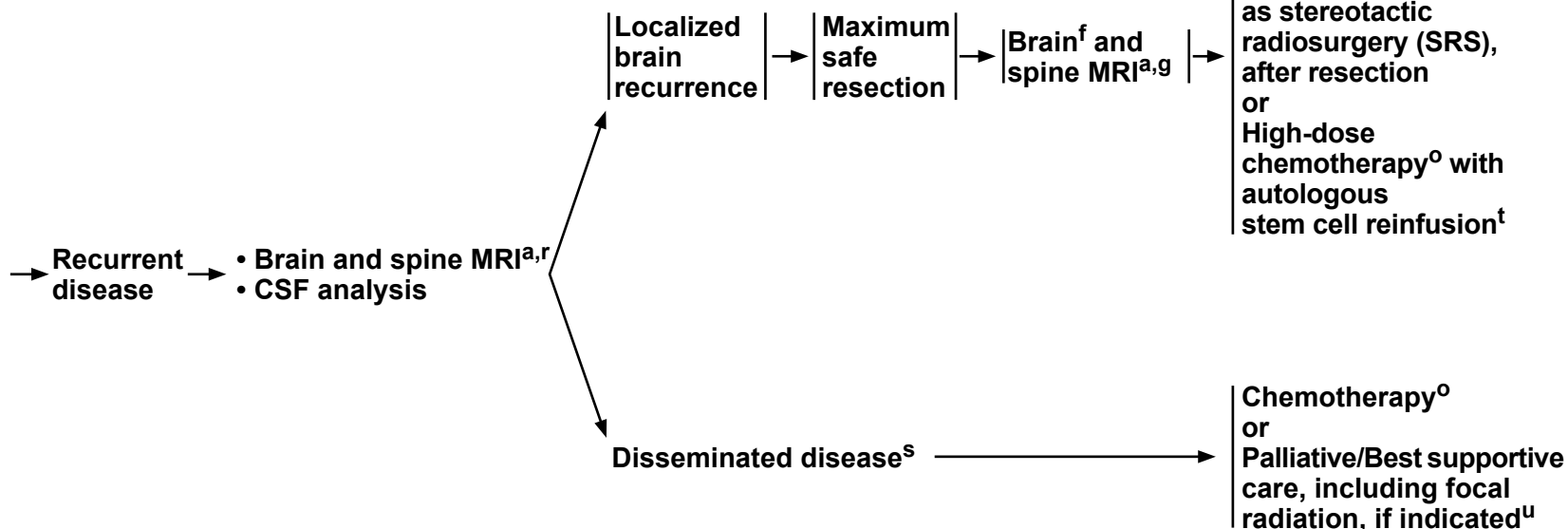
FOLLOW-UP^a

CLINICAL STAGING

SURGERY

TREATMENT FOR RECURRENCE

Brain MRI:
every 3 mo for 2 y;
then every 6–12 mo for
5–10 y;
then as clinically
indicated
For patients with
previous spine disease,
concurrent spine
imaging as clinically
indicated



^aSee [Principles of Brain and Spine Tumor Imaging \(BRAIN-A\)](#).

^rPostoperative brain MRI within 24–72 hours after surgery.

^gSpine MRI should be delayed by at least 2–3 weeks post surgery to avoid post-surgical artifacts.

^oSee [Principles of Brain and Spinal Cord Tumor Systemic Therapy \(BRAIN-D\)](#).

^rAs clinically indicated, consider bone scan; contrast-enhanced CT scans of chest, abdomen, and pelvis; and/or bone marrow biopsy.

^sConsider resection for palliation of symptoms where indicated.

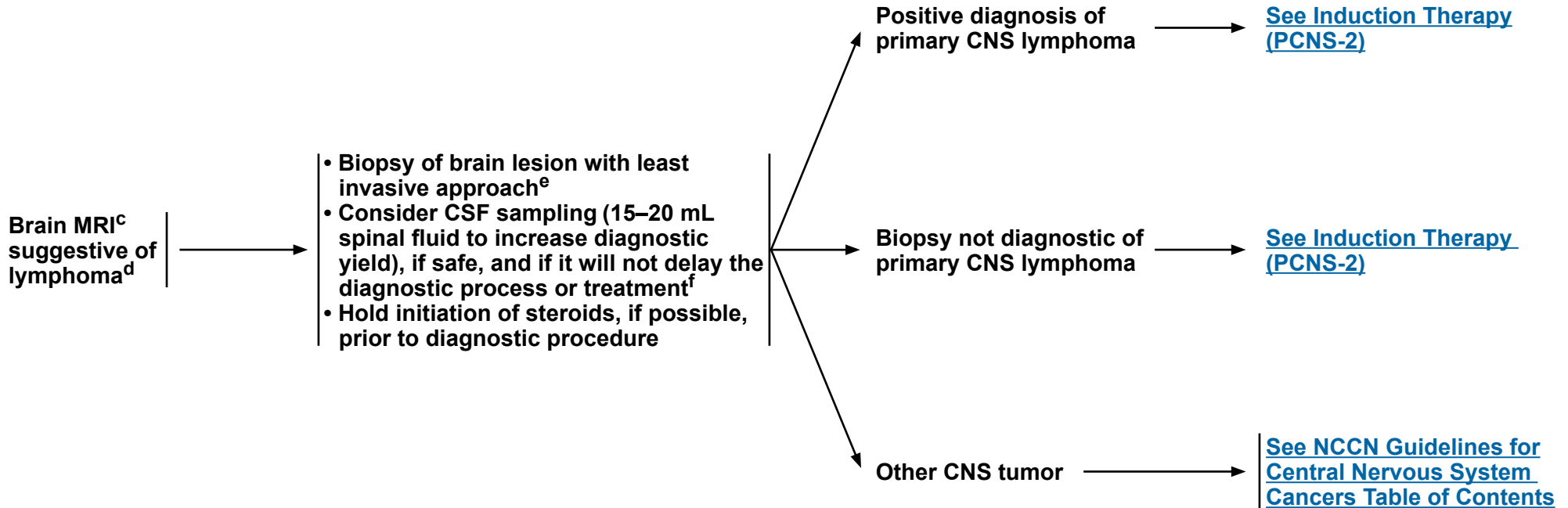
^tOnly if the patient is without evidence of disease after surgery or conventional dose re-induction chemotherapy.

^uSee [Principles of Brain and Spinal Cord Tumor Radiation Therapy \(BRAIN-C\)](#).

Note: All recommendations are category 2A unless otherwise indicated.

Clinical Trials: NCCN believes that the best management of any patient with cancer is in a clinical trial. Participation in clinical trials is especially encouraged.

**DIAGNOSIS BY
TISSUE EVALUATION**



^aIf patient is HIV positive, antiretroviral therapy should be part of his/her treatment. Antiretrovirals (ARVs) can be administered safely with chemotherapy but consultation with an HIV specialist or pharmacist is important to optimize compatibility. [See NCCN Guidelines for Diffuse Large B-Cell Lymphoma, subalgorithm for AIDS-Related B-Cell Lymphomas.](#)

^bFor additional guidance on management of transplant recipients with PCNSL, [see NCCN Guidelines for Diffuse Large B-Cell Lymphoma, sub-algorithm for Post-Transplant Lymphoproliferative Disorders.](#)

^c[See Principles of Brain and Spine Tumor Imaging \(BRAIN-A\).](#)

^dIncludes primary CNS lymphoma of the brain, spine, CSF, and leptomeninges. For lymphoma with primary tumor outside the CNS or involving only the eye, [See NCCN Guidelines for Diffuse Large B-Cell Lymphoma.](#)

^eIf stereotactic biopsy is not available refer to a specialized center.

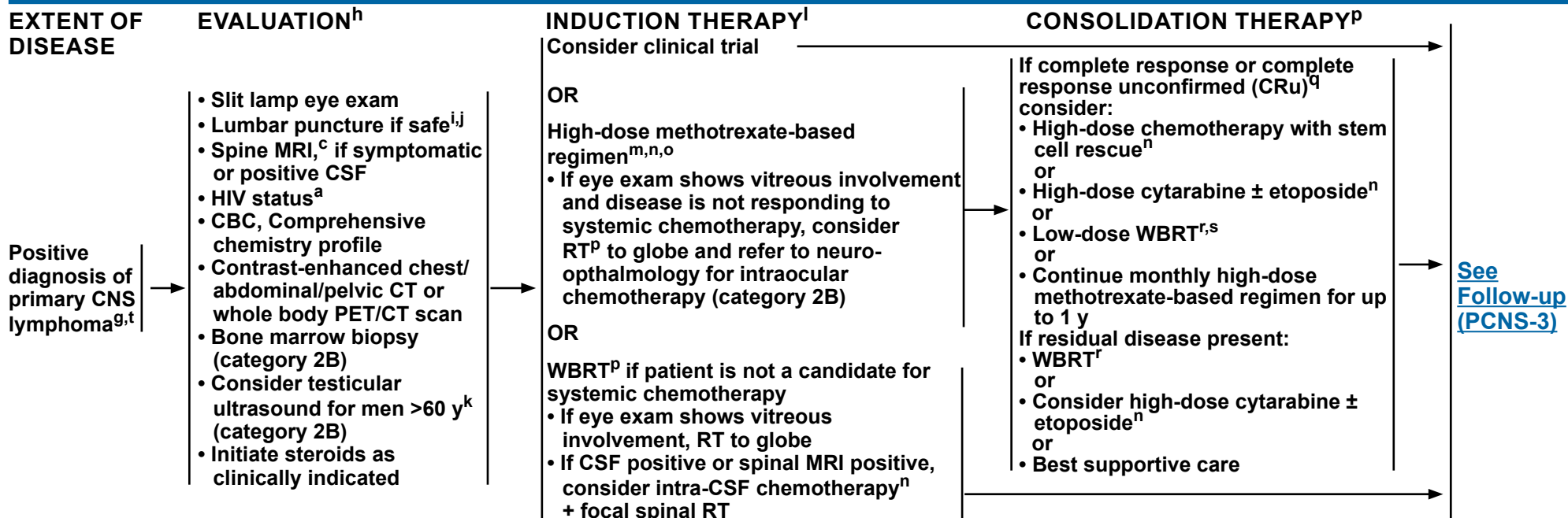
^fBrain biopsy is recommended as the primary procedure to obtain diagnosis. CSF analysis should include flow cytometry and CSF cytology and possibly gene rearrangements.

Note: All recommendations are category 2A unless otherwise indicated.
Clinical Trials: NCCN believes that the best management of any patient with cancer is in a clinical trial. Participation in clinical trials is especially encouraged.

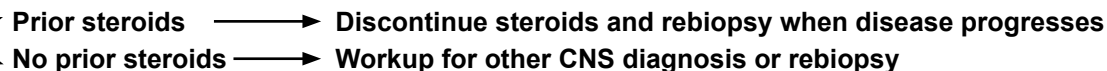

NCCN Guidelines Version 2.2018

Primary CNS Lymphoma^a



Biopsy not diagnostic of primary CNS lymphoma



^aIf patient is HIV positive, antiretroviral therapy should be part of his/her treatment. ARVs can be administered safely with chemotherapy but consultation with an HIV specialist or pharmacist is important to optimize compatibility. [See NCCN Guidelines for Diffuse Large B-Cell Lymphoma, sub-algorithm for AIDS-Related B-Cell Lymphomas.](#)

^c[See Principles of Brain and Spine Tumor Imaging \(BRAIN-A\).](#)

^gMay institute primary therapy and workup simultaneously.

^hFor full details regarding evaluation of extent of disease and response criteria for primary CNS lymphoma, refer to Abrey LE, Batchelor TT, Ferreri AJM, et al. Report of an international workshop to standardize baseline evaluation and response criteria for primary CNS lymphoma. *J Clin Oncol* 2005;23:5034-5043.

ⁱCSF analysis should include flow cytometry, and CSF cytology, and may consider gene rearrangements.

^jCaution is indicated in patients who are anticoagulated, thrombocytopenic, or who have a bulky intra-cranial mass.

^kRecommend regular testicular exams. If PET/CT scan is negative, then there is no need for testicular ultrasound.

^lA low KPS should not be a reason to withhold chemotherapy. KPS may improve dramatically after treatment.

^mDose adjusted for GFR.

ⁿ[See Principles of Brain and Spinal Cord Tumor Systemic Therapy \(BRAIN-D\).](#)

^oIf CSF positive or spinal MRI positive, consider alternative systemic chemotherapy regimens

and/or intra-CSF chemotherapy (category 2B), especially for patients who cannot tolerate systemic methotrexate ≥3 g/m².

^pDue to a lack of strong evidence, it is not clear which consolidation regimen provides the most benefit.

^qFor CRu criteria, see: Abrey LE, et al. Report of an international workshop to standardize baseline evaluation and response criteria for primary CNS lymphoma. *J Clin Oncol* 2005;23:5034-5043.

^r[See Principles of Brain and Spinal Cord Tumor Radiation Therapy \(BRAIN-C\).](#)

^sWBRT may increase neurotoxicity, especially in patients >60 y.

^tIncludes primary CNS lymphoma of the brain, spine, CSF, and leptomeninges.

Note: All recommendations are category 2A unless otherwise indicated.

Clinical Trials: NCCN believes that the best management of any patient with cancer is in a clinical trial. Participation in clinical trials is especially encouraged.

NCCN Guidelines Version 2.2018

Primary CNS Lymphoma^a

FOLLOW-UP

- Brain MRI:^c
 - ▶ every 3 mo until 2 y,
 - ▶ every 6 mo until 5 y,
 - ▶ then annually indefinitely
- For patients with previous spine disease, concurrent spine imaging^c and CSF sampling as clinically indicated
- For patients with prior ocular involvement, concurrent ophthalmologic follow-up as clinically indicated

RELAPSED OR REFRACTORY PRIMARY CNS LYMPHOMA

Any type of treatment history

Prior WBRT

Prior high-dose methotrexate-based regimen without prior RT

Prior high-dose chemotherapy with stem cell rescue

Previous response with long duration (≥12 mo)

No response or short duration (<12 mo)

Previous response with long duration (≥12 mo)

No response or short duration (<12 mo)

TREATMENT

- Consider clinical trial
- Consider chemotherapy (systemic and/or intra-CSF)ⁿ or
- Consider high-dose therapy^v with stem cell rescue^u (category 2B) or
- Consider focal irradiation or
- Palliative/Best supportive care
- Re-treat with high-dose methotrexate ± other chemotherapyⁿ or
- Other systemic chemotherapyⁿ or
- Consider high-dose therapy with stem cell rescue^u (category 2B) or
- Palliative/Best supportive care
- WBRT or involved-field RT^r ± chemotherapyⁿ or
- Consider high-dose therapy with stem cell rescue^u (category 2B) or
- Palliative/Best supportive care
- Consider second high-dose chemotherapy with stem cell rescue^u or
- Other systemic chemotherapyⁿ or
- Best supportive care
- WBRT or involved-field RT^r or
- Palliative/Best supportive care

^aIf patient is HIV positive, antiretroviral therapy should be part of his/her treatment. ARVs can be administered safely with chemotherapy but consultation with an HIV specialist or pharmacist is important to optimize compatibility. [See NCCN Guidelines for B-Cell Lymphomas, sub-algorithm for AIDS-Related B-Cell Lymphomas.](#)

^c[See Principles of Brain and Spine Tumor Imaging \(BRAIN-A\).](#)

ⁿ[See Principles of Brain and Spinal Cord Tumor Systemic Therapy \(BRAIN-D\).](#)

^r[See Principles of Brain and Spinal Cord Tumor Radiation Therapy \(BRAIN-C\).](#)

^uIf the recurrent disease goes into complete remission with reinduction chemotherapy.

^vThe risk of neurotoxicity should be considered before administering high-dose therapy to a patient with prior WBRT.

Note: All recommendations are category 2A unless otherwise indicated.

Clinical Trials: NCCN believes that the best management of any patient with cancer is in a clinical trial. Participation in clinical trials is especially encouraged.



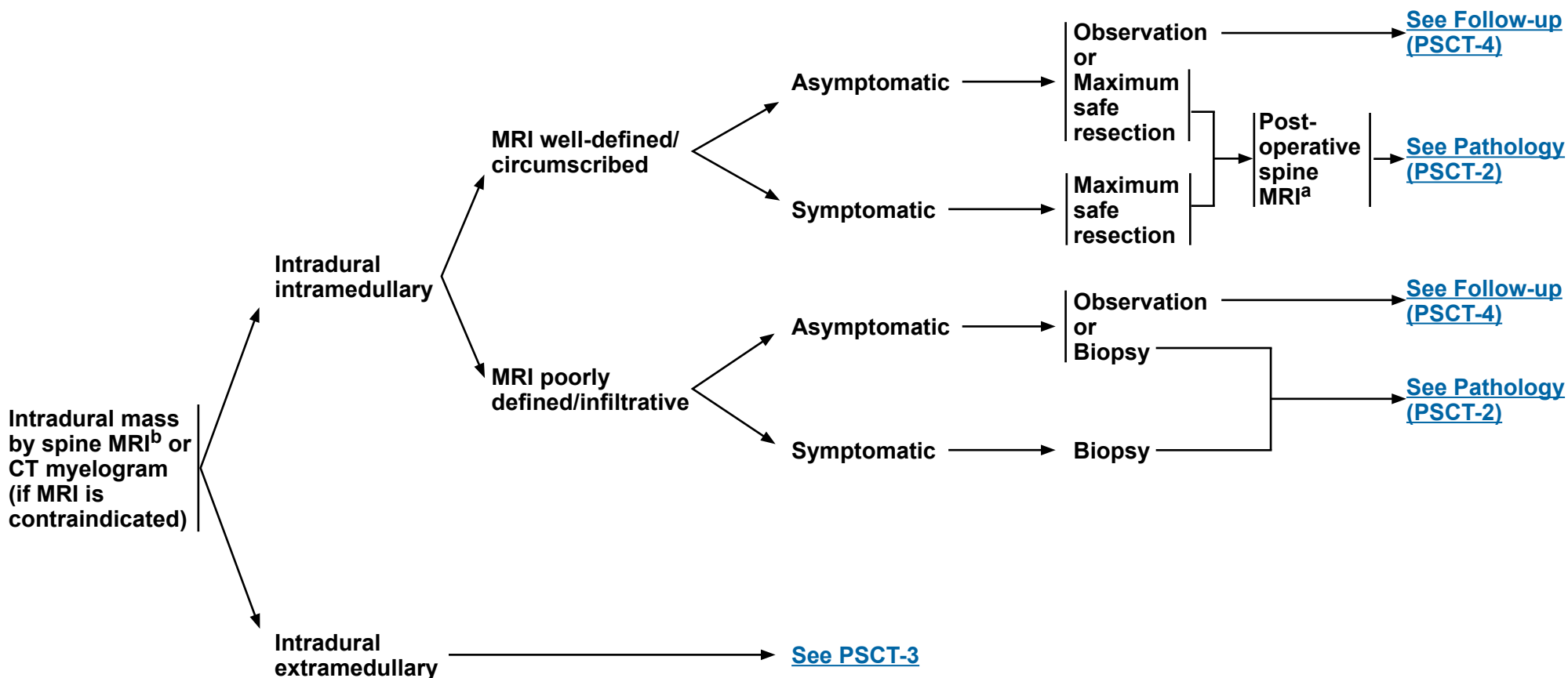
NCCN Guidelines Version 2.2018

Primary Spinal Cord Tumors

RADIOLOGIC PRESENTATION^a

CLINICAL PRESENTATION

SURGERY^c



^aSee Principles of Brain and Spine Tumor Imaging (BRAIN-A).

^bConsider a multidisciplinary review in treatment planning, before surgery and once pathology is available (See Principles of Brain and Spine Tumor Management [BRAIN-E]).

^cSee Principles of Brain Tumor Surgery (BRAIN-B).

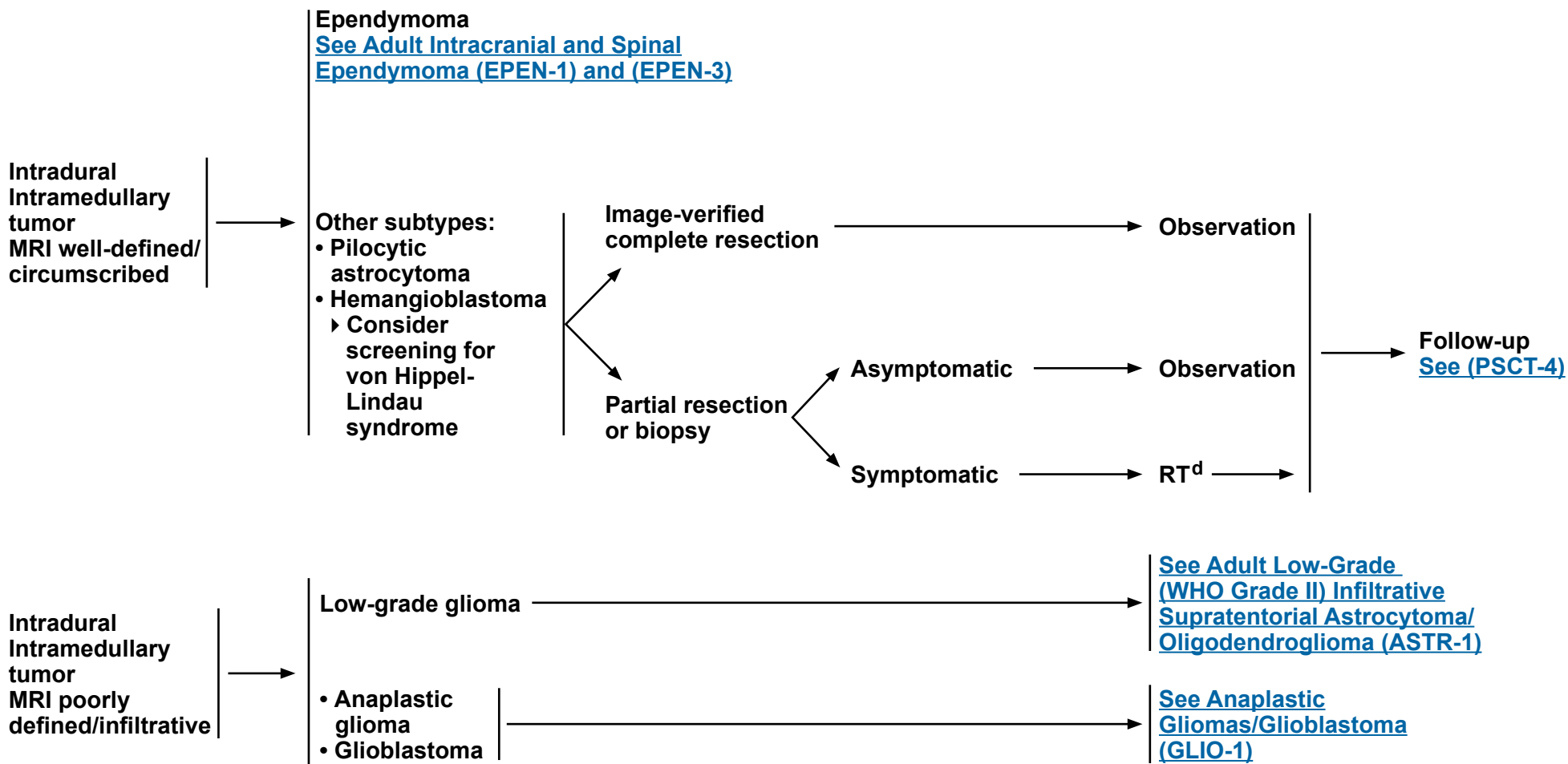
Note: All recommendations are category 2A unless otherwise indicated.
Clinical Trials: NCCN believes that the best management of any patient with cancer is in a clinical trial. Participation in clinical trials is especially encouraged.



NCCN Guidelines Version 2.2018

Primary Spinal Cord Tumors

RADIOLOGIC PRESENTATION	PATHOLOGY	CLINICAL PRESENTATION	ADJUVANT TREATMENT	FOLLOW-UP
-------------------------	-----------	-----------------------	--------------------	-----------



^dSee Principles of Brain and Spinal Cord Tumor Radiation Therapy (BRAIN-C).

Note: All recommendations are category 2A unless otherwise indicated.
Clinical Trials: NCCN believes that the best management of any patient with cancer is in a clinical trial. Participation in clinical trials is especially encouraged.



NCCN Guidelines Version 2.2018

Primary Spinal Cord Tumors

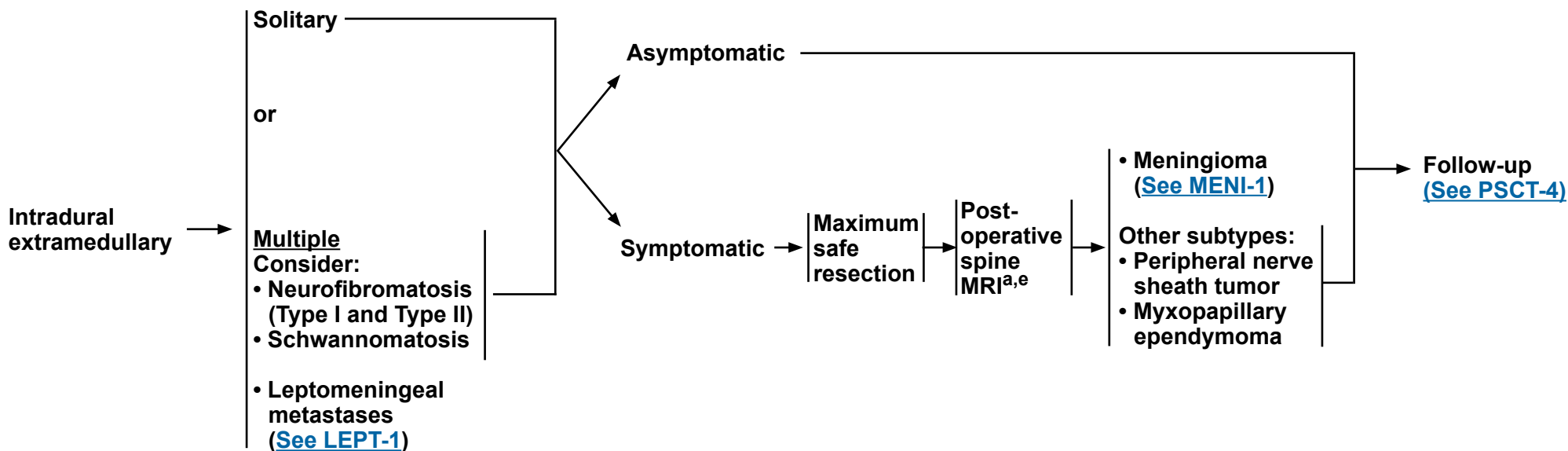
RADIOLOGIC PRESENTATION

CLINICAL PRESENTATION

SURGERY^c

PATHOLOGY

FOLLOW-UP



^aSee Principles of Brain and Spine Tumor Imaging (BRAIN-A).

^cSee Principles of Brain Tumor Surgery (BRAIN-B).

^eSpine MRI should be delayed by at least 2–3 weeks post surgery to avoid post-surgical artifacts.

Note: All recommendations are category 2A unless otherwise indicated.
Clinical Trials: NCCN believes that the best management of any patient with cancer is in a clinical trial. Participation in clinical trials is especially encouraged.



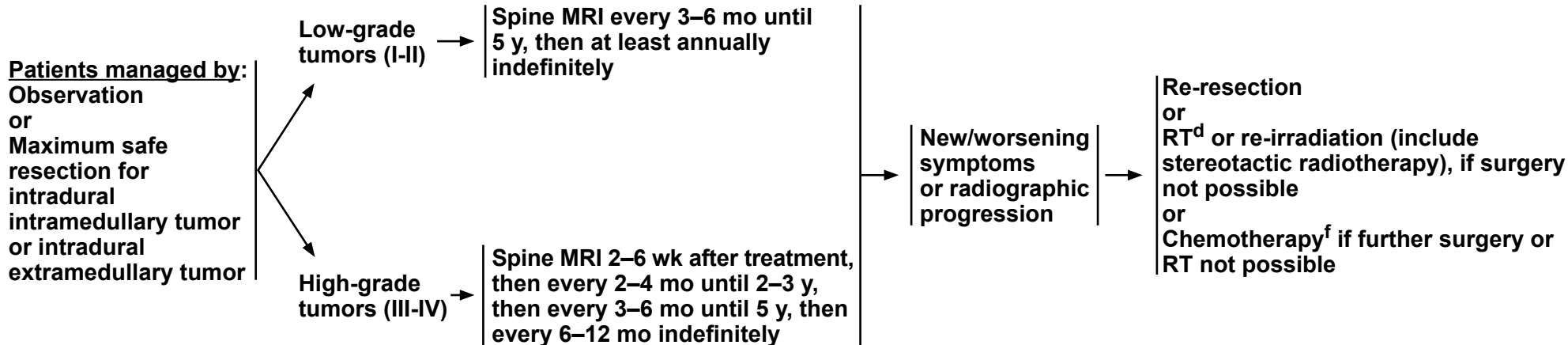
NCCN Guidelines Version 2.2018

Primary Spinal Cord Tumors

FOLLOW-UP^a

RECURRENCE

TREATMENT FOR RECURRENCE



^aSee Principles of Brain and Spine Tumor Imaging (BRAIN-A).

^dSee Principles of Brain and Spinal Cord Tumor Radiation Therapy (BRAIN-C).

^fSee Principles of Brain and Spinal Cord Tumor Systemic Therapy (BRAIN-D) for options according to disease histology.

Note: All recommendations are category 2A unless otherwise indicated.

Clinical Trials: NCCN believes that the best management of any patient with cancer is in a clinical trial. Participation in clinical trials is especially encouraged.



NCCN Guidelines Version 2.2018

Meningiomas

PRESENTATION^a

Radiographic diagnosis by brain MRI:

- Dural-based mass
- Homogeneously contrast-enhancing
- Dural tail
- CSF cleft

Meningioma by radiographic criteria
or
Possible meningioma:

- Consider resection
- Consider octreotide scan if diagnostic doubt exists

TREATMENT^b

Observe (preferred for small asymptomatic tumors; not generally recommended for symptomatic tumors)^h

or

Surgery^{c,d}
(if accessible)^{f,g}

or

RT^{f,g}

Consider RT depending on factors in footnote "b"
In general, postoperative management depends on grade,^e extent of resection, and symptoms, as follows:

- Grade I: observation or consider RT (for symptomatic patients)
- Grade II with complete resection: consider RT
- Grade II with incomplete resection: RT
- Grade III: RT

Follow-up
(See [MENI-2](#))

^aMultidisciplinary input for treatment planning if feasible.

^bTreatment selection should be based on assessment of a variety of inter-related factors, including patient features (eg, age, performance score, comorbidities, treatment preferences), tumor features (eg, size, grade, growth rate, location [proximity to critical structures], potential for causing neurologic consequences if untreated, presence and severity of symptoms), and treatment-related factors (eg, potential for neurologic consequences from surgery/RT, likelihood of complete resection and/or complete irradiation with SRS, treatability of tumor if it progresses, available surgical or radiation oncology expertise and resources). The decision to administer RT after surgery also depends on the extent of resection achieved. Multidisciplinary input for treatment planning is

recommended.

^cPostoperative brain MRI 24–72 hours after surgery.

^d[See Principles of Brain and Spine Tumor Imaging \(BRAIN-A\).](#)

^eWHO Grade I = Benign meningioma, WHO Grade II = Atypical meningioma, WHO Grade III = Malignant (anaplastic) meningioma.

^fRT can be either external-beam or stereotactic radiosurgery (SRS).

^g[See Principles of Brain Tumor Radiation Therapy \(BRAIN-C\).](#)

^hFor asymptomatic meningiomas, observation is preferred for small tumors, with a suggested cutoff of ≤3 cm. Active treatment with surgery and/or RT is recommended in cases with one or more tumor- and/or treatment-related risk factors, such as proximity to the optic nerve.

Note: All recommendations are category 2A unless otherwise indicated.

Clinical Trials: NCCN believes that the best management of any patient with cancer is in a clinical trial. Participation in clinical trials is especially encouraged.



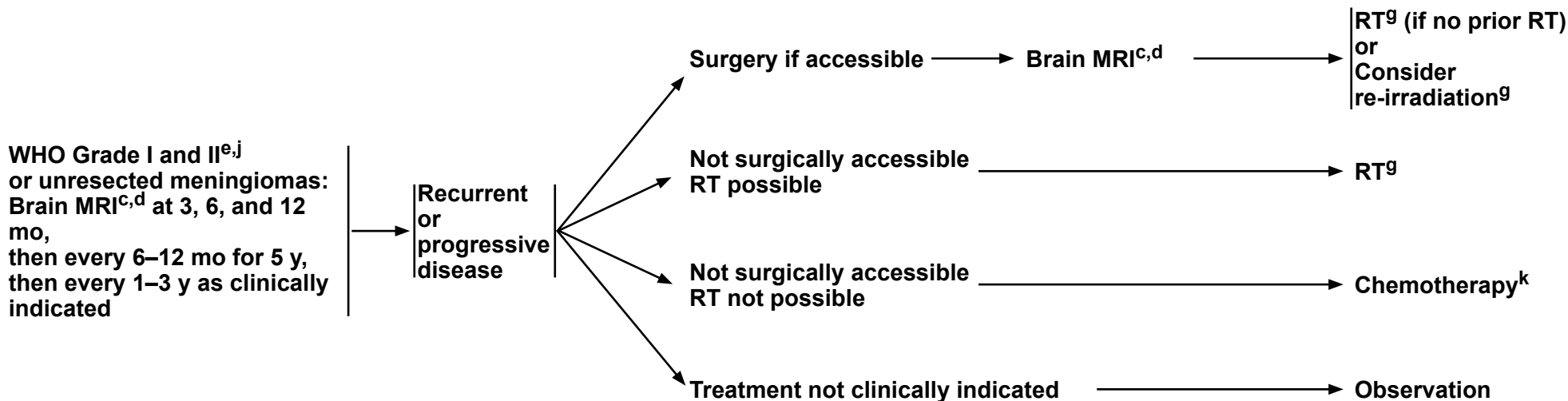
NCCN Guidelines Version 2.2018

Meningiomas

FOLLOW-UPⁱ

RECURRENCE/PROGRESSION

TREATMENT



^cPostoperative brain MRI 24–72 hours after surgery.

^dSee [Principles of Brain and Spine Tumor Imaging \(BRAIN-A\)](#).

^eWHO Grade I = Benign meningioma, WHO Grade II = Atypical meningioma, WHO Grade III = Malignant (anaplastic) meningioma.

^gSee [Principles of Brain and Spinal Cord Tumor Radiation Therapy \(BRAIN-C\)](#).

ⁱConsider less frequent follow-up after 5–10 y.

^jMore frequent imaging may be required for WHO Grade 3 meningiomas, and for meningiomas of any grade that are treated for recurrence or with chemotherapy.

^kSee [Principles of Brain and Spinal Cord Tumor Systemic Therapy \(BRAIN-D\)](#).

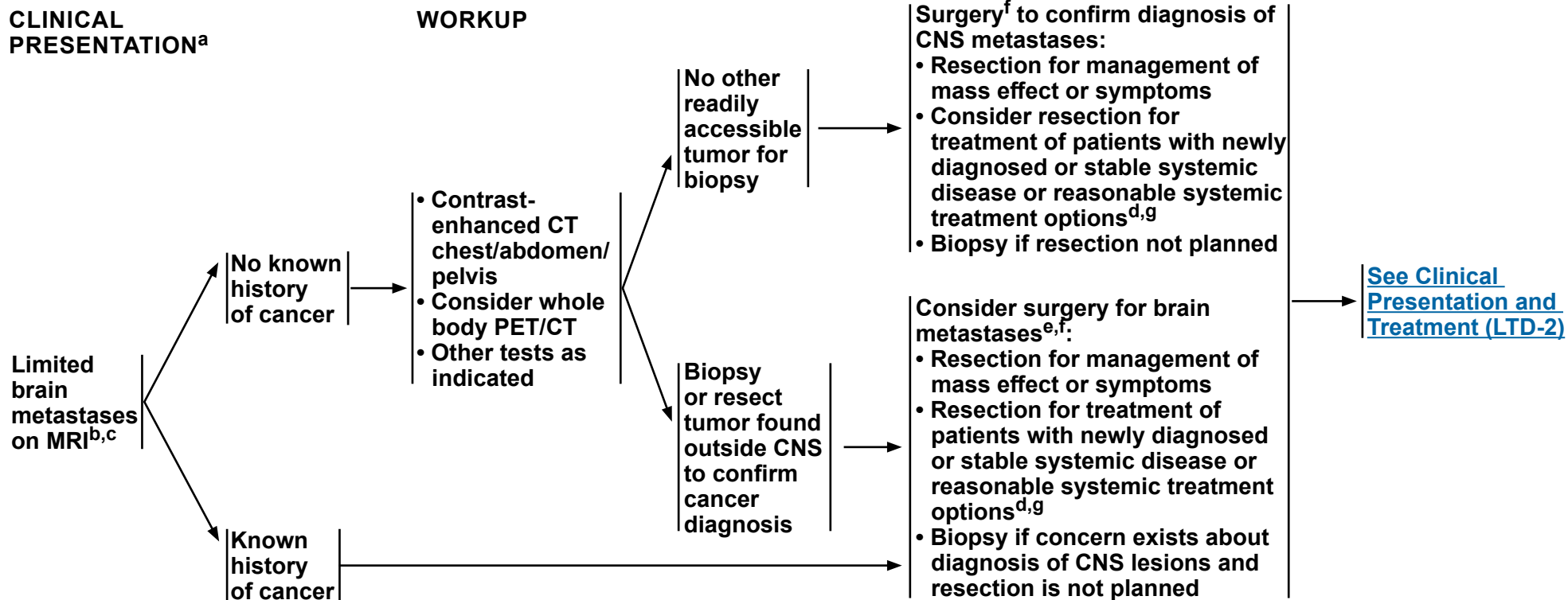
Note: All recommendations are category 2A unless otherwise indicated.

Clinical Trials: NCCN believes that the best management of any patient with cancer is in a clinical trial. Participation in clinical trials is especially encouraged.



NCCN Guidelines Version 2.2018

Limited Brain Metastases



^aSee [Principles of Brain and Spine Tumor Imaging \(BRAIN-A\)](#).

^bConsider a multidisciplinary review in treatment planning, especially once pathology is available (See [Principles of Brain and Spine Tumor Management \(BRAIN-E\)](#)).

^c"Limited" brain metastases defines a group of patients for whom SRS is equally effective and offers significant cognitive protection compared with WBRT. The definition of "limited" brain metastases in terms of number of metastases or total intracranial disease volume is evolving and may depend on the specific clinical situation. (Yamamoto M, Serizawa T, Shuto T, et al. Stereotactic radiosurgery for patients with multiple brain metastases (JLGK0901): a multi-institutional prospective observational study. *Lancet Oncol* 2014;15:387-395.)

^dFor secondary CNS lymphoma treatment may include systemic treatment, whole-brain or focal RT, or combination.

^eThe decision to resect a tumor may depend on the need to establish histologic diagnosis, the size of the lesion, its location, and institutional expertise. For example, smaller (<2 cm), deep, asymptomatic lesions may be considered for treatment with SRS versus larger (>2 cm), symptomatic lesions that may be more appropriate for surgery. (Ewend MG, Morris DE, Carey LA, Ladha AM, Brem S: Guidelines for the initial management of metastatic brain tumors: role of surgery, radiosurgery, and radiation therapy. *J Natl Compr Cancer Netw* 2008; 6:505-513.)

^fSee [Principles of Brain Tumor Surgery \(BRAIN-B\)](#).


^gIf an active agent exists (eg, cytotoxic, targeted, or immune modulating), trial of systemic therapy with good CNS penetration may be considered in select patients (eg, for patients with small asymptomatic brain metastases from melanoma or ALK rearrangement positive NSCLC), it is reasonable to hold on treating with radiation to see if systemic therapy can control the brain metastases. See [Principles of Brain and Spinal cord Tumor Systemic Therapy \(BRAIN-D\)](#).

Note: All recommendations are category 2A unless otherwise indicated.

Clinical Trials: NCCN believes that the best management of any patient with cancer is in a clinical trial. Participation in clinical trials is especially encouraged.

CLINICAL PRESENTATION

TREATMENT^g



^dFor secondary CNS lymphoma treatment may include systemic treatment, whole-brain or focal RT, or combination.

^gIf an active agent exists (eg, cytotoxic, targeted, or immune modulating), trial of systemic therapy with good CNS penetration may be considered in select patients (eg, for patients with small asymptomatic brain metastases from melanoma or ALK rearrangement positive NSCLC); it is reasonable to hold on treating with radiation to see if systemic therapy can control the brain metastases. [See Principles of Brain and Spinal cord Tumor Systemic Therapy \(BRAIN-D\)](#).

^h[See Principles of Brain and Spinal Cord Tumor Radiation Therapy \(BRAIN-C\)](#).

ⁱSRS is preferred when safe, especially for low tumor volume, to both the resection cavity and any other non-resected brain metastases. WBRT is generally not recommended but may be appropriate in some rare clinical circumstances (eg, ventricle is violated, cerebellar lesions, risk of meningeal disease, need for complete CNS control before going on protocol, not good SRS candidate for technical reasons, poor PS, advanced age).

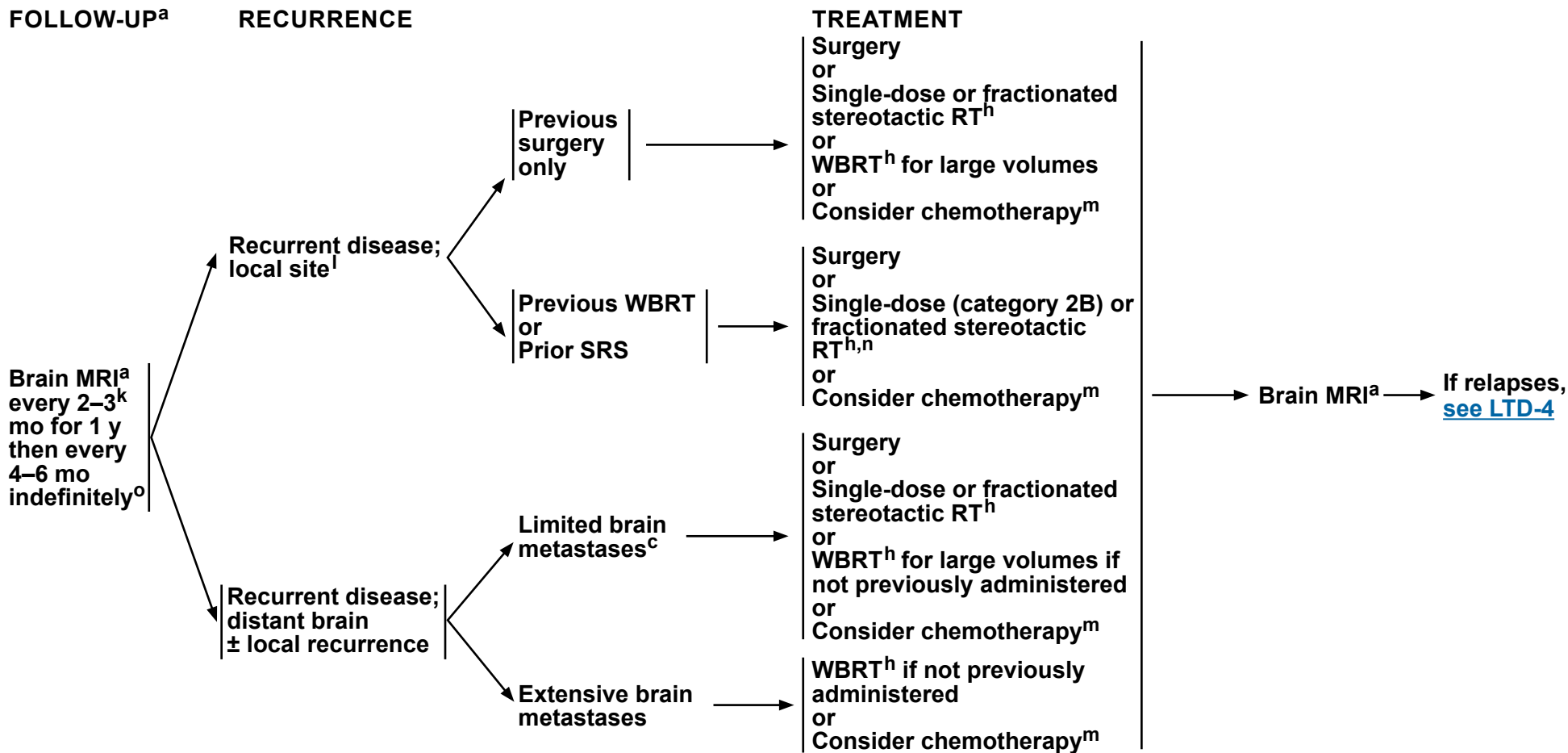
^jFor brain metastases not managed with resection, SRS + WBRT is generally not recommended but may be appropriate in some rare clinical circumstances. Brown 2016 showed that for tumors <3 cm, SRS + WBRT improved local control compared with SRS alone, but did not significantly improve survival, and was associated with greater cognitive decline and poorer quality of life. (Brown PD, Jaeckle K, Ballman KV, et al. Effect of radiosurgery alone vs radiosurgery with whole brain radiation therapy on cognitive function in patients with 1 to 3 brain metastases: a randomized clinical trial. JAMA 2016;316:401-409).

Note: All recommendations are category 2A unless otherwise indicated.
Clinical Trials: NCCN believes that the best management of any patient with cancer is in a clinical trial. Participation in clinical trials is especially encouraged.



NCCN Guidelines Version 2.2018

Limited Brain Metastases



^aSee Principles of Brain and Spine Tumor Imaging (BRAIN-A).

^c"Limited" brain metastases defines a group of patients for whom SRS is equally effective and offers significant cognitive protection compared with WBRT. The definition of "limited" brain metastases in terms of number of metastases or total intracranial disease volume is evolving and may depend on the specific clinical situation. (Yamamoto M, Serizawa T, Shuto T, et al. Stereotactic radiosurgery for patients with multiple brain metastases (JLKG0901): a multi-institutional prospective observational study. *Lancet Oncol* 2014;15:387-395.)

^hSee Principles of Brain and Spinal Cord Tumor Radiation Therapy (BRAIN-C).

^kMRI every 2 months (instead of 3 mo) for those patients treated with SRS alone.

^lAfter stereotactic radiosurgery, recurrence on radiograph can be confounded by treatment effects; consider tumor tissue sampling if there is a high index of suspicion of recurrence.

^mSee Principles of Brain and Spinal Cord Tumor Systemic Therapy (BRAIN-D).

ⁿIf patient had previous SRS with a good response >6 mo, then reconsider SRS if imaging supports active tumor and not necrosis.

^oImaging to evaluate emergent signs/symptoms is appropriate at any time.

Note: All recommendations are category 2A unless otherwise indicated.

Clinical Trials: NCCN believes that the best management of any patient with cancer is in a clinical trial. Participation in clinical trials is especially encouraged.

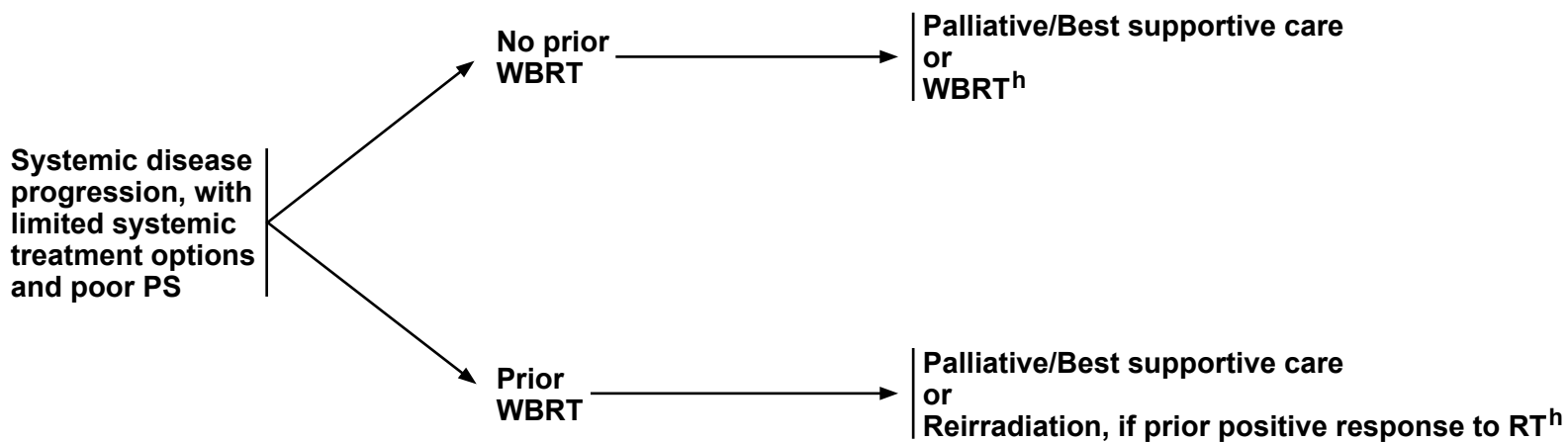


NCCN Guidelines Version 2.2018

Limited Brain Metastases

RECURRENCE

TREATMENT



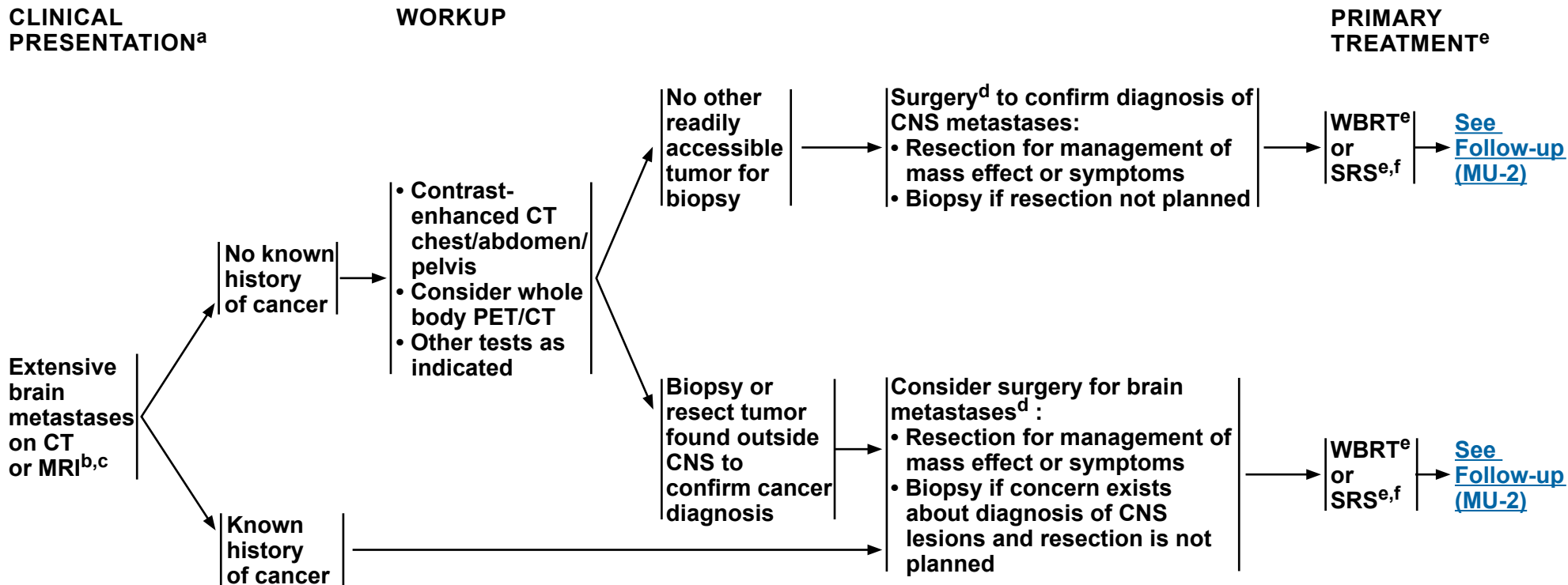
^hSee [Principles of Brain and Spinal Cord Tumor Radiation Therapy \(BRAIN-C\)](#).

Note: All recommendations are category 2A unless otherwise indicated.
Clinical Trials: NCCN believes that the best management of any patient with cancer is in a clinical trial. Participation in clinical trials is especially encouraged.



NCCN Guidelines Version 2.2018

Extensive Brain Metastases



^aSee [Principles of Brain and Spine Tumor Imaging \(BRAIN-A\)](#).

^bConsider a multidisciplinary review in treatment planning, especially once pathology is available ([See Principles of Brain and Spine Tumor Management \(BRAIN-E\)](#)).

^cIncludes all cases that do not fit the definition of "limited brain metastases" on [LTD-1](#).

^dSee [Principles of Brain Tumor Surgery \(BRAIN-B\)](#).

^eSee [Principles of Brain and Spinal Cord Tumor Radiation Therapy \(BRAIN-C\)](#).

^fSRS can be considered for patients with good performance and low overall tumor volume and/or radioresistant tumors such as melanoma. (Yamamoto M, Serizawa T, Shuto T, et al. Stereotactic radiosurgery for patients with multiple brain metastases (JLGK0901): a multi-institutional prospective observational study. *Lancet Oncol* 2014;15:387-395.)

Note: All recommendations are category 2A unless otherwise indicated.
Clinical Trials: NCCN believes that the best management of any patient with cancer is in a clinical trial. Participation in clinical trials is especially encouraged.



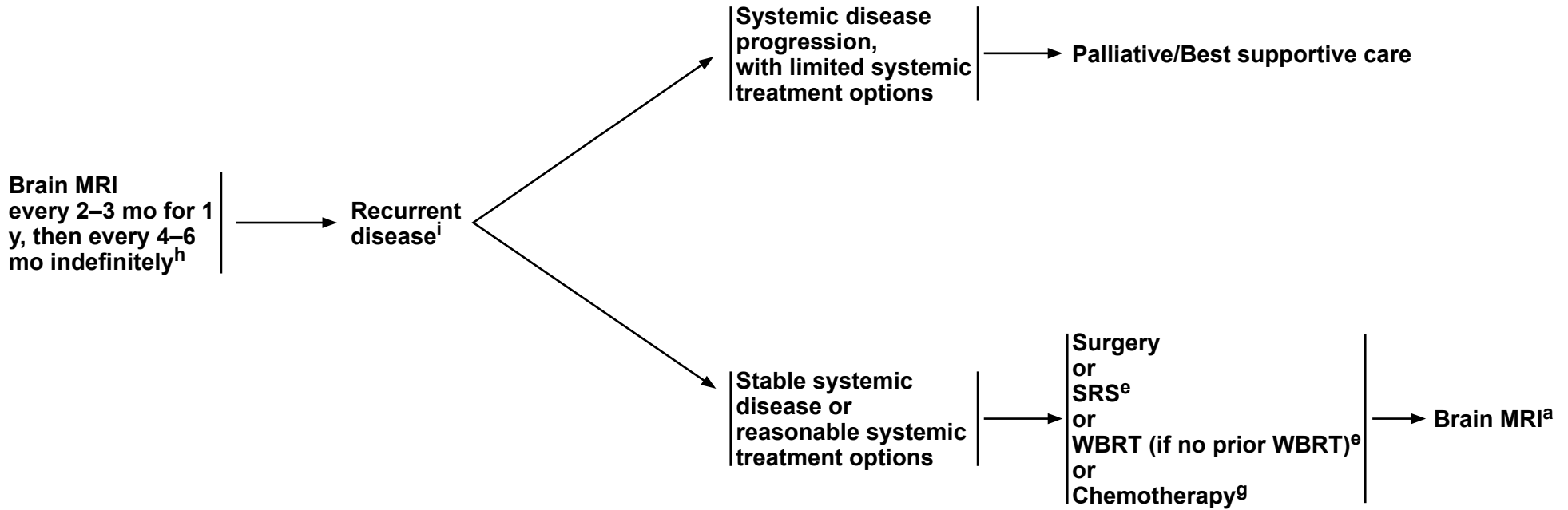
NCCN Guidelines Version 2.2018

Extensive Brain Metastases

FOLLOW-UP^a

RECURRENCE

TREATMENT



^aSee Principles of Brain and Spine Tumor Imaging (BRAIN-A).

^eSee Principles of Brain and Spinal Cord Tumor Radiation Therapy (BRAIN-C).

^gSee Principles of Brain and Spinal Cord Tumor Systemic Therapy (BRAIN-D).

^hImaging to evaluate emergent signs/symptoms is appropriate at any time.

ⁱAfter stereotactic radiosurgery, recurrence on radiograph can be confounded by treatment effects; consider tumor tissue sampling if there is a high index of suspicion of recurrence.

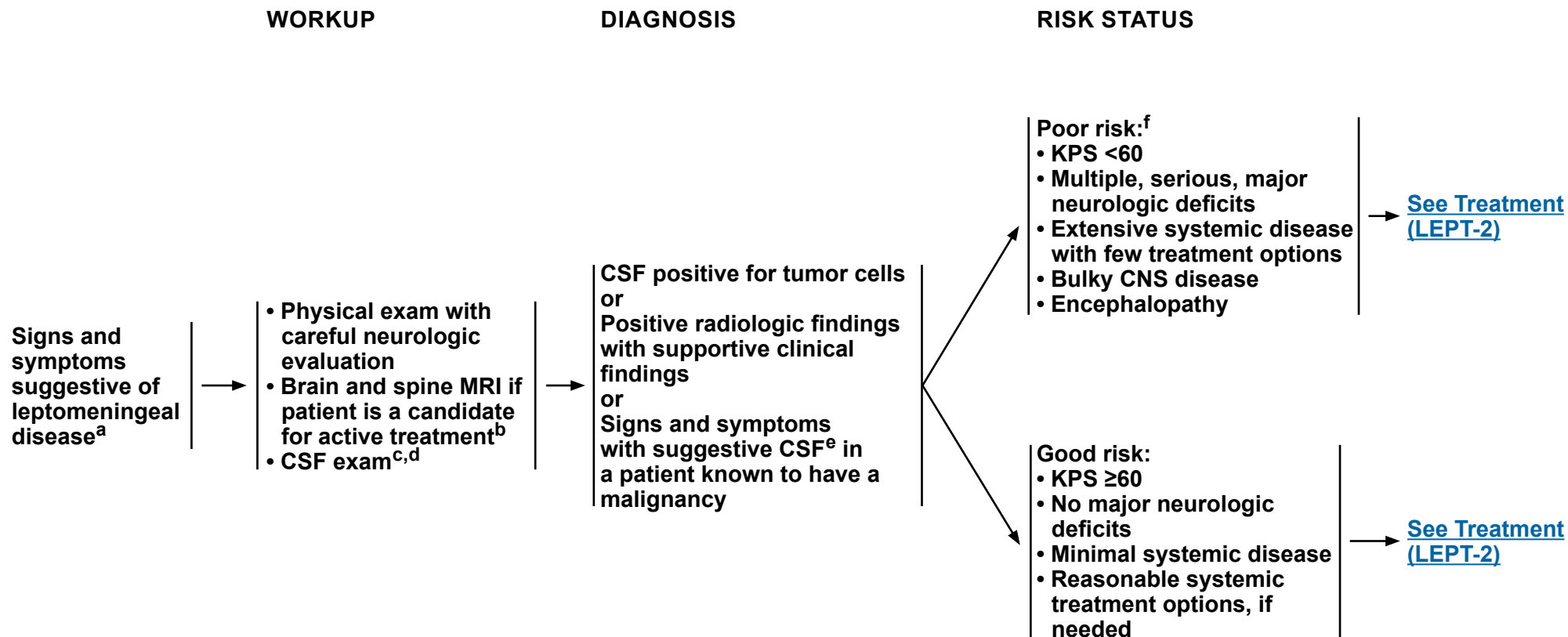
Note: All recommendations are category 2A unless otherwise indicated.

Clinical Trials: NCCN believes that the best management of any patient with cancer is in a clinical trial. Participation in clinical trials is especially encouraged.



NCCN Guidelines Version 2.2018

Leptomeningeal Metastases



^aConsider a multidisciplinary review in treatment planning, especially once pathology is available ([See Principles of Brain and Spine Tumor Management \[BRAIN-E\]](#)).

^b[See Principles of Brain and Spine Tumor Imaging \(BRAIN-A\)](#).

^cCaution is indicated in patients who are anticoagulated, thrombocytopenic, or who have a bulky intra-cranial mass.

^dCSF analysis should include: a cell count, differential, glucose, and protein. For solid malignancies, order cytopathology. When available, assessment of circulating tumor cells (CTC) increases sensitivity of tumor cell detection and assessment of response to treatment. For hematologic malignancies, use flow cytometry.

^eSuggestive CSF includes high WBC, low glucose, and high protein. If CSF is not positive for tumor cells, a second lumbar puncture is sometimes helpful. This is a volume-dependent test and ideally ≥10 mL should be sent for cytologic analysis.

^fPatients with exceptionally chemosensitive tumors (eg, small cell lung cancer, lymphoma) may be treated.

Note: All recommendations are category 2A unless otherwise indicated.
Clinical Trials: NCCN believes that the best management of any patient with cancer is in a clinical trial. Participation in clinical trials is especially encouraged.



NCCN Guidelines Version 2.2018

Leptomeningeal Metastases

RISK STATUS

TREATMENT

Poor risk:^f

- KPS <60
- Multiple, serious, major neurologic deficits
- Extensive systemic disease with few treatment options
- Bulky CNS disease
- Encephalopathy



Palliative/Best supportive care and
Consider involved-field RT to neurologically symptomatic or painful sites for palliation (including spine and intracranial disease)

Good risk:

- KPS ≥60
- No major neurologic deficits
- Minimal systemic disease
- Reasonable systemic treatment options, if needed



WBRT and/or involved-field RT^g to bulky disease and neurologically symptomatic or painful sites (including spine and intracranial disease)



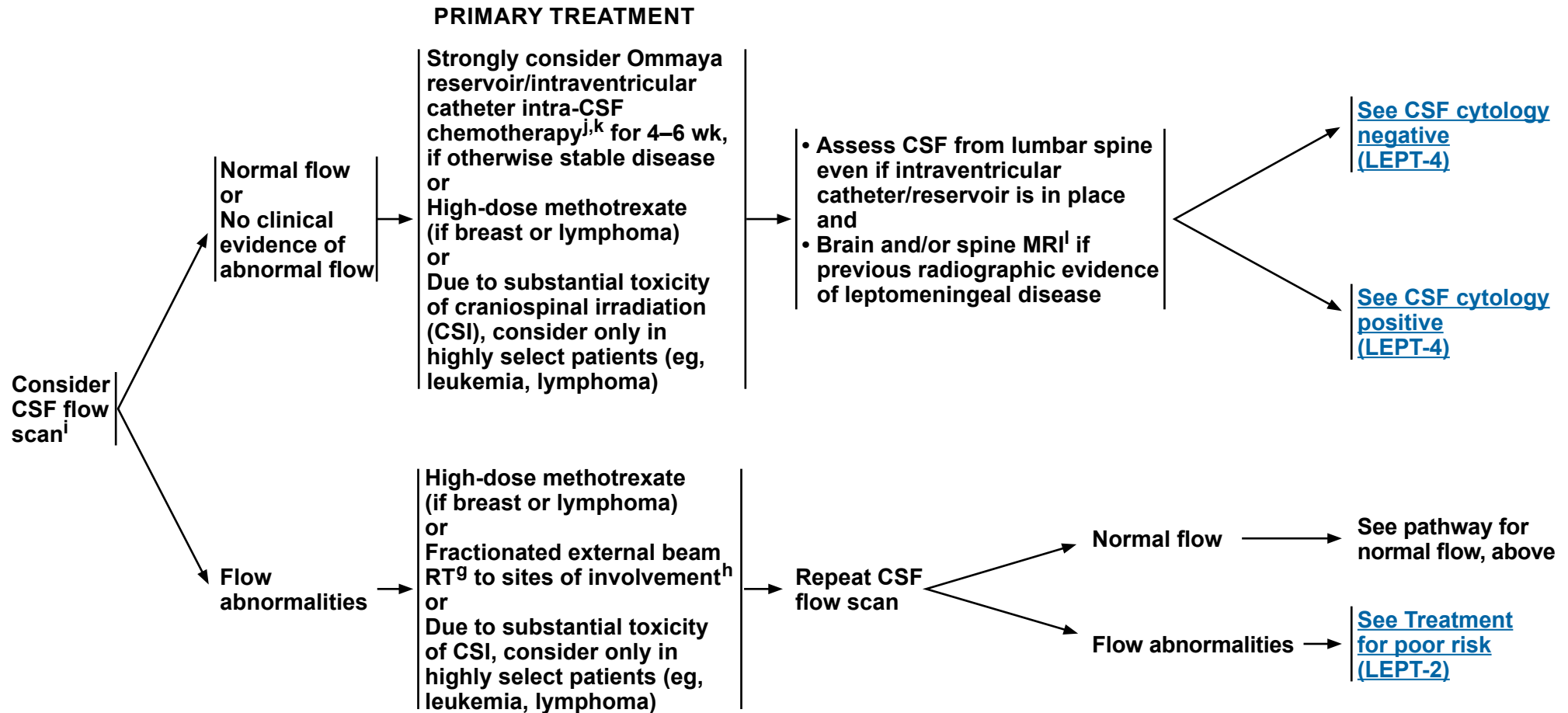
[See CSF flow scan \(LEPT-3\)](#)

^fPatients with exceptionally chemosensitive tumors (eg, small cell lung cancer, lymphoma) may be treated.

^gSee [Principles of Brain and Spinal Cord Tumor Radiation Therapy \(BRAIN-C\)](#).

Note: All recommendations are category 2A unless otherwise indicated.

Clinical Trials: NCCN believes that the best management of any patient with cancer is in a clinical trial. Participation in clinical trials is especially encouraged.



^gSee [Principles of Brain and Spinal Cord Tumor Radiation Therapy \(BRAIN-C\)](#).

^hUsually WBRT and/or partial spine field recommended.

ⁱHighly recommended if symptoms or conventional imaging suggests CSF flow blockage.

^jSee [Principles of Brain and Spinal Cord Tumor Systemic Therapy \(BRAIN-D\)](#).

^kIntra-CSF chemotherapy can start with radiation (concomitant) or high-dose methotrexate for lymphoma or CSI.

^lSee [Principles of Brain and Spine Tumor Imaging \(BRAIN-A\)](#).

Note: All recommendations are category 2A unless otherwise indicated.

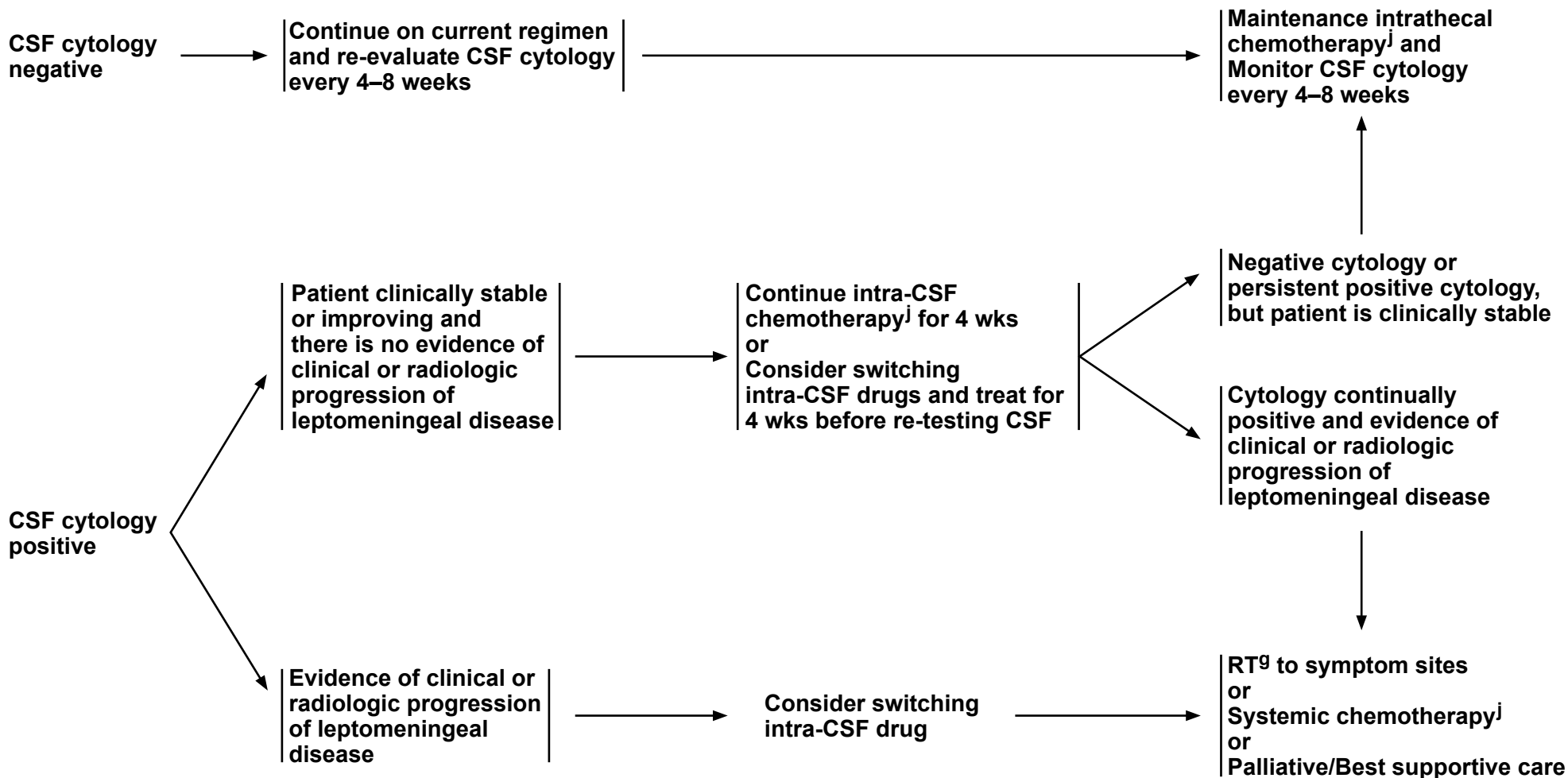
Clinical Trials: NCCN believes that the best management of any patient with cancer is in a clinical trial. Participation in clinical trials is especially encouraged.



NCCN Guidelines Version 2.2018

Leptomeningeal Metastases

TREATMENT



^gSee Principles of Brain and Spinal Cord Tumor Radiation Therapy (BRAIN-C).

^jSee Principles of Brain and Spinal Cord Tumor Systemic Therapy (BRAIN-D).

Note: All recommendations are category 2A unless otherwise indicated.
Clinical Trials: NCCN believes that the best management of any patient with cancer is in a clinical trial. Participation in clinical trials is especially encouraged.



NCCN Guidelines Version 2.2018

Metastatic Spine Tumors

PRESENTATION

Patient diagnosed with cancer or patient with newly discovered abnormality suspicious for spine metastasis

Asymptomatic
(Incidental finding)

Symptomatic:
• Severe, new, or progressive pain or neurologic symptoms

WORKUP

- Systemic imaging (ie, contrast-enhanced chest/abdominal/pelvic CT or whole body PET/CT, bone scan as indicated for metastatic workup)
- Biopsy^a if it alters management

Spinal MRI^{b,c,d}
(urgent in the event of neurologic symptoms)

TREATMENT

- Observation
Spine MRI^d in 6–8 weeks, then every 2–3 months until the nature of the lesion is established
- Surgery/focal RT or chemotherapy^e are options for patients with asymptomatic epidural disease

No tumor

Spinal cord compression^f

No spinal cord compression^d

[See SPINE-2](#)

^aBiopsy if remote history of cancer.

^bIf the patient is unable to have an MRI, then a CT myelogram is recommended.

^c15%–20% of patients have additional lesions. Highly recommend complete spine imaging.

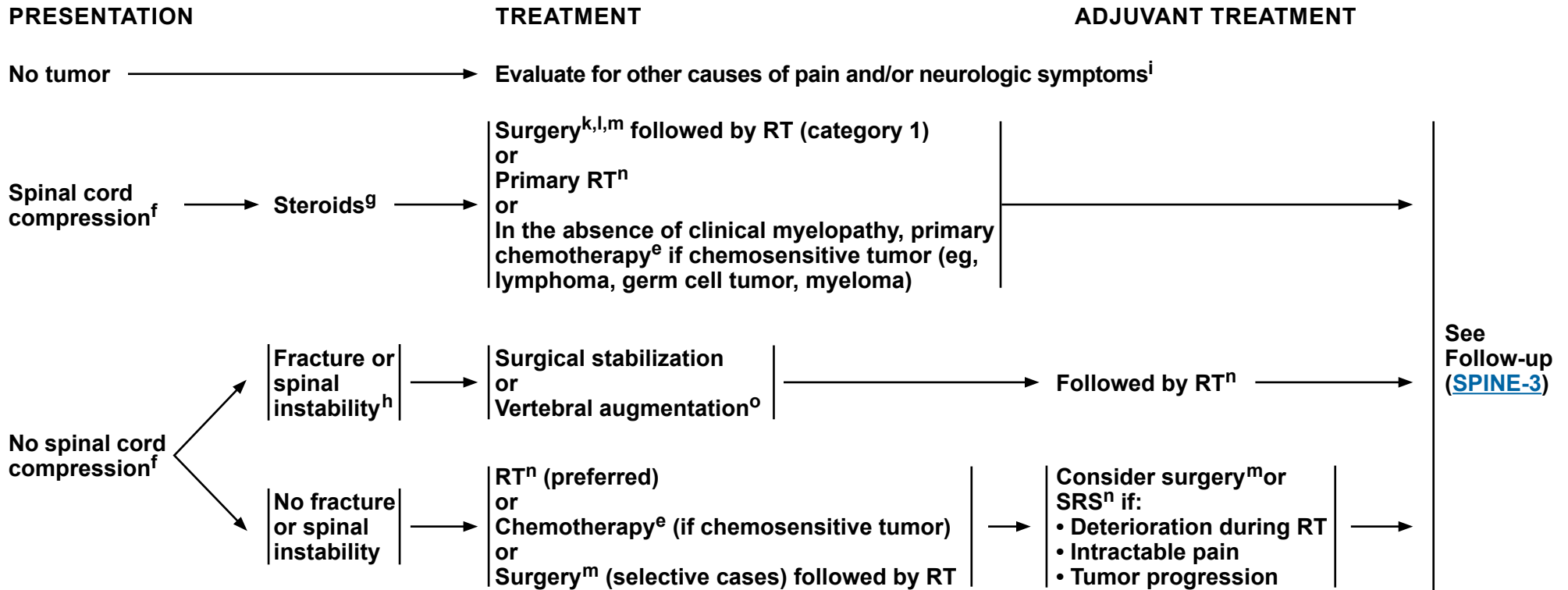
^d[See Principles of Brain and Spine Tumor Imaging \(BRAIN-A\).](#)

^e[See Principles of Brain and Spinal Cord Tumor Systemic Therapy \(BRAIN-D\).](#)

^fIncludes cauda equina syndrome.

Note: All recommendations are category 2A unless otherwise indicated.

Clinical Trials: NCCN believes that the best management of any patient with cancer is in a clinical trial. Participation in clinical trials is especially encouraged.



^eSee Principles of Brain and Spinal Cord Tumor Systemic Therapy (BRAIN-D).

^fIncludes cauda equina syndrome.

^gThe recommended minimum dose of steroids is 4 mg of dexamethasone every 6 hours, although dose of steroids may vary (10–100 mg). A randomized trial supported the use of high-dose steroids (Sorensen PS, et al. Eur J Cancer 1994;30A:22-27).

^hSpinal instability is grossly defined as the presence of significant kyphosis or subluxation (deformity), or of significantly retropulsed bone fragment.

ⁱConsider alternative diagnosis of leptomeningeal disease (See LEPT-1).

^kTumor resection with or without spinal stabilization. Surgery should be focused on anatomic pathology.

^lRegarding surgery, note the following:

- Category 1 evidence supports the role of surgery in patients with a solitary epidural spinal cord compression by a tumor not known to be radiosensitive and who are willing to undergo surgery. (Patchell RA, et al. Lancet 2005;366(9486):643-648)
- For surgery, patients with hematologic tumors (ie, lymphoma, myeloma, leukemia) should be excluded, life expectancy should be ≥3 mo, and the patient should not be paraplegic for >24 h.
- Surgery is especially indicated if the patient has any of the following: spinal instability, no history of cancer, rapid neurologic deterioration during RT, previous RT to site, and single-site spinal cord compression.

^mPostoperative spine MRI should be delayed by at least 2–3 weeks to avoid post-surgical artifacts. See Principles of Brain Tumor Surgery (BRAIN-B).

ⁿRecommend stereotactic radiosurgery if oligometastases and radioresistant. See Principles of Brain and Spinal Cord Tumor Radiation Therapy (BRAIN-C).

^oVertebral augmentation: vertebroplasty, kyphoplasty.

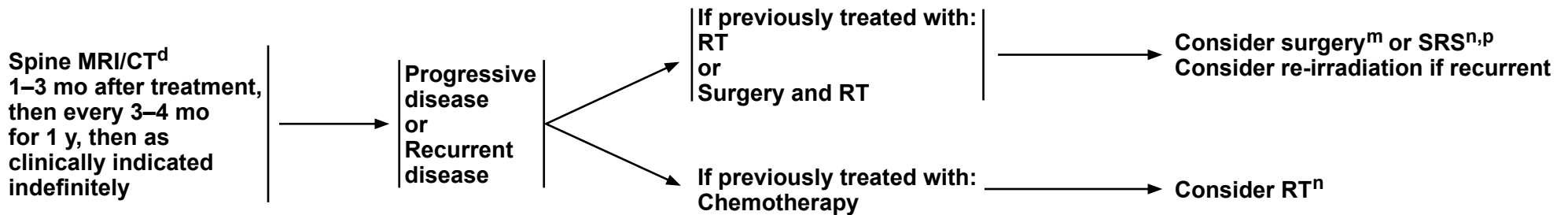
Note: All recommendations are category 2A unless otherwise indicated.

Clinical Trials: NCCN believes that the best management of any patient with cancer is in a clinical trial. Participation in clinical trials is especially encouraged.

FOLLOW-UP

PRESENTATION (Symptom- or MRI-based)

TREATMENT FOR RECURRENCE OR PROGRESSIVE DISEASE



^dSee [Principles of Brain and Spine Tumor Imaging \(BRAIN-A\)](#).

^mPostoperative spine MRI should be delayed by at least 2–3 weeks to avoid post-surgical artifacts. See [Principles of Brain Tumor Surgery \(BRAIN-B\)](#).

ⁿRecommend stereotactic radiosurgery if oligometastases and radioresistant. See [Principles of Brain and Spinal Cord Tumor Radiation Therapy \(BRAIN-C\)](#).

^pGary AK, et al. Prospective evaluation of spinal reirradiation by using stereotactic body radiation therapy: The University of Texas MD Anderson Cancer Center experience. *Cancer* 2011;117:3509-3516.

Note: All recommendations are category 2A unless otherwise indicated.
Clinical Trials: NCCN believes that the best management of any patient with cancer is in a clinical trial. Participation in clinical trials is especially encouraged.

**PRINCIPLES OF BRAIN AND SPINE TUMOR IMAGING¹**

This is a list of imaging modalities available and used in neuro-oncology primarily to make treatment decisions. The most common use for MR spectroscopy, MR perfusion, and PET scanning is to differentiate radiation necrosis from active tumor, as this might obviate the need for surgery or the discontinuation of an effective therapy. Imaging is always recommended to investigate emergent signs or symptoms.

- **MRI² of the brain and spine (with and without contrast):**
 - ▶ Gold standard
 - ▶ Provides a “static” picture of tumors
 - ▶ **Benefits:** Provides a reasonably good delineation of tumors; higher grade tumors and brain leptomeningeal metastasis usually enhance; lower grade tumors usually do not enhance
 - ▶ **Limitations:** Sensitive to movement, metallic objects cause artifact, patients with implantable devices cannot have an MRI, claustrophobia may be an issue, or renal insufficiency
 - ▶ Postoperative brain MRI should be performed within 24–72 hours for gliomas and other brain tumors to determine extent of resection.
 - ▶ Postoperative spine MRI should be delayed by at least 2–3 weeks to avoid post-surgical artifacts.
- **CT of the brain and spine (with and without contrast):**
 - ▶ Should be used in patients who cannot have an MRI
 - ▶ **Benefits:** Claustrophobia or implantable devices are not an issue, can be done faster than an MRI
 - ▶ **Limitations:** Lacks resolution of MRI, especially in posterior fossa, or renal insufficiency
- **MR spectroscopy: Assess metabolites within tumors and normal tissue**
 - ▶ May be useful in differentiating tumor from radiation necrosis; may be helpful in grading tumors or assessing response
 - ▶ Area most abnormal would be the best place to target for a biopsy
 - ▶ **Limitations:** Tumors near vessels, air spaces, or bone. Extra time in MRI and others as noted under MRI
- **MR perfusion: Measures cerebral blood volume in tumors**
 - ▶ May be useful in differentiating grade of tumor or tumor versus radiation necrosis. Area of highest perfusion would be the best place to biopsy.
 - ▶ **Limitations:** Tumors near vessels, air spaces, bone, small-volume lesions, or tumors in the spinal cord. Extra time in MRI and others as noted under MRI.
- **Brain PET scanning: Assess metabolism within tumor and normal tissue by using radiolabeled tracers**
 - ▶ May be useful in differentiating tumor from radiation necrosis but has some limitations; may also correlate with tumor grade or provide the optimal area for biopsy
 - ▶ **Limitations:** Accuracy of interpretations, availability of equipment and isotopes

¹The imaging modalities listed may not be available at every institution.

²Wen PY, Macdonald DR, Reardon DA, et al. Updated response assessment for high-grade gliomas: Response assessment in neuro-oncology working group. J Clin Oncol 2010;28:1963-1972.

Note: All recommendations are category 2A unless otherwise indicated.

Clinical Trials: NCCN believes that the best management of any patient with cancer is in a clinical trial. Participation in clinical trials is especially encouraged.



PRINCIPLES OF BRAIN TUMOR SURGERY

Guiding Principles

- Gross total resection when appropriate
- Minimal surgical morbidity
- Accurate diagnosis

Factors

- Age
- Performance status (PS)
- Feasibility of decreasing the mass effect with surgery
- Resectability, including number of lesions, location of lesions, time since last surgery (recurrent patients)
- New versus recurrent tumor
- Suspected pathology – benign vs. malignant, possibility of other non-cancer diagnoses, projected natural history

Options

- Gross total resection where feasible
- Stereotactic biopsy
- Open biopsy/debulking followed by planned observation or adjuvant therapy
- Chemotherapy implants, when indicated (See footnote h on [GLIO-1](#))

Tissue

- Sufficient tissue to pathologist for neuropathology evaluation and molecular correlates
 - Frozen section analysis when possible to help with intraoperative decision-making
 - Review by experienced neuropathologist
-
- Postoperative brain MRI should be performed within 24–72 hours for gliomas and other brain tumors to determine the extent of resection. Postoperative spine MRI should be delayed by at least 2–3 weeks to avoid post-surgical artifacts.
 - The extent of resection should be judged on the postoperative study and used as a baseline to assess further therapeutic efficacy or tumor progression.

Note: All recommendations are category 2A unless otherwise indicated.

Clinical Trials: NCCN believes that the best management of any patient with cancer is in a clinical trial. Participation in clinical trials is especially encouraged.

**PRINCIPLES OF BRAIN AND SPINAL CORD TUMOR RADIATION THERAPY****Low-Grade Gliomas (Grades I/II)**

- Tumor volumes are best defined using pre- and postoperative imaging, usually fluid-attenuated inversion recovery (FLAIR) and/or T2 signal abnormality on MRI for gross tumor volume (GTV). Clinical target volume (CTV) (GTV plus 1–2 cm margin) should receive 45–54 Gy in 1.8–2.0 Gy fractions.^{1,2,3} Consider RT dose escalation to 59.4–60 Gy for IDH-wildtype low-grade gliomas, as these patients may have a more aggressive course of disease.
- SRS has not been established to have a role in the management of low-grade gliomas. Phase I trials using SRS do not support its role as initial treatment.

High-Grade Gliomas (Grades III/IV)

- The GTV is best defined using pre- and postoperative MRI imaging using enhanced T1 and FLAIR/T2. To account for sub-diagnostic tumor infiltration, the GTV is expanded 1–2 cm (CTV) for grade III, and up to 2–2.5 cm (CTV) for grade IV. Although trials in GBM have historically used CTV expansion in the range of 2 cm, smaller CTV expansions are supported in the literature and can be appropriate. A PTV of margin of 3–5 mm is typically added to the CTV to account for daily setup errors and image registration. Daily image guidance is required if smaller PTV margins are used. When edema as assessed by T2/FLAIR is included in an initial phase of treatment, fields are usually reduced for the last phase of the treatment (boost). The boost target volume will typically encompass only the gross residual tumor and the resection cavity. A range of acceptable clinical target volume margins exists. Both strategies appear to produce similar outcomes.⁴
- The recommended dose is 60 Gy in 2.0 Gy fractions or 59.4 Gy in 1.8 Gy fractions. A slightly lower dose, such as 55.8–59.4 Gy in 1.8 Gy or 57 Gy in 1.9 Gy fractions, can be applied when the tumor volume is very large (gliomatosis) or for grade III astrocytoma. If a boost volume is used, the initial phase of the RT plan will receive 46 Gy in 2 Gy fractions or 45–50.4 Gy in 1.8 Gy fractions. The boost plan will typically then receive 14 Gy in 2 Gy fractions or 9–14.4 Gy in 1.8 Gy fractions.⁴
- In poorly performing patients or the elderly a hypofractionated accelerated course is reasonable with the goal of completing the treatment in 2–4 weeks. Typical fractionation schedules are 34 Gy/10 fx, 40.05 Gy/15 fx, or 50 Gy/20 fx.^{5,6} Alternatively, a shorter fractionation schedule of 25 Gy/5 fx may be considered for elderly and/or frail patients with smaller tumors for whom a longer course of treatment would not be tolerable.⁷

Ependymoma

- **Limited Fields:** Intracranial tumor volumes are best defined using pre- and postoperative imaging, usually enhanced T1 and or FLAIR/T2. Anatomic areas that are touched by preoperative tumor volume plus postoperative signal abnormality on MRI for GTV; CTV (GTV plus 1–2 cm margin) should receive 54–59.4 Gy in 1.8–2.0 Gy fractions.
- **Craniospinal:** To reduce toxicity from craniospinal irradiation in adults, consider the use of intensity-modulated radiotherapy or protons if available. Whole brain and spine (to bottom of thecal sac) receive 36 Gy in 1.8 Gy fractions, followed by limited field to spine lesions to 45 Gy. (Gross metastatic lesions below the conus could receive higher doses of 54–60 Gy).^{8,9} Primary intracranial site should receive total dose of 54–59.4 Gy in 1.8–2.0 Gy fractions. Consider boosting any gross intracranial metastatic sites to a higher dose while respecting normal tissue tolerances.
- For spine ependymomas, see section on primary spinal cord tumors ([BRAIN-C 2 of 4](#)).^{10,11}

Note: All recommendations are category 2A unless otherwise indicated.

Clinical Trials: NCCN believes that the best management of any patient with cancer is in a clinical trial. Participation in clinical trials is especially encouraged.

[Continued](#)
[References](#)

BRAIN-C
1 OF 4



PRINCIPLES OF BRAIN AND SPINAL CORD TUMOR RADIATION THERAPY

Adult Medulloblastoma

• **Standard risk for recurrence:**

- ▶ **Conventional dose: 30–36 Gy CSI^{12,†} and boosting the primary brain site to 54–55.8 Gy with or without adjuvant chemotherapy**
- ▶ **Reduced dose: May consider reduced dose radiation with adjuvant chemotherapy: 23.4 Gy CSI^{12,13,††} and boosting the primary brain site to 54–55.8 Gy¹**

High risk for recurrence: 36 Gy CSI^{3,†} with boosting primary brain site to 54–55.8 Gy with adjuvant chemotherapy.

Primary CNS Lymphoma

- **WBRT may be withheld in the primary setting in patients treated with chemotherapy. When used, low-dose WBRT should be limited to 23.4 Gy in 1.8 Gy fractions following a CR to chemotherapy.¹⁴ For less than complete response (CR), consider WBRT to 30–36 Gy followed by a limited field to gross disease to 45 Gy or focal radiation to residual disease only.¹⁵⁻¹⁸**
- **For patients who are not candidates for chemo: WBRT doses of 24–36 Gy followed by a boost to gross disease for a total dose of 45 Gy.**

Primary Spinal Cord Tumors

- **Doses of 45–54 Gy are recommended using fractions of 1.8 Gy. In tumors below the conus medullaris higher doses up to 60 Gy can be delivered.**

Meningiomas

- **WHO grade I meningiomas may be treated by fractionated conformal radiotherapy with doses of 45–54 Gy.**
 - ▶ **Stereotactic or image-guided therapy is recommended when using tight margins or when close to critical structures. Conformal radiation therapy (eg, 3D-CRT, IMRT, VMAT) is recommended to spare critical structures and uninvolved tissue.**
 - ▶ **WHO grade I meningiomas may also be treated with SRS doses of 12–16 Gy in a single fraction when appropriate.**
- **For WHO grade II meningiomas undergoing radiation, treatment should be directed to gross tumor (if present) and surgical bed + a margin (1–2 cm) to a dose of 54–60 Gy in 1.8–2.0 Gy fractions. Consider limiting margin expansion into the brain parenchyma if there is no evidence of brain invasion.**
- **WHO grade III meningiomas should be treated as malignant tumors with treatment directed to gross tumor (if present) and surgical bed + a margin (2–3 cm) receiving 59.4–60 Gy in 1.8–2.0 Gy fractions.**

††Regimen supported by data from pediatric trials only.

†To reduce toxicity from craniospinal irradiation in adults, consider the use of intensity-modulated radiotherapy or protons if available.

Note: All recommendations are category 2A unless otherwise indicated.

Clinical Trials: NCCN believes that the best management of any patient with cancer is in a clinical trial. Participation in clinical trials is especially encouraged.

[Continued](#)
[References](#)

BRAIN-C
2 OF 4

**PRINCIPLES OF BRAIN AND SPINAL CORD TUMOR RADIATION THERAPY****Brain Metastases**

- **Whole brain radiotherapy (WBRT):** Doses vary between 20 and 40 Gy delivered in 5–20 fractions. The standard regimens include 30 Gy in 10 fractions or 37.5 Gy in 15 fractions. Nevertheless, 20 Gy in 5 fractions is a good option in poor performers.¹⁹ For better prognosis patients consider memantine during and after WBRT for a total of 6 months.²⁰
- **SRS:** Maximum marginal doses from 24–15 Gy based on tumor volume is recommended.²¹⁻²⁴
- SRS generally preferred over WBRT limited brain metastases, with the possible exception of patients with poor performance or uncontrolled systemic tumor.

Leptomeningeal Metastases

- Volumes and dose depend on primary source and sites requiring palliation.

Metastatic Spine

- Doses to vertebral body metastases will depend on patient's PS, spine stability, location in relationship to spinal cord, primary histology, presence of epidural disease, and overall treatment intent (pain relief, long-term local control, or cure). Generally, conventional external beam radiation doses of 8 Gy/1 fx, 20 Gy/5 fx, or 30 Gy/10 fx can be used. It is critical to consider tolerance at the spine and/or nerve root. In selected cases, or recurrences after previous radiation, stereotactic body radiotherapy (SBRT) is appropriate. It is critical to consider tolerance of the spine and/or spinal nerve roots. In patients with uncomplicated spine metastases that are treated primarily for pain relief, 8 Gy in 1 fraction has been shown to provide equivalent pain control to longer fractionation schedules and is more convenient for patients, but may be associated with higher rates of retreatment, which may be a consideration when life expectancy exceeds 6 months. When lower BED regimens are utilized upfront (ie, BED \leq 60 Gy₂ which includes up to 20 Gy in 5 fractions but does not include 30 Gy in 10 fractions), retreatment with similar BED regimens, such as 20 Gy in 5 fractions or 8 Gy in 1 fraction, can safely be considered as early as 4 weeks from initial treatment for pain relief. In other cases, doses ranging from 15 Gy in 1 fraction to 40 Gy in 20 fractions have been utilized for tumor control, with careful consideration of tolerance of the spinal cord and/or nerve roots. In these instances, it is generally recommended that 6 months or more of time between treatments is required.
- Stereotactic radiation approaches (SRS/SBRT) for spinal cases may be preferred for patients with oligometastatic disease where tumor ablation is a goal of treatment and in tumors considered radioresistant (renal cell, melanoma, sarcoma, hepatocellular, and some colorectal and NSCLC cases). Stereotactic radiation may also be preferred in the setting of tumor recurrence after prior radiation as a strategy to limit radiation dose to the spinal cord or other critical structures. Careful adherence to consensus guidelines for radiosurgery planning and delivery is recommended.^{25, 26, 27}

Note: All recommendations are category 2A unless otherwise indicated.

Clinical Trials: NCCN believes that the best management of any patient with cancer is in a clinical trial. Participation in clinical trials is especially encouraged.

References

PRINCIPLES OF BRAIN AND SPINAL CORD TUMOR RADIATION THERAPY

REFERENCES

- ¹Karim AB, et al. A randomized trial on dose-response in radiation therapy of low-grade cerebral glioma: European Organization for Research and Treatment of Cancer (EORTC) Study 22844. *Int J Radiat Oncol Biol Phys* 1996;36:549-556.
- ²Shaw E, et al. Prospective randomized trial of low- versus high-dose radiation therapy in adults with supratentorial low-grade glioma: initial report of a North Central Cancer Treatment Group/Radiation Therapy Oncology Group/Eastern Cooperative Oncology Group study. *J Clin Oncol* 2002;20:2267-2276.
- ³van den Bent MJ, et al. Long-term efficacy of early versus delayed radiotherapy for low-grade astrocytoma and oligodendroglioma in adults: the EORTC 22845 randomised trial. *Lancet* 2005;366(9490):985-90.
- ⁴Cabrera AR, Kirkpatrick JP, Fiveash JB, et al. Radiation therapy for glioblastoma: Executive summary of an American Society for Radiation Oncology Evidence-Based Clinical Practice Guideline. *Pract Radiat Oncol* 2016;6:217-225.
- ⁵Roa W, Brasher PM, Bauman G, et al. Abbreviated course of radiation therapy in older patients with glioblastoma multiforme: a prospective randomized clinical trial. *J Clin Oncol* 2004;22:1583-1588.
- ⁶Malmström A, Grønberg BH, Marosi C, et al. Temozolomide versus standard 6-week radiotherapy versus hypofractionated radiotherapy in patients older than 60 years with glioblastoma: the Nordic randomised, phase 3 trial. *Lancet Oncol* 2012;13:916-920.
- ⁷Roa W, Kepka L, Kumar N, et al. International Atomic Energy Agency Randomized Phase III Study of Radiation Therapy in Elderly and/or Frail Patients With Newly Diagnosed Glioblastoma Multiforme. *J Clin Oncol* 2015;33:4145-4150.
- ⁸Emami B, Lyman J, Brown A, et al. Tolerance of normal tissue to therapeutic irradiation. *Int J Radiat Oncol Biol Phys* 1991;21:109-122.
- ⁹Pieters RS, Niemierko A, Fullerton BC, Munzenrider JE. Cauda equina tolerance to high-dose fractionated irradiation. *Int J Radiat Oncol Biol Phys* 2006;64:251-257.
- ¹⁰Abdel-Wahab M, et al. Spinal cord gliomas: A multi-institutional retrospective analysis. *Int J Radiat Oncol Biol Phys*, 2006; 64:1060-1071.
- ¹¹Lee SH, et al. Long-term outcomes of surgical resection with or without adjuvant radiation therapy for treatment of spinal ependymoma: a retrospective multicenter study by the Korea Spinal Oncology Research Group. *Neuro Oncol* 2013;15:921-929.
- ¹²Brown AP, Barney CL, Grosshans DR. Proton beam craniospinal irradiation reduces acute toxicity for adults with medulloblastoma. *Int J Radiat Oncol Biol Phys* 2013;86:277-284.
- ¹³Packer RJ, Gajjar A, Vezina G, et al. Phase III study of craniospinal radiation therapy followed by adjuvant chemotherapy for newly diagnosed average-risk medulloblastoma. *J Clin Oncol* 2006;24:4202-4208.
- ¹⁴Morris PG, Correa DD, Yahalom J, et al. Rituximab, methotrexate, procarbazine, and vincristine followed by consolidation reduced-dose whole-brain radiotherapy and cytarabine in newly diagnosed primary CNS lymphoma: final results and long-term outcome. *J Clin Oncol* 2013;31:3971-3979.
- ¹⁵Thiel E, Korfel A, Martus P, et al. High-dose methotrexate with or without whole brain radiotherapy for primary CNS lymphoma (G-PCNSL-SG-1): a phase 3, randomised, non-inferiority trial. *Lancet Oncol* 2010;11:1036-1047.
- ¹⁶Shah GD, Yahalom J, Correa DD, et al. Combined immunochemotherapy with reduced whole-brain radiotherapy for newly diagnosed primary CNS lymphoma. *J Clin Oncol* 2007;30:4730-4735.
- ¹⁷Kasenda B, Loeffler J, Illerhaus G, et al. The role of whole brain radiation in primary CNS lymphoma. *Blood* 2016;1:32-36.
- ¹⁸Ghesquière H, Ferlay C, Sebban C, et al. Long-term follow-up of an age-adapted C5R protocol followed by radiotherapy in 99 newly diagnosed primary CNS lymphomas: a prospective multicentric phase II study of the Groupe d'Etude des Lymphomes de l'Adulte (GELA). *Ann Oncol* 2010;4:842-850.
- ¹⁹Andrews DW, Scott CB, Sperduto PW, et al. Whole brain radiation therapy with or without stereotactic radiosurgery boost for patients with one to three brain metastases: phase III results of the RTOG 9508 randomized trial. *Lancet* 2004;363:1665-1672.
- ²⁰Brown PD, Pugh S, Laack NN, Wefel JS, et al. Memantine for the prevention of cognitive dysfunction in patients receiving whole-brain radiotherapy: a randomized, double-blind, placebo-controlled trial. *Neuro Oncol* 2013;15:1429-37.
- ²¹Shaw E, Scott C, Souhami L, et al. Single dose radiosurgical treatment of recurrent previously irradiated primary brain tumors and brain metastases: final report of RTOG protocol 90-05. *J Radiat Oncol Biol Phys* 2000;47:291-298.
- ²²Aoyama H, Shirato H, Tago M, et al. Stereotactic radiosurgery plus whole-brain radiation therapy vs stereotactic radiosurgery alone for treatment of brain metastases: A randomized controlled trial. *JAMA* 2006;295:2483-2491.
- ²³Chang WS, Kim HY, Chang JW, et al. Analysis of radiosurgical results in patients with brain metastases according to the number of brain lesions: is stereotactic radiosurgery effective for multiple brain metastases? *J Neurosurg* 2010;113 Suppl:73-78.
- ²⁴Yamamoto M, Serizawa T, Shuto T, et al. Stereotactic radiosurgery for patients with multiple brain metastases (JLKG0901): a multi-institutional prospective observational study. *Lancet Oncol* 2014;15:387-395.
- ²⁵Cox BW, Spratt DE, Lovelock M, et al. International Spine Radiosurgery Consortium consensus guidelines for target volume definition in spinal stereotactic radiosurgery. *Int J Radiat Oncol Biol Phys* 2012;83:e597-605.
- ²⁶Redmond KJ, Lo SS, Soltys SG, et al. Consensus guidelines for postoperative stereotactic body radiation therapy for spinal metastases: results of an international survey. *J Neurosurg Spine* 2017;26:299-306.
- ²⁷Redmond KJ, Robertson S, Lo SS, et al. Consensus Contouring Guidelines for Postoperative Stereotactic Body Radiation Therapy for Metastatic Solid Tumor Malignancies to the Spine. *Int J Radiat Oncol Biol Phys* 2017;97:64-74.

Note: All recommendations are category 2A unless otherwise indicated.

Clinical Trials: NCCN believes that the best management of any patient with cancer is in a clinical trial. Participation in clinical trials is especially encouraged.

**PRINCIPLES OF BRAIN AND SPINAL CORD TUMOR SYSTEMIC THERAPY****Consider Clinical Trial (Preferred for Eligible Patients)****Adult Low-Grade Infiltrative Supratentorial Astrocytoma/
Oligodendroglioma (excluding pilocytic astrocytoma)**

- **Adjuvant Treatment: For low-risk patients:**
 - ▶ PCV (procarbazine + lomustine + vincristine)¹
 - ▶ Temozolomide²⁻⁴
- **Adjuvant Treatment: For high-risk patients:**
 - ▶ RT + adjuvant PCV (category 1)
 - ▶ RT + adjuvant temozolomide²⁻⁴ (category 2B)
 - ▶ RT + concurrent and adjuvant temozolomide (category 2B)
- **Recurrence or Progressive, Low-Grade Disease:**
 - ▶ RT + adjuvant PCV
 - ▶ RT + adjuvant temozolomide
 - ▶ RT+ concurrent and adjuvant temozolomide
 - ▶ Temozolomide^{3-5,a}
 - ▶ Lomustine or carmustine
 - ▶ PCV⁶
 - ▶ Platinum-based regimens^{7-9,g}

^aFor patients not previously treated.

^bThe panel recommends that PCV be administered after RT (as per EORTC 26951) since the intensive PCV regimen given prior to RT (RTOG 9402) was not tolerated as well.

^cThe WHO 2016 classification of CNS tumors has deleted oligoastrocytoma as a diagnostic category; however, oligoastrocytoma NOS and anaplastic oligoastrocytoma NOS may continue to be used for tumors that cannot be classified as either astrocytoma or oligodendroglioma due to the absence of appropriate molecular testing.

Anaplastic Gliomas

- **Adjuvant Treatment**
 - ▶ **Anaplastic oligodendroglioma (1p19q co-deleted) (KPS ≥60)**
 - ◇ RT with neoadjuvant PCV^{10,b}
 - ◇ RT with adjuvant PCV^{11,b}
 - ◇ RT with concurrent TMZ and adjuvant TMZ
 - ▶ **Anaplastic astrocytoma/anaplastic oligoastrocytoma, NOS^c (KPS ≥60)**
 - ◇ RT followed by adjuvant TMZ (12 cycles)¹²
 - ◇ RT with concurrent TMZ and adjuvant TMZ
 - ◇ RT with neoadjuvant PCV^b
 - ◇ RT with adjuvant PCV^b
 - ▶ **Anaplastic gliomas (KPS <60):**
 - ◇ Temozolomide (category 2B)
- **Recurrence Therapy^d**
 - ▶ Temozolomide^{4,5,13,14}
 - ▶ Lomustine or carmustine¹⁵
 - ▶ PCV
 - ▶ Bevacizumab^{16-18,e}
 - ▶ Bevacizumab + chemotherapy^f (irinotecan,^{19,20} carmustine/lomustine,²¹ temozolomide, carboplatin [category 2B for carboplatin]^{22,23})
 - ▶ Irinotecan^{24,25}
 - ▶ Cyclophosphamide (category 2B)^{26,27}
 - ▶ Platinum-based regimens⁹
 - ▶ Etoposide²⁸

^dStrongly suggest consideration of clinical trials prior to treating recurrent disease with standard chemotherapy, as additional therapies may eliminate the majority of clinical trial options.

^ePatients who have good performance status but evidence of radiographic progression may benefit from continuation of bevacizumab to prevent rapid neurologic deterioration.

^fBevacizumab + chemotherapy can be considered if bevacizumab monotherapy fails.

^gPlatinum-based regimens include cisplatin or carboplatin.

Note: All recommendations are category 2A unless otherwise indicated.

Clinical Trials: NCCN believes that the best management of any patient with cancer is in a clinical trial. Participation in clinical trials is especially encouraged.

[Continued](#)
[References](#)

BRAIN-D
1 OF 8

**PRINCIPLES OF BRAIN AND SPINAL CORD TUMOR SYSTEMIC THERAPY****Consider Clinical Trial (Preferred for Eligible Patients)****Glioblastoma****• Adjuvant Treatment:**

- ▶ Concurrent (with RT) temozolomide²⁹ 75 mg/m² daily
- ▶ Post RT temozolomide²⁹ 150–200 mg/m² 5/28 schedule
- ▶ Temozolomide^{29,30} 150–200 mg/m² 5/28 schedule

• Recurrence Therapy^d

- ▶ Bevacizumab^{31-34,e}
- ▶ Bevacizumab + chemotherapy^f
(irinotecan,³²⁻³⁴ carmustine/lomustine,²¹ temozolomide, carboplatin
[category 2B for carboplatin])
- ▶ Temozolomide^{5,29,35}
- ▶ Lomustine or carmustine¹⁵
- ▶ PCV
- ▶ Cyclophosphamide (category 2B)²⁶
- ▶ Platinum-based regimens^g

Adult Intracranial and Spinal Ependymoma (excluding subependymoma)**• Recurrence**

- ▶ Platinum-based regimens:^g Single agent or combination³⁶
- ▶ Etoposide
- ▶ Lomustine or carmustine³⁶
- ▶ Bevacizumab^e
- ▶ Temozolomide³⁷

^dStrongly suggest consideration of clinical trials prior to treating recurrent disease with standard chemotherapy, as additional therapies may eliminate the majority of clinical trial options.

^ePatients who have good performance status but evidence of radiographic progression may benefit from continuation of bevacizumab to prevent rapid neurologic deterioration.

^fBevacizumab + chemotherapy can be considered if bevacizumab monotherapy fails.

Adult Medulloblastoma**• Weekly vincristine^h during craniospinal radiation therapy followed by either of the following regimens:**

- ◊ Cisplatin, cyclophosphamide, and vincristine^{38,h}
- ◊ Cisplatin, lomustine, and vincristine^{36,h}

• Recurrence Therapy**▶ No prior chemotherapy**

- ◊ High-dose cyclophosphamide ± etoposide
- ◊ Carboplatin, etoposide, and cyclophosphamide
- ◊ Cisplatin, etoposide, and cyclophosphamide
- ◊ Consider high-dose chemotherapy with autologous stem cell reinfusion³⁹ in patients who achieve a CR with conventional doses of chemotherapy or have no residual disease after re-resection

▶ Prior Chemotherapy

- ◊ High-dose cyclophosphamide ± etoposide
- ◊ Oral etoposide^{40,41}
- ◊ Temozolomide⁴²
- ◊ Consider high-dose chemotherapy with autologous stem cell reinfusion³⁹ in patients who achieve a CR with conventional doses of chemotherapy or have no residual disease after re-resection

Meningiomas

- Interferon alfa (category 2B)⁴³
- Somatostatin analogue, if octreotide scan positive⁴⁴
- Sunitinib (category 2B)⁴⁵
- Bevacizumab + everolimus⁴⁶ (category 2B)

^gPlatinum-based regimens include cisplatin or carboplatin.

^hOmission of vincristine during radiotherapy phase of therapy or dose modification may be required for adults because they do not tolerate this regimen as well. Data supporting vincristine's use have been found in pediatric trials only. Patients should be closely monitored for neurologic toxicity with periodic exams.

Note: All recommendations are category 2A unless otherwise indicated.

Clinical Trials: NCCN believes that the best management of any patient with cancer is in a clinical trial. Participation in clinical trials is especially encouraged.

[Continued](#)
[References](#)

BRAIN-D
2 OF 8

PRINCIPLES OF BRAIN AND SPINAL CORD TUMOR SYSTEMIC THERAPY

Consider Clinical Trial (Preferred for Eligible Patients)

Primary CNS Lymphoma

• Induction Therapy

▶ Systemic therapy

◊ High-dose methotrexate 8 g/m² combined with the following:^{47,i}

– Rituximab^{48-51,j}

– Rituximab and temozolomide^{52,j}

◊ High-dose methotrexate 3.5 g/m² combined with the following, and consider WBRT:^{k,i}

– Vincristine, procarbazine, and rituximab (R-MPV)⁵³⁻⁵⁶

– Temozolomide + rituximab followed by post-RT temozolomide⁵⁷

▶ Intra-CSF Therapy

◊ Methotrexate

◊ Cytarabine

◊ Rituximab⁵⁸

• Consolidation Therapy

▶ High-dose chemotherapy with stem cell rescue

◊ Carmustine + thiotepa^{59,60}

◊ Thiotepa, busulfan, and cyclophosphamide (TBC)^{56,61}

▶ High-dose cytarabine ± etoposide (EA)⁶²

▶ High-dose cytarabine⁵³⁻⁵⁵

• Relapsed or Refractory Disease

▶ Retreat with high-dose methotrexate with or without rituximab^{47,i}

▶ Ibrutinib^{63,l}

▶ Temozolomide

▶ Rituximab ± temozolomide⁶⁴

▶ Lenalidomide with or without rituximab⁶⁵

▶ Topotecan

▶ Consider high-dose chemotherapy with autologous stem cell reinfusion in eligible patients^{59,66,67}

▶ High-dose cytarabine⁶⁸

▶ Dexamethasone, high-dose cytarabine, cisplatin⁶⁹

▶ Pemetrexed⁷⁰

ⁱConsider glucarpidase (carboxypeptidase G2) for prolonged methotrexate clearance due to methotrexate-induced renal toxicity.⁴⁹

^jHepatitis B testing is indicated because of the risk of reactivation with immunotherapy + chemotherapy. Tests include hepatitis B surface antigen and core antibody for a patient with no risk factors. For patients with risk factors or previous history of hepatitis B, add e-antigen. If positive, check viral load and consult with gastroenterologist. [See NCCN Guidelines for B-Cell Lymphomas](#) (NHODG-B, 2 of 3) also has information about HPV testing for patients considering rituximab.

^kOther combinations with methotrexate may be used.

^lIbrutinib is associated with risk of aspergillus infection.

Note: All recommendations are category 2A unless otherwise indicated.

Clinical Trials: NCCN believes that the best management of any patient with cancer is in a clinical trial. Participation in clinical trials is especially encouraged.

[Continued](#)
[References](#)

BRAIN-D
3 OF 8

PRINCIPLES OF BRAIN AND SPINAL CORD TUMOR SYSTEMIC THERAPY

Consider Clinical Trial (Preferred for Eligible Patients)

Brain Metastases

- **Newly Diagnosed^m**
 - ▶ **BRAF/MEK inhibitor combination (melanoma):**
 - ◊ **Vemurafenib⁷¹/cobimetinib (category 2B)**
 - ◊ **Dabrafenib⁷²⁻⁷⁴/trametinib⁷⁵**
 - ▶ **Ipilimumab + nivolumab (melanoma)^{76,77}**
 - ▶ **Pembrolizumab (melanoma or non-small cell lung cancer)⁷⁸**
 - ▶ **Alectinib (ALK rearrangement-positive NSCLC)⁷⁹**
- **Recurrent Diseaseⁿ**
 - ▶ **Treatment as per the regimens of the primary tumor**
 - ▶ **Carmustine wafer⁸⁰**
 - ▶ **Temozolomide 5/28 schedule**
 - ▶ **High-dose methotrexate^{81,82} (breast and lymphoma)**
 - ▶ **Capecitabine ± lapatinib,^{83,84} cisplatin,^{85,86} etoposide^{85,86} (breast)⁸⁷⁻⁹¹**
 - ▶ **Capecitabine + neratinib (breast)⁹²**
 - ▶ **Paclitaxel + neratinib (breast)^{93,94} (category 2B)**
 - ▶ **Topotecan (small cell lung)**
 - ▶ **Ipilimumab (melanoma)⁹⁵**
 - ▶ **Ipilimumab + nivolumab (melanoma)^{76,77}**
 - ▶ **Pembrolizumab (melanoma or non-small cell lung cancer)⁷⁸**
 - ▶ **BRAF/MEK inhibitor combination therapy (melanoma):**
 - ◊ **Vemurafenib^{71,96}/cobimetinib^o**
 - ◊ **Dabrafenib⁷²⁻⁷⁴/trametinib⁷⁵**
 - ▶ **Ceritinib, alectinib,⁹⁷ brigatinib⁹⁸ (ALK rearrangement-positive NSCLC)**
 - ▶ **Erlotinib, afatinib, gefitinib (EGFR-sensitizing mutation-positive non-small cell lung cancer)**
 - ▶ **Osimertinib (EGFR T790M mutation-positive non-small cell lung cancer)^{99,100}**
 - ▶ **Crizotinib (ALK rearrangement-positive or ROS1 rearrangement-positive non-small cell lung cancer)**

ⁱConsider glucarpidase (carboxypeptidase G2) for prolonged methotrexate clearance due to methotrexate-induced renal toxicity.⁴⁹

^mFor patients with asymptomatic brain metastases, it is reasonable to treat with these systemic therapies in lieu of upfront WBRT or SRS.

ⁿUse agents active against primary tumor.

Leptomeningeal Metastases

- **Treatment**
 - ▶ **Systemic therapy specific to primary cancer type; emphasizing drugs with good CNS penetration**
 - ▶ **Intra-CSF chemotherapy¹⁰¹**
 - ◊ **Cytarabine (lymphoma/leukemias)^{102,103}**
 - ◊ **Methotrexate (lymphoma/leukemias, breast)**
 - ◊ **Thiotepa**
 - ◊ **Rituximab (lymphoma)¹⁰³**
 - ◊ **Topotecan¹⁰⁴**
 - ◊ **Etoposide¹⁰⁵**
 - ◊ **Interferon alfa (category 2B)¹⁰⁶**
 - ◊ **Trastuzumab (breast)¹⁰⁷**
 - ▶ **High-dose methotrexate for lymphoma and breast^{108,i}**
 - ▶ **Weekly pulse erlotinib for EGFR exon 19 deletion or exon 21 L858R mutation (non-small cell lung cancer) (category 2B)¹⁰⁹**

Metastatic Spine Tumors

- **Use regimen for disease-specific site**

^oAlthough there are no published prospective studies on the combination of vemurafenib and cobimetinib for melanoma patients with brain metastases, there is high-quality evidence that for melanoma with distant metastasis, combination therapy with vemurafenib and cobimetinib is associated with improved outcomes and safety compared with single-agent vemurafenib.

Note: All recommendations are category 2A unless otherwise indicated.

Clinical Trials: NCCN believes that the best management of any patient with cancer is in a clinical trial. Participation in clinical trials is especially encouraged.

[References](#)

PRINCIPLES OF BRAIN AND SPINAL CORD TUMOR SYSTEMIC THERAPY
REFERENCES

- ¹Shaw EG, Wang M, Coons SW, et al. Randomized trial of radiation therapy plus procarbazine, lomustine, and vincristine chemotherapy for supratentorial adult low-grade glioma: initial results of RTOG 9802. *J Clin Oncol* 2012;30:3065-3070.
- ²Pouratian N, Gasco J, Sherman JH, et al. Toxicity and efficacy of protracted low dose temozolomide for the treatment of low grade gliomas. *J Neurooncol* 2007;82:281-288.
- ³Kesari S, Schiff D, Drappatz J, et al. Phase II study of protracted daily temozolomide for low-grade gliomas in adults. *Clin Cancer Res* 2009;15:330-337.
- ⁴Nicholson HS, Kretschmar CS, Krailo M, et al. Phase 2 study of temozolomide in children and adolescents with recurrent central nervous system tumors: a report from the Children's Oncology Group. *Cancer* 2007;110:1542-1550.
- ⁵Perry JR, Rizek P, Cashman R, et al. Temozolomide rechallenge in recurrent malignant glioma by using a continuous temozolomide schedule: the "rescue" approach. *Cancer* 2008;113:2152-2157.
- ⁶Triebels VH, Taphoorn MJ, Brandes AA, et al. Salvage PCV chemotherapy for temozolomide-resistant oligodendrogliomas. *Neurology* 2004;63:904-906.
- ⁷Massimino M, Spreafico F, Riva D, et al. A lower-dose, lower-toxicity cisplatin-etoposide regimen for childhood progressive low-grade glioma. *J Neurooncol* 2010.
- ⁸Moghrabi A, Friedman HS, Ashley DM, et al. Phase II study of carboplatin (CBDCA) in progressive low-grade gliomas. *Neurosurg Focus* 1998;4:e3.
- ⁹Brandes AA, Basso U, Vastola F, et al. Carboplatin and teniposide as third-line chemotherapy in patients with recurrent oligodendroglioma or oligoastrocytoma: a phase II study. *Ann Oncol* 2003;14:1727-1731.
- ¹⁰Cairncross G, Wang M, Shaw E, et al. Phase III Trial of Chemoradiotherapy for Anaplastic Oligodendroglioma: Long-Term Results of RTOG 9402. *J Clin Oncol* 2013;31:337-343.
- ¹¹van den Bent MJ, Brandes AA, Taphoorn MJ. Adjuvant Procarbazine, Lomustine, and Vincristine Chemotherapy in Newly Diagnosed Anaplastic Oligodendroglioma: Long-Term Follow-Up of EORTC Brain Tumor Group Study 26951. *J Clin Oncol* 2013;31:344-350.
- ¹²van den Bent MJ, Baumert B, Erridge SC, et al. Interim results from the CATNON trial (EORTC study 26053-22054) of treatment with concurrent and adjuvant temozolomide for 1p/19q non-co-deleted anaplastic glioma: a phase 3, randomised, open-label intergroup study. *Lancet* 2017;390:1645-1653.
- ¹³Yung WK, Prados MD, Yaya-Tur R, et al. Multicenter phase II trial of temozolomide in patients with anaplastic astrocytoma or anaplastic oligoastrocytoma at first relapse. Temodal Brain Tumor Group. *J Clin Oncol* 1999;17:2762-2771.
- ¹⁴Perry JR, Belanger K, Mason WP, et al. Phase II trial of continuous dose-intense temozolomide in recurrent malignant glioma: RESCUE study. *J Clin Oncol* 2010;28:2051-2057.
- ¹⁵Wick W, Puduvalli VK, Chamberlain MC, et al. Phase III Study of Enzastaurin Compared with lomustine in the treatment of recurrent intracranial glioblastoma. *J Clin Oncol* 2010;28:1168-1174.
- ¹⁶Norden AD, Young GS, Setayesh K, et al. Bevacizumab for recurrent malignant gliomas: efficacy, toxicity, and patterns of recurrence. *Neurology* 2008;70:779-787.
- ¹⁷Chamberlain MC, Johnston S. Bevacizumab for recurrent alkylator-refractory anaplastic oligodendroglioma. *Cancer* 2009;115:1734-1743.
- ¹⁸Chamberlain MC, Johnston S. Salvage chemotherapy with bevacizumab for recurrent alkylator-refractory anaplastic astrocytoma. *J Neurooncol* 2009;91:359-367.
- ¹⁹Taillibert S, Vincent LA, Granger B, et al. Bevacizumab and irinotecan for recurrent oligodendroglial tumors. *Neurology* 2009;72:1601-1606.
- ²⁰Vredenburg JJ, Desjardins A, Herndon JE, 2nd, et al. Phase II trial of bevacizumab and irinotecan in recurrent malignant glioma. *Clin Cancer Res* 2007;13:1253-1259.
- ²¹Soffietti R, Ruda R, Trevisan E, et al. Phase II study of bevacizumab and nitrosourea in patients with recurrent malignant glioma: A multicenter Italian study [abstract]. *J Clin Oncol* 2009;27(Suppl 15S):2012.
- ²²Mrugala MM, Crew LK, Fink JR, et al. Carboplatin and bevacizumab for recurrent malignant glioma. *Oncol Lett* 2012;4:1082-1086.
- ²³Thompson EM, Dosa E, Kraemer DF, Neuwelt EA. Treatment with bevacizumab plus carboplatin for recurrent malignant glioma. *Neurosurgery* 2010;67:87-93.
- ²⁴Chamberlain MC, Wei-Tsao DD, Blumenthal DT, et al. Salvage chemotherapy with CPT-11 for recurrent temozolomide-refractory anaplastic astrocytoma. *Cancer* 2008;112:2038-2045.
- ²⁵Chamberlain MC. Salvage chemotherapy with CPT-11 for recurrent oligodendrogliomas. *J Neurooncol* 2002;59:157-163.
- ²⁶Chamberlain MC, Tsao-Wei DD. Salvage chemotherapy with cyclophosphamide for recurrent, temozolomide-refractory glioblastoma multiforme. *Cancer* 2004;100:1213-1220.
- ²⁷Chamberlain MC, Tsao-Wei DD, Groshen S. Salvage chemotherapy with cyclophosphamide for recurrent temozolomide-refractory anaplastic astrocytoma. *Cancer* 2006;106:172-179.
- ²⁸Fulton D, Urtasun R, Forsyth P. Phase II study of prolonged oral therapy with etoposide (VP16) for patients with recurrent malignant glioma. *J Neurooncol* 1996;27:149-155.
- ²⁹Stupp R, Mason WP, van den Bent MJ, et al. Radiotherapy plus concomitant and adjuvant temozolomide for glioblastoma. *N Engl J Med* 2005;352:987-996.
- ³⁰Malmstrom A, Gronberg BH, Marosi C, et al. Temozolomide versus standard 6-week radiotherapy versus hypofractionated radiotherapy in patients older than 60 years with glioblastoma: the Nordic randomised, phase 3 trial. *Lancet Oncol* 2012;13:916-926.
- ³¹Cloughesy TF, Prados MD, Wen PY, et al. A phase II, randomized, non-comparative clinical trial of the effect of bevacizumab (BV) alone or in combination with irinotecan (CPT) on 6-month progression free survival (PFS6) in recurrent, treatment-refractory glioblastoma (GBM) (abstract). *Journal of Clinical Oncology* 2008;26:Abstr 2010b.
- ³²Friedman HS, Prados MD, Wen PY, et al. Bevacizumab alone and in combination with irinotecan in recurrent glioblastoma. *J Clin Oncol* 2009;27:4733-4740.

[Continued](#)**Note: All recommendations are category 2A unless otherwise indicated.****Clinical Trials: NCCN believes that the best management of any patient with cancer is in a clinical trial. Participation in clinical trials is especially encouraged.**

NCCN Guidelines Version 2.2018

Central Nervous System Cancers

PRINCIPLES OF BRAIN AND SPINAL CORD TUMOR SYSTEMIC THERAPY

REFERENCES

- ³³Kreisl TN, Kim L, Moore K, et al. Phase II trial of single-agent bevacizumab followed by bevacizumab plus irinotecan at tumor progression in recurrent glioblastoma. *J Clin Oncol* 2009;27:740-745.
- ³⁴Vredenburgh JJ, Desjardins A, Herndon JE, 2nd, et al. Bevacizumab plus irinotecan in recurrent glioblastoma multiforme. *J Clin Oncol* 2007;25:4722-4729.
- ³⁵Yung WK, Albright RE, Olson J, et al. A phase II study of temozolomide vs. procarbazine in patients with glioblastoma multiforme at first relapse. *Br J Cancer* 2000;83:588-593.
- ³⁶Gornet MK, Buckner JC, Marks RS, et al. Chemotherapy for advanced CNS ependymoma. *J Neurooncol* 1999;45:61-67.
- ³⁷Ruda R, Bosa C, Magistrello M, et al. Temozolomide as salvage treatment for recurrent intracranial ependymomas of the adult: a retrospective study. *Neuro Oncol* 2016;18:261-268.
- ³⁸Packer RJ, Gajjar A, Vezina G, et al. Phase III study of craniospinal radiation therapy followed by adjuvant chemotherapy for newly diagnosed average-risk medulloblastoma. *J Clin Oncol* 2006;24:4202-4208.
- ³⁹Dunkel IJ, Gardner SL, Garvin JH, Jr., et al. High-dose carboplatin, thiotepa, and etoposide with autologous stem cell rescue for patients with previously irradiated recurrent medulloblastoma. *Neuro Oncol* 2010;12:297-303.
- ⁴⁰Ashley DM, Meier L, Kerby T, et al. Response of recurrent medulloblastoma to low-dose oral etoposide. *J Clin Oncol* 1996;14:1922-1927.
- ⁴¹Chamberlain MC, Kormanik PA. Chronic oral VP-16 for recurrent medulloblastoma. *Pediatr Neurol* 1997;17:230-234.
- ⁴²Nicholson HS, Kretschmar CS, Krailo M, et al. Phase 2 study of temozolomide in children and adolescents with recurrent central nervous system tumors: a report from the Children's Oncology Group. *Cancer* 2007;110:1542-1550.
- ⁴³Chamberlain MC, Glantz MJ. Interferon-alpha for recurrent World Health Organization grade 1 intracranial meningiomas. *Cancer* 2008;113:2146-2151.
- ⁴⁴Chamberlain MC, Glantz MJ, Fadul CE. Recurrent meningioma: salvage therapy with long-acting somatostatin analogue. *Neurology* 2007;69:969-973.
- ⁴⁵Kaley TJ, Wen P, Schiff D, et al. Phase II trial of sunitinib for recurrent and progressive atypical and anaplastic meningioma. *Neuro Oncol* 2015;17:116-121.
- ⁴⁶Shih KC, Chowdhary S, Rosenblatt P, et al. A phase II trial of bevacizumab and everolimus as treatment for patients with refractory, progressive intracranial meningioma. *J Neurooncol* 2016;129:281-288.
- ⁴⁷Batchelor T, Carson K, O'Neill A, et al. Treatment of primary CNS lymphoma with methotrexate and deferred radiotherapy: a report of NABTT 96-07. *J Clin Oncol* 2003;21:1044-1049.
- ⁴⁸Chamberlain MC, Johnston SK. High-dose methotrexate and rituximab with deferred radiotherapy for newly diagnosed primary B-cell CNS lymphoma. *Neuro Oncol* 2010;12:736-744.
- ⁴⁹Gregory G, Arumugaswamy A, Leung T, et al. Rituximab is associated with improved survival for aggressive B cell CNS lymphoma. *Neuro Oncol* 2013;15:1068-1073.
- ⁵⁰Holdhoff M, Ambady P, Abdelaziz A, et al. High-dose methotrexate with or without rituximab in newly diagnosed primary CNS lymphoma. *Neurology* 2014;83:235-239.
- ⁵¹Ly KI, Crew LL, Graham CA, Mrugala MM. Primary central nervous system lymphoma treated with high-dose methotrexate and rituximab: A single-institution experience. *Oncol Lett* 2016;11:3471-3476.
- ⁵²Wieduwilt MJ, Valles F, Issa S, et al. Immunochemotherapy with intensive consolidation for primary CNS lymphoma: a pilot study and prognostic assessment by diffusion-weighted MRI. *Clin Cancer Res* 2012;18:1146-1155.
- ⁵³DeAngelis LM, Seiferheld W, Schold SC, et al. Combination chemotherapy and radiotherapy for primary central nervous system lymphoma: Radiation Therapy Oncology Group Study 93-10. *J Clin Oncol* 2002;20:4643-4648.
- ⁵⁴Shah GD, Yahalom J, Correa DD, et al. Combined immunochemotherapy with reduced whole-brain radiotherapy for newly diagnosed primary CNS lymphoma. *J Clin Oncol* 2007;25:4730-4735. Erratum in: *J Clin Oncol* 2008;26:340.
- ⁵⁵Gavrilovic IT, Hormigo A, Yahalom J, et al. Long-term follow-up of high-dose methotrexate-based therapy with and without whole brain irradiation for newly diagnosed primary CNS lymphoma. *J Clin Oncol* 2006;24:4570-4574.
- ⁵⁶Omuro A, Correa DD, DeAngelis LM, et al. R-MPV followed by high-dose chemotherapy with TBC and autologous stem-cell transplant for newly diagnosed primary CNS lymphoma. *Blood* 2015;125:1403-1410.
- ⁵⁷Glass J, Won M, Schultz CJ, et al. Phase I and II Study of Induction Chemotherapy With Methotrexate, Rituximab, and Temozolomide, Followed By Whole-Brain Radiotherapy and Postirradiation Temozolomide for Primary CNS Lymphoma: NRG Oncology RTOG 0227. *J Clin Oncol* 2016;34:1620-1625.
- ⁵⁸Schulz H, Pels H, Schmidt-Wolf I, et al. Intraventricular treatment of relapsed central nervous system lymphoma with the anti-CD20 antibody rituximab. *Haematologica* 2004;89:753-754.
- ⁵⁹Illerhaus G, Muller F, Feuerhake F, et al. High-dose chemotherapy and autologous stem-cell transplantation without consolidating radiotherapy as first-line treatment for primary lymphoma of the central nervous system. *Haematologica* 2008;93:147-148.
- ⁶⁰Kasenda B, Schorb E, Fritsch K, et al. Prognosis after high-dose chemotherapy followed by autologous stem-cell transplantation as first-line treatment in primary CNS lymphoma—a long-term follow-up study. *Ann Oncol* 2012;23:2670-2675.
- ⁶¹DeFilipp Z, Li S, El-Jawahri A, et al. High-dose chemotherapy with thiotepa, busulfan, and cyclophosphamide and autologous stem cell transplantation for patients with primary central nervous system lymphoma in first complete remission. *Cancer* 2017;123:3073-3079.

[Continued](#)**Note:** All recommendations are category 2A unless otherwise indicated.**Clinical Trials:** NCCN believes that the best management of any patient with cancer is in a clinical trial. Participation in clinical trials is especially encouraged.

PRINCIPLES OF BRAIN AND SPINAL CORD TUMOR SYSTEMIC THERAPY

REFERENCES

- ⁶²Rubenstein JL, Hsi ED, Johnson JL, et al. Intensive chemotherapy and immunotherapy in patients with newly diagnosed primary CNS lymphoma: CALGB 50202 (Alliance 50202). *J Clin Oncol* 2013;31:3061-3068.
- ⁶³Grommes C, Pastore A, Palaskas N, et al. Ibrutinib Unmasks Critical Role of Bruton Tyrosine Kinase in Primary CNS Lymphoma. *Cancer Discov* 2017;7:1018-1029.
- ⁶⁴Enting RH, Demopoulos A, DeAngelis LM, Abrey LE. Salvage therapy for primary CNS lymphoma with a combination of rituximab and temozolomide. *Neurology* 2004;63:901-903.
- ⁶⁵Rubenstein JL, Fraser E, Formaker P, et al. Phase I investigation of lenalidomide plus rituximab and outcomes of lenalidomide maintenance in recurrent CNS lymphoma (abstract). *Journal of Clinical Oncology* 2016;34:Abstr 7502.
- ⁶⁶Soussain C, Hoang-Xuan K, Taillandier L, et al. Intensive chemotherapy followed by hematopoietic stem-cell rescue for refractory and recurrent primary CNS and intraocular lymphoma: Societe Francaise de Greffe de Moelle Osseuse-Therapie Cellulaire. *J Clin Oncol* 2008;26:2512-2518.
- ⁶⁷Kasenda B, Ihorst G, Schroers R, et al. High-dose chemotherapy with autologous haematopoietic stem cell support for relapsed or refractory primary CNS lymphoma: a prospective multicentre trial by the German Cooperative PCNSL study group. *Leukemia* 2017;31:2623-2629.
- ⁶⁸DeAngelis LM, Kreis W, Chan K, et al. Pharmacokinetics of ara-C and ara-U in plasma and CSF after high-dose administration of cytosine arabinoside. *Cancer Chemother Pharmacol* 1992;29:173-177.
- ⁶⁹McLaughlin P, Velasquez WS, Redman JR, et al. Chemotherapy with dexamethasone, high-dose cytarabine, and cisplatin for parenchymal brain lymphoma. *J Natl Cancer Inst* 1988;80:1408-1412.
- ⁷⁰Raizer JJ, Rademaker A, Evens AM, et al. Pemetrexed in the treatment of relapsed/refractory primary central nervous system lymphoma. *Cancer* 2012;118:3743-3748.
- ⁷¹McArthur GA, Maio M, Arance A, et al. Vemurafenib in metastatic melanoma patients with brain metastases: an open-label, single-arm, phase 2, multicentre study. *Ann Oncol* 2017;28:634-641.
- ⁷²Long GV, Trefzer U, Davies MA, et al. Dabrafenib in patients with Val600Glu or Val600Lys BRAF-mutant melanoma metastatic to the brain (BREAK-MB): a multicentre, open-label, phase 2 trial. *Lancet Oncol* 2012;13:1087-1095.
- ⁷³Falchook GS, Long GV, Kurzrock R, et al. Dabrafenib in patients with melanoma, untreated brain metastases, and other solid tumours: a phase 1 dose-escalation trial. *Lancet* 2012;379:1893-1901.
- ⁷⁴Azer MW, Menzies AM, Haydu LE, et al. Patterns of response and progression in patients with BRAF-mutant melanoma metastatic to the brain who were treated with dabrafenib. *Cancer* 2014;120:530-536.
- ⁷⁵Davies MA, Saiag P, Robert C, et al. Dabrafenib plus trametinib in patients with BRAFV600-mutant melanoma brain metastases (COMBI-MB): a multicentre, multicohort, open-label, phase 2 trial. *Lancet Oncol* 2017;18:863-873.
- ⁷⁶Tawbi HA-H, Forsyth PAJ, Algazi AP, et al. Efficacy and safety of nivolumab (NIVO) plus ipilimumab (IPI) in patients with melanoma (MEL) metastatic to the brain: Results of the phase II study CheckMate 204 (abstract). *Journal of Clinical Oncology* 2017;35:Abstr 9507.
- ⁷⁷Long GV, Atkinson V, Menzies AM, et al. A randomized phase II study of nivolumab or nivolumab combined with ipilimumab in patients (pts) with melanoma brain metastases (mets): The Anti-PD1 Brain Collaboration (ABC) (abstract). *Journal of Clinical Oncology* 2017;35:Abstr 9508.
- ⁷⁸Goldberg SB, Gettinger SN, Mahajan A, et al. Pembrolizumab for patients with melanoma or non-small-cell lung cancer and untreated brain metastases: early analysis of a non-randomised, open-label, phase 2 trial. *Lancet Oncol* 2016;17:976-983.
- ⁷⁹Peters S, Camidge DR, Shaw AT, et al. Alectinib versus Crizotinib in Untreated ALK-Positive Non-Small-Cell Lung Cancer. *N Engl J Med* 2017;377:829-838.
- ⁸⁰Ewend MG, Brem S, Gilbert M, et al. Treatment of single brain metastasis with resection, intracavity carmustine polymer wafers, and radiation therapy is safe and provides excellent local control. *Clin Cancer Res* 2007;13:3637-3641.
- ⁸¹Lassman AB, Abrey LE, Shah GD, et al. Systemic high-dose intravenous methotrexate for central nervous system metastases. *J Neurooncol* 2006;78:255-260.
- ⁸²Bokstein F, Lossos A, Lossos IS, Siegal T. Central nervous system relapse of systemic non-Hodgkin's lymphoma: results of treatment based on high-dose methotrexate combination chemotherapy. *Leuk Lymphoma* 2002;43:587-593.
- ⁸³Metro G, Foglietta J, Russillo M, et al. Clinical outcome of patients with brain metastases from HER2-positive breast cancer treated with lapatinib and capecitabine. *Ann Oncol* 2011;22:625-630.
- ⁸⁴Sutherland S, Ashley S, Miles D, et al. Treatment of HER2-positive metastatic breast cancer with lapatinib and capecitabine in the lapatinib expanded access programme, including efficacy in brain metastases—the UK experience. *Br J Cancer* 2010;102:995-1002.
- ⁸⁵Cocconi G, Lottici R, Bisagni G, et al. Combination therapy with platinum and etoposide of brain metastases from breast carcinoma. *Cancer Invest* 1990;8:327-334.
- ⁸⁶Franciosi V, Cocconi G, Michiara M, et al. Front-line chemotherapy with cisplatin and etoposide for patients with brain metastases from breast carcinoma, nonsmall cell lung carcinoma, or malignant melanoma: a prospective study. *Cancer* 1999;85:1599-1605.
- ⁸⁷Rivera E, Meyers C, Groves M, et al. Phase I study of capecitabine in combination with temozolomide in the treatment of patients with brain metastases from breast carcinoma. *Cancer* 2006;107:1348-1354.
- ⁸⁸Fabi A, Vidiri A, Ferretti G, et al. Dramatic regression of multiple brain metastases from breast cancer with Capecitabine: another arrow at the bow? *Cancer Invest* 2006;24:466-468.

[Continued](#)

Note: All recommendations are category 2A unless otherwise indicated.

Clinical Trials: NCCN believes that the best management of any patient with cancer is in a clinical trial. Participation in clinical trials is especially encouraged.

PRINCIPLES OF BRAIN AND SPINAL CORD TUMOR SYSTEMIC THERAPY

REFERENCES

- ⁸⁹Siegelmann-Danieli N, Stein M, Bar-Ziv J. Complete response of brain metastases originating in breast cancer to capecitabine therapy. *Isr Med Assoc J* 2003;5:833-834.
- ⁹⁰Wang ML, Yung WK, Royce ME, et al. Capecitabine for 5-fluorouracil-resistant brain metastases from breast cancer. *Am J Clin Oncol* 2001;24:421-424.
- ⁹¹Hikino H, Yamada T, Johbara K, et al. Potential role of chemo-radiation with oral capecitabine in a breast cancer patient with central nervous system relapse. *Breast* 2006;15:97-99.
- ⁹²Freedman RA, Gelman RS, Melisko ME, et al. TBCRC 022: Phase II trial of neratinib + capecitabine for patients (Pts) with human epidermal growth factor receptor 2 (HER2+) breast cancer brain metastases (BCBM) (abstract). *Journal of Clinical Oncology* 2017;35:Abstr 1005.
- ⁹³Awada A, Colomer R, Bondarenko I, et al. Efficacy and CNS progression analysis from the randomized phase 2 trial of neratinib + paclitaxel vs trastuzumab + paclitaxel as first-line treatment for HER2+ metastatic breast cancer (NEfERTT) (abstract). *Journal of Clinical Oncology* 2015;33:Abstr 610.
- ⁹⁴Awada A, Colomer R, Inoue K, et al. Neratinib Plus Paclitaxel vs Trastuzumab Plus Paclitaxel in Previously Untreated Metastatic ERBB2-Positive Breast Cancer: The NEfERT-T Randomized Clinical Trial. *JAMA Oncol* 2016;2:1557-1564.
- ⁹⁵Margolin K, Ernstoff MS, Hamid O, et al. Ipilimumab in patients with melanoma and brain metastases: an open-label, phase 2 trial. *Lancet Oncol* 2012;13:459-465.
- ⁹⁶Dummer R, Goldinger SM, Turtschi CP, et al. Vemurafenib in patients with BRAF(V600) mutation-positive melanoma with symptomatic brain metastases: final results of an open-label pilot study. *Eur J Cancer* 2014;50:611-621.
- ⁹⁷Gandhi L, Ou SI, Shaw AT, et al. Efficacy of alectinib in central nervous system metastases in crizotinib-resistant ALK-positive non-small-cell lung cancer: Comparison of RECIST 1.1 and RANO-HGG criteria. *Eur J Cancer* 2017;82:27-33.
- ⁹⁸Kim DW, Tiseo M, Ahn MJ, et al. Brigatinib in Patients With Crizotinib-Refractory Anaplastic Lymphoma Kinase-Positive Non-Small-Cell Lung Cancer: A Randomized, Multicenter Phase II Trial. *J Clin Oncol* 2017;35:2490-2498.
- ⁹⁹Goss G, Tsai CM, Shepherd FA, et al. CNS response to osimertinib in patients with T790M-positive advanced NSCLC: pooled data from two Phase II trials. *Ann Oncol* 2017;mdx820-mdx820.
- ¹⁰⁰Mok TS, Wu YL, Ahn MJ, et al. Osimertinib or Platinum-Pemetrexed in EGFR T790M-Positive Lung Cancer. *N Engl J Med* 2017;376:629-640.
- ¹⁰¹Chamberlain MC. Leptomeningeal metastasis. *Curr Opin Neurol* 2009;22:665-674.
- ¹⁰²Jaecle KA, Phuphanich S, Bent MJ, et al. Intrathecal treatment of neoplastic meningitis due to breast cancer with a slow-release formulation of cytarabine. *Br J Cancer* 2001;84:157-163.
- ¹⁰³Chamberlain MC, Johnston SK, Van Horn A, Glantz MJ. Recurrent lymphomatous meningitis treated with intra-CSF rituximab and liposomal ara-C. *J Neurooncol* 2009;91:271-277.
- ¹⁰⁴Groves MD, Glantz MJ, Chamberlain MC, et al. A multicenter phase II trial of intrathecal topotecan in patients with meningeal malignancies. *Neuro Oncol* 2008;10:208-215.
- ¹⁰⁵Chamberlain MC, Tsao-Wei DD, Groshen S. Phase II trial of intracerebrospinal fluid etoposide in the treatment of neoplastic meningitis. *Cancer* 2006;106:2021-2027.
- ¹⁰⁶Chamberlain MC. A phase II trial of intra-cerebrospinal fluid alpha interferon in the treatment of neoplastic meningitis. *Cancer* 2002;94:2675-2680.
- ¹⁰⁷Zagouri F, Sergentanis TN, Bartsch R, et al. Intrathecal administration of trastuzumab for the treatment of meningeal carcinomatosis in HER2-positive metastatic breast cancer: a systematic review and pooled analysis. *Breast Cancer Res Treat* 2013;139:13-22.
- ¹⁰⁸Lassman AB, Abrey LE, Shah GD, et al. Systemic high-dose intravenous methotrexate for central nervous system metastases. *J Neurooncol* 2006;78:255-260.
- ¹⁰⁹Grommes C, Oxnard GR, Kris MG, et al. "Pulsatile" high-dose weekly erlotinib for CNS metastases from EGFR mutant non-small cell lung cancer. *Neuro Oncol* 2011;13:1364-1369.

Note: All recommendations are category 2A unless otherwise indicated.

Clinical Trials: NCCN believes that the best management of any patient with cancer is in a clinical trial. Participation in clinical trials is especially encouraged.

**PRINCIPLES OF BRAIN AND SPINE TUMOR MANAGEMENT****General**

Patients diagnosed with a tumor involving the brain, spinal cord, and related support structures should be referred to practitioners who are experienced in the diagnosis and management of these lesions.¹ The patient may (and should) be presented with options for care, which may include procedures or treatments best done by other specialists. The care options should then be discussed with the patient and their chosen supports in a manner that is understandable and culturally and educationally sensitive.

Multidisciplinary Care

- During the course of their treatment, most patients will be seen by multiple subspecialists. Close and regular communication among all providers across disciplines is essential. Utilization of brain tumor board or multidisciplinary clinic care models facilitates interactions among multiple subspecialists, ideally including allied health services (ie, physical, occupational and speech therapies, nursing, psychology, social work) for optimizing treatment plan recommendations.
- As treatment proceeds, it is important that the patient and family understand the role of each team member. One practitioner should be identified early on as the main point of contact for follow-up care questions. This individual can facilitate referral to the appropriate specialist.
- Offering patients the option of participation in a clinical trial is strongly encouraged. Practitioners should discuss any local, regional, and national options for which the patient may be eligible and the advantages and disadvantages of participation. Centers treating neuro-oncology patients are encouraged to participate in large collaborative trials in order to have local options to offer patients.
- Throughout treatment the patient's quality of life should remain the highest priority and guide clinical decision-making. While responses on imaging are benchmarks of successful therapy, other indicators of success such as overall well-being, function in day-to-day activities, social and family interactions, nutrition, pain control, long-term consequences of treatment, and psychological issues must be considered.
- Patients should be informed of the possibility of pseudoprogression, its approximate incidence, and potential investigations that may be needed in the event that pseudoprogression is suspected. Close follow-up imaging, MR spectroscopy, PET/CT imaging, and repeat surgery may be necessary if clinically indicated.
- For patients with spine tumors, it is important to assemble a multidisciplinary team to integrate diagnosis, treatment, symptom management, and rehabilitation. Patients with spine tumors have complex physical, psychological, and social care needs. Optimal management requires a multidisciplinary team including the following expertise: medical and radiation oncology, surgical specialties (ie, neurosurgery, orthopedic surgery, surgical oncology), radiology, interventionalists, pain specialists, bowel and bladder care, back care and ambulatory support, physical therapy, psychological and/or social services, and nutritional support. Early integration of palliative care and pain management is strongly recommended. [See NCCN Guidelines for Palliative Care and NCCN Guidelines for Adult Cancer Pain.](#)

¹Depending on local referral patterns and available expertise, this physician may be a neurosurgeon, neurologist, medical oncologist, or radiation oncologist.

Note: All recommendations are category 2A unless otherwise indicated.

Clinical Trials: NCCN believes that the best management of any patient with cancer is in a clinical trial. Participation in clinical trials is especially encouraged.

[Continued](#)

PRINCIPLES OF BRAIN AND SPINE TUMOR MANAGEMENT

Medical Management

1. Mass Effect, Brain Edema, Radiation Necrosis

- Steroid therapy should be carefully monitored. If a patient is asymptomatic, steroids may be unnecessary. Careful questioning for subtle symptoms should be undertaken if edema is extensive on imaging. In general, the lowest dose of steroids should be used for the shortest time possible.² Downward titration of the dose should be attempted whenever possible. Patients with extensive mass effect should receive steroids for at least 24 h before radiation therapy. Patients with a high risk of GI side effects (perioperative patients, prior history of ulcers/GI bleed, receiving NSAIDs or anticoagulation) should receive H₂ blockers or proton pump inhibitors. Care should be taken to watch for development of steroid side effects.³ Consider short-course bevacizumab for management of symptoms driven by RT necrosis, poorly controlled vasogenic edema, or mass effect in patients with brain metastases and primary brain tumors, particularly those with deep-seated unresectable tumors, as it may allow overall quality-of-life improvements by reducing steroid dose and improving functional status.⁴

2. Seizures

- Seizures are frequent in patients with primary or metastatic brain tumors. Despite this, studies have shown that the use of older, “traditional” antiepileptic drugs (AEDs), including phenytoin, phenobarbital, and valproic acid as prophylaxis against seizures in patients who have never had a seizure or who are undergoing neurosurgical procedures, is ineffective and is not recommended. Newer agents (ie, levetiracetam, topiramate, lamotrigine, pregabalin) have not yet been systematically studied. Seizure prophylaxis is not recommended as routine in asymptomatic patients but is reasonable to consider perioperatively.
- Many AEDs have significant effects on the cytochrome P450 system, and may have effects on the metabolism of numerous chemotherapeutic agents such as irinotecan, gefitinib, erlotinib, and temsirolimus among others. Where possible, such enzyme-inducing AEDs (EIAEDs) should be avoided (ie, phenytoin, phenobarbital, carbamazepine), and non-EIAEDs should be used instead (ie, levetiracetam, topiramate, valproic acid). Patients should be closely monitored for any adverse effects of the AEDs or chemotherapeutic agents.

3. Endocrine Disorders

- Endocrinopathies are common with brain tumor patients. This may be affected by concomitant steroid use as well as by radiotherapy, surgery, and certain medical therapies. Patients who present with a declining sense of well-being or quality of life should be evaluated not only for abnormalities related to their hypothalamic pituitary and adrenal axis, but also with regard to thyroid and gonad function.

4. Fatigue (Also see the [NCCN Guidelines for Cancer-Related Fatigue](#))

- Fatigue is commonly experienced by brain tumor patients. This symptom can be severe, persistent, emotionally overwhelming, and not related to the degree or duration of physical activity. Screening should be initiated to identify any underlying medical sources of this symptom, after which patients can be taught energy conservation and organizational skills to help manage this effect. Supervised, moderate exercise may be of assistance for those in otherwise good general medical condition. More data are needed on the use of CNS stimulants and these agents are not routinely recommended.

²An exception to this rule is in the case of suspected CNS lymphoma. Steroids should be avoided where possible ([see PCNS-1](#)) prior to biopsy to allow best chance of diagnosis.

³Refractory hyperglycemia, skin changes, visual changes, fluid retention, and myopathy. If any of these changes occur, it is imperative to evaluate potential palliative treatments for them and also to evaluate the current dose of steroids to see if it can be reduced in an attempt to mitigate these side effects.

⁴Kaley T, Nolan C, Carver A, Omuro A. Bevacizumab for acute neurologic deterioration in patients with glioblastoma. *CNS Oncol* 2013;2:413-418.

Note: All recommendations are category 2A unless otherwise indicated.

Clinical Trials: NCCN believes that the best management of any patient with cancer is in a clinical trial. Participation in clinical trials is especially encouraged.

[Continued](#)

BRAIN-E
2 OF 3

**PRINCIPLES OF BRAIN AND SPINE TUMOR MANAGEMENT****Medical Management—continued****5. Psychiatric Disorders (Also see the [NCCN Guidelines for Distress Management including NCCN Distress Tool \[DIS-A\]](#))**

- Depression and/or anxiety is common in neuro-oncology patients. These symptoms are greater than simple sadness or anxiety associated with the diagnosis of a tumor. The vegetative symptoms associated with depression or severe anxiety may become very disabling for the patient and distressing for the family. These symptoms will respond to psychotropic medications as they do in non-tumor patients. If less severe, strong support from behavioral health allies and other qualified counselors is also extremely beneficial. Physicians, and other members of their health care teams, should be sensitive to these symptoms and inquire about them in follow-up visits in order to determine if the patient may be a candidate for psychological or psychiatric treatment. Communication between members of the patient's health care team regarding the patient's response to treatment is important. See Andersen BL, DeRubeis RJ, Berman BS, et al. Screening, assessment, and care of anxiety and depressive symptoms in adults with cancer: an American Society of Clinical Oncology guideline adaptation. *J Clin Oncol* 2014;32:1605-1619.
- AEDs, anxiolytics, some chemotherapy agents, antiemetics, and other agents used directly in cancer therapy may affect mental status, alertness, and mood. Alterations in thought processes should trigger an investigation for any treatable causes, including endocrine disorders, infection, side effects of medication, or tumor progression.

6. Venous Thromboembolism (VTE)

- See the [NCCN Guidelines for Cancer-Associated Venous Thromboembolic Disease](#).

Allied Services

- Physical therapy, occupational therapy, and speech therapy may be helpful for many patients with CNS tumors, either benign or malignant. Surgical intervention is not a prerequisite for referral, and these therapies should not be withheld from patients because of the uncertain course of certain malignant tumors. Many patients with aggressive, malignant primary brain tumors or CNS metastases can benefit from inpatient rehabilitation.
- Practitioners are encouraged to serve as a resource and to refer patients to social services, support groups, and cancer patient advocacy organizations. Institutional or community resources that can assist patients and families in dealing with financial, insurance, and legal issues are important.
- Practitioners should be familiar with their state laws concerning seizures and driving so that they can advise patients and families appropriately.
- Practitioners should become familiar with palliative and hospice care resources that are available in their community in order to help educate patients and families that involvement of these services does not indicate a state of hopelessness, no further treatment, or abandonment. Palliative care should be integrated into management of neuro-oncology patients early in the course of their treatment. [See NCCN Guidelines for Palliative Care](#) and Ferrell BR, Temel JS, Temin S, et al. Integration of Palliative Care Into Standard Oncology Care: American Society of Clinical Oncology Clinical Practice Guideline Update. *J Clin Oncol* 2017;35:96-112.

Note: All recommendations are category 2A unless otherwise indicated.

Clinical Trials: NCCN believes that the best management of any patient with cancer is in a clinical trial. Participation in clinical trials is especially encouraged.



PRINCIPLES OF BRAIN TUMOR PATHOLOGY

- Incorporation of relevant diagnostic markers, including histopathologic and molecular information, as per the WHO 2016 Classification of Tumors of the Central Nervous System should be considered standard practice for tumor classification.
- Molecular/genetic characterization complements standard histologic analysis, providing additional diagnostic and prognostic information that can greatly improve diagnostic accuracy, influence treatment selection, and possibly improve management decision-making.

Standard Histopathologic Examination and Classification

- Histologic subgrouping of CNS neoplasms provides valuable prognostic information, as is described in the WHO Classification of Tumors of the Central Nervous System.¹
- Inter-observer discrepancies in histologic diagnosis and grading are a recognized issue, due to the inherently subjective nature of certain aspects of histopathologic interpretation (eg, astrocytic vs. oligodendroglial morphology). Also, surgical sampling does not always capture all the relevant diagnostic features in morphologically heterogeneous tumors.
- Even so, the traditional histologic classification of CNS neoplasms into primary neuroectodermal neoplasms (eg, glial, neuronal, embryonal) from other primary CNS neoplasms (eg, lymphoma, germ cell, meningeal), metastatic neoplasms, and non-neoplastic conditions mimicking tumors remains fundamental to any pathologic assessment.

Molecular Characterization

- With the use of genetic and molecular testing, histologically similar CNS neoplasms can be differentiated more accurately in terms of prognosis and, in some instances, for response to different therapies.²⁻⁶
- Molecular characterization of primary CNS tumors has substantially impacted clinical trial eligibility and risk stratification in the past 10 years, thereby evolving the standard of care towards an integrated tumor diagnosis in neuro-oncology.
- Molecular/genetic characterization does not replace standard histologic assessment, but serves as a complementary approach to provide additional diagnostic and prognostic information that often enhances treatment selection.
- There are no identified targeted agents with demonstrated efficacy in glioblastoma. However, the panel encourages molecular testing of tumor because if a driver mutation is detected, it may be reasonable to treat with a targeted therapy on a compassionate use basis and/or the patient may have more treatment options in the context of a clinical trial. Molecular testing also has a valuable role in improving diagnostic accuracy and prognostic stratification that may inform treatment selection.

Note: All recommendations are category 2A unless otherwise indicated.

Clinical Trials: NCCN believes that the best management of any patient with cancer is in a clinical trial. Participation in clinical trials is especially encouraged.

**PRINCIPLES OF BRAIN TUMOR PATHOLOGY MOLECULAR MARKERS**

The following molecular markers are often used by neuropathologists to facilitate characterization of gliomas and/or by neuro-oncologists to guide treatment decisions:

Isocitrate Dehydrogenase 1 and 2 (IDH1 and IDH2) Mutation

- **Recommendation:** IDH mutation testing is required for the workup of glioma.
- **Description:** IDH1 and IDH2 are metabolic enzymes. Specific mutations in genes encoding these enzymes lead to the aberrant production of D-2-hydroxyglutarate, an oncometabolite that causes epigenetic modifications in affected cells.⁷
- **Detection:** The most common IDH1 mutation (R132H) is reliably screened by mutation-specific immunohistochemistry, which is recommended for all glioma patients. If the R132H immunostain result is negative, in the appropriate clinical context, sequencing of IDH1 and IDH2 is highly recommended to detect less common IDH1 and IDH2 mutations. Standard sequencing methods include Sanger sequencing, pyrosequencing, and next-generation sequencing, and should be performed on formalin-fixed, paraffin-embedded tissue.⁷
- **Diagnostic value:**
 - ▶ IDH mutations define WHO grade II and III astrocytomas and oligodendrogliomas, and the secondary grade IV glioblastomas into which astrocytomas often evolve. Their presence distinguishes lower-grade gliomas from primary glioblastomas, which are IDH-wild type.^{8,9} Detection of these mutations in a specimen that is otherwise equivocal for tumor may also be regarded as evidence that a diffusely infiltrative glioma is present.⁷
 - ▶ True grade I non-infiltrative gliomas, such as pilocytic astrocytomas and gangliogliomas, do not contain IDH mutations. In such cases, detection of an IDH mutation indicates that the tumor is at least a grade II diffusely infiltrative glioma.⁷
- **Prognostic value:**
 - ▶ IDH mutations are commonly associated with MGMT promoter methylation.⁴
 - ▶ IDH1 or 2 mutations are associated with a relatively favorable prognosis and are important in stratification for clinical trials.¹⁰
 - ▶ In grade II or III infiltrative gliomas, wild-type IDH1 or 2 is associated with increased risk of aggressive disease.⁴
 - ▶ IDH1 or 2 mutations are associated with a survival benefit for patients treated with radiation or alkylator chemotherapy.^{11,12}

Note: All recommendations are category 2A unless otherwise indicated.

Clinical Trials: NCCN believes that the best management of any patient with cancer is in a clinical trial. Participation in clinical trials is especially encouraged.

[Continued](#)
[References](#)

BRAIN-F
2 OF 8

**PRINCIPLES OF BRAIN TUMOR PATHOLOGY MOLECULAR MARKERS**

The following molecular markers are often used by neuropathologists to facilitate characterization of gliomas and/or by neuro-oncologists to guide treatment decisions:

Codeletion of 1p and 19q

- **Recommendation:** 1p19q testing is an essential part of molecular diagnostics for oligodendroglioma.
- **Description:** This codeletion represents an unbalanced translocation (1;19)(q10;p10), leading to whole-arm deletion of 1p and 19q.¹³
- **Detection:** The codeletion of 1p and 19q is detectable by fluorescence in situ hybridization (FISH) or polymerase chain reaction (PCR). Additional methods, including array-based genomic copy number testing and next-generation sequencing, may also be employed.
- **Diagnostic value:** It is strongly associated with oligodendroglial histology and helps confirm the oligodendroglial character of tumors with equivocal or mixed histologic features.¹⁴
 - ▶ IDH-mutated gliomas that do NOT show loss of ATRX (for example, by IHC) should be strongly considered for 1p19q testing, even if not clearly oligodendroglial by histology. Conversely, IDH1 wild-type gliomas do not contain true whole-arm 1p/19q codeletion.¹⁵ Therefore, 1p/19q testing is unnecessary if a glioma is not IDH-mutant, and a glioma should not be regarded as 1p/19q-codeleted without an accompanying IDH mutation, regardless of test results.
 - ▶ A tumor should only be diagnosed as an oligodendroglioma if it contains both an IDH mutation and 1p/19q codeletion. Furthermore, the term “oligoastrocytoma” should no longer be used, as such morphologically ambiguous tumors can reliably be resolved into astrocytomas and oligodendrogliomas with molecular testing.¹⁶
- **Prognostic value:** The codeletion confers a favorable prognosis and is predictive of response to alkylating chemotherapy and combination therapy with radiation and alkylating chemotherapy.^{17,18}

MGMT Promoter Methylation

- **Recommendation:** MGMT promoter methylation is an essential part of molecular diagnostics for all high-grade gliomas (grade III and IV).
- **Description:** MGMT (O⁶-methylguanine-DNA methyltransferase) is a DNA repair enzyme that reverses the DNA damage caused by alkylating agents, resulting in tumor resistance to temozolomide and nitrosourea-based chemotherapy. Methylation of the MGMT promoter silences MGMT, making the tumor more sensitive to treatment with alkylating agents.¹⁹
- **Detection:** Methylation of the MGMT promoter is detectable by methylation-specific PCR,²⁰ pyrosequencing,²¹ or array-based technologies.²²
- **Prognostic value:**
 - ▶ MGMT promoter methylation is strongly associated with IDH mutations and genome-wide epigenetic changes (G-CIMP phenotype).⁴
 - ▶ MGMT promoter methylation confers a survival advantage in glioblastoma and is used for risk stratification in clinical trials.²³
 - ▶ MGMT promoter methylation is particularly useful in treatment decisions for elderly patients with high-grade gliomas (grades III-IV).^{24,25}
 - ▶ Patients with glioblastoma that are not MGMT promoter methylated derive less benefit from treatment with temozolomide compared to those whose tumors are methylated.²³

Note: All recommendations are category 2A unless otherwise indicated.

Clinical Trials: NCCN believes that the best management of any patient with cancer is in a clinical trial. Participation in clinical trials is especially encouraged.

[Continued](#)
[References](#)**BRAIN-F**
3 OF 8



PRINCIPLES OF BRAIN TUMOR PATHOLOGY MOLECULAR MARKERS

The following molecular markers are often used by neuropathologists to facilitate characterization of gliomas and/or by neuro-oncologists to guide treatment decisions:

ATRX Mutation

- **Recommendation:** ATRX mutation testing is strongly recommended but not required for glioma.
- **Description:** ATRX encodes a chromatin regulator protein. Loss of function mutations enable alternative lengthening of telomeres (ALT).²⁶
- **Detection:** ATRX mutations can be detected by IHC for wild-type ATRX (loss of wild-type expression) and/or sequencing.²⁷
- **Diagnostic value:** ATRX mutations in glioma are strongly associated with IDH mutations, and are nearly always mutually exclusive with 1p/19q codeletion.²⁷ ATRX deficiency, coupled with IDH mutation, is typical of astrocytoma. A lack of ATRX immunostaining in glioblastoma should trigger IDH1/2 sequencing if R132H IDH1 immunostain is negative, due to the frequent co-occurrence of ATRX and IDH mutations.^{5,27}

TERT Mutation

- **Recommendation:** TERT mutation testing is recommended but not required for gliomas.
- **Description:** TERT encodes the catalytic active site of telomerase, the enzyme responsible for maintaining telomere length in dividing cells. TERT mutations found in gliomas are located in its noncoding promoter region, and cause increased expression of the TERT protein.²⁸
- **Detection:** TERT mutations can be detected by sequencing of the promoter region.²⁹
- **Diagnostic value:** TERT mutations are almost invariably present in 1p/19q codeleted oligodendroglioma, and are found in most glioblastomas. TERT mutation, in combination with IDH mutation and 1p/19q codeletion, is characteristic of oligodendroglioma. Absence of TERT mutation, coupled with IDH mutation, designates astrocytoma.
- **Prognostic value:** In the absence of an IDH mutation, TERT mutations in diffusely infiltrative gliomas are associated with reduced overall survival compared to gliomas lacking TERT mutations.^{4,30,31} Combined TERT and IDH mutations in the absence of 1p/19q codeletion is an uncommon event, but such tumors have a prognosis as favorable as gliomas with all three molecular alterations.^{4,30}

Note: All recommendations are category 2A unless otherwise indicated.

Clinical Trials: NCCN believes that the best management of any patient with cancer is in a clinical trial. Participation in clinical trials is especially encouraged.

**PRINCIPLES OF BRAIN TUMOR PATHOLOGY MOLECULAR MARKERS**

The following molecular markers are often used by neuropathologists to facilitate characterization of gliomas and/or by neuro-oncologists to guide treatment decisions:

H3F3A Mutation

- **Recommendation:** H3F3A mutation testing is recommended in the appropriate clinical context.
- **Description:** The most common histone mutation in brain tumors, H3K27M, is caused by a lysine-to-methionine substitution in the H3F3A gene and inhibits the trimethylation of H3.3 histone. G34 mutations are more common in cortical gliomas in children.³²⁻³⁴
- **Detection:** Although a K27M histone antibody is available,³⁵ it is not 100% specific and interpretation can be difficult for non-experts. Therefore, screening by H3F3A sequencing is a viable alternative and the preferred approach, especially since it will also detect mutations in G34.
- **Diagnostic value:** Histone mutations most commonly occur in pediatric midline gliomas (eg, diffuse intrinsic pontine gliomas [DIPG]), although midline gliomas in adults can also contain histone mutations.³⁶ Their presence can be considered solid evidence of an infiltrative glioma, which is often helpful in small biopsies of midline lesions that may not be fully diagnostic with light microscopy or do not fully resemble infiltrative gliomas.^{32,33,36}
- **Prognostic value:** K27M gliomas typically do not have MGMT promoter methylation, and the mutation is an adverse prognostic marker in children and adults. The G34 mutation does not appear to have any prognostic significance once the diagnosis of a glioblastoma has been established.^{33,36,37}

BRAF Mutation

- **Recommendation:** BRAF fusion and/or mutation testing is recommended in the appropriate clinical context.
- **Description:** Activating mutations in BRAF, most commonly the V600E variant seen in other cancers (eg, melanoma), are present in 60%–80% of supratentorial grade II-III pleomorphic xanthoastrocytomas (PXA), 30% of dysembryoplastic neuroepithelial tumors, 20% of grade I gangliogliomas, and 5% of grade I pilocytic astrocytomas (PA). Diffusely infiltrative gliomas can also harbor a BRAF mutation, especially in children. BRAF V600E has even been found in nonneoplastic cortical dysplasia. In contrast, activating BRAF fusions occur predominately in PA of the posterior fossa, although some supratentorial PA also have this fusion.³⁸⁻⁴⁰
- **Detection:** BRAF V600E is best detected by sequencing, and BRAF fusions can be detected with RNA-Seq or other PCR-based breakpoint methods that capture the main 16-9, 15-9, and 16-11 breakpoints between BRAF and its main fusion partner, KIAA1549. FISH is too unreliable to detect BRAF fusions.³⁸
- **Diagnostic value:** The presence of a BRAF fusion is reliable evidence that the tumor is a pilocytic astrocytoma, provided the histology is compatible. BRAF V600E is more complicated, as it can occur in a variety of tumors over all four WHO grades and requires integration with histology.
- **Prognostic value:** Tumors with BRAF fusions tend to be indolent, with occasional recurrence but only rare progression to lethality. BRAF V600E tumors show a much greater range of outcomes and need to be considered in context with other mutations and clinicopathologic findings (eg, CDKN2A/B deletion). BRAF V600E tumors may respond to BRAF inhibitors such as vemurafenib, but comprehensive clinical trials are still ongoing.⁴¹⁻⁴³

Note: All recommendations are category 2A unless otherwise indicated.

Clinical Trials: NCCN believes that the best management of any patient with cancer is in a clinical trial. Participation in clinical trials is especially encouraged.

[Continued](#)
[References](#)

BRAIN-F
5 OF 8

**PRINCIPLES OF BRAIN TUMOR PATHOLOGY MOLECULAR MARKERS**

The following molecular markers are often used by neuropathologists to facilitate characterization of gliomas and/or by neuro-oncologists to guide treatment decisions:

RELA fusion

- **Recommendation:** RELA fusion testing is recommended in the appropriate clinical context.
- **Description:** Ependymomas arising in the supratentorium often contain activating fusions of RELA. Increased RELA activity leads to increased NF-kappa-B signaling and more aggressive behavior. This event is more common in children than in adults, and occurs only in the supratentorium, not the posterior fossa or spine.^{44,45}
- **Detection:** The most common RELA fusion partner is C11orf95. This can be detected with RNA-Seq or a break-apart FISH probe set.⁴⁶
- **Diagnostic value:** Detection of RELA fusion is not required for the diagnosis of ependymoma, as this entity is still diagnosed by light microscopy.
- **Prognostic value:** RELA fusion-positive ependymomas are now a distinct entity in the WHO classification of central nervous system tumors, as this subset of ependymomas tends to be far more aggressive than other supratentorial ependymomas.^{1,44,45}

Medulloblastoma Molecular Subtyping

- **Recommendation:** Medulloblastoma testing should be referred to academic tertiary centers with expertise in this area.
- **Description:** Medulloblastomas are WHO grade IV tumors that predominantly arise from the cerebellum in pediatric patients, but can also occur in adults. The WHO committee on central nervous system tumors now recommends subclassification of these tumors into four distinct groups: i) WNT-activated; ii) SHH-activated and TP53-mutant; iii) SHH-activated and TP53-wildtype; and iv) non-WNT/non-SHH.^{1,47}
- **Detection:** Virtually all WNT-driven medulloblastomas will contain mutations in either CTNNB1 or, less commonly, APC (the latter mutation may be germline if the patient has Turcot syndrome). WNT-driven tumors will also usually contain monosomy 6. Nuclear immunoreactivity for beta-catenin is a very useful way to identify WNT medulloblastomas, in conjunction with CTNNB1 sequencing and chromosome 6 FISH. Differentiating between WNT-activated, SHH-activated, and non-WNT/non-SHH tumors is best classified by expression arrays, DNA methylation arrays, or an immunohistochemistry panel composed of beta-catenin, GAB1, and YAP1. Because there are a variety of hotspots in TP53, gene sequencing is recommended in SHH-activated medulloblastomas.⁴⁸⁻⁵¹
- **Diagnostic value:** None of the molecular markers associated with each medulloblastoma subtype is specific to medulloblastomas; the diagnosis of medulloblastoma is still made on the basis of light microscopy.
- **Prognostic value:** The most important aspect of medulloblastoma molecular diagnostics is that the WNT-activated subset has a markedly better prognosis relative to the other three subtypes, regardless of age at diagnosis. Among SHH-activated medulloblastomas, detection of TP53 mutations is associated with more aggressive behavior, whereas TP53-wildtype SHH-activated medulloblastomas have a variable course. Non-WNT/non-SHH medulloblastomas also show a variable course.^{1,47,52}

Note: All recommendations are category 2A unless otherwise indicated.

Clinical Trials: NCCN believes that the best management of any patient with cancer is in a clinical trial. Participation in clinical trials is especially encouraged.

References

PRINCIPLES OF BRAIN TUMOR PATHOLOGY
REFERENCES

- ¹Louis DN, Perry A, Reifenberger G, et al. The 2016 World Health Organization Classification of Tumors of the Central Nervous System: a summary. *Acta Neuropathol* 2016;131:803-820.
- ²Weller M, Pfister SM, Wick W, et al. Molecular neuro-oncology in clinical practice: a new horizon. *Lancet Oncol* 2013;14:e370-379.
- ³Hegi ME, Stupp R. Withholding temozolomide in glioblastoma patients with unmethylated MGMT promoter--still a dilemma? *Neuro Oncol* 2015;17:1425-1427.
- ⁴Eckel-Passow JE, Lachance DH, Molinaro AM, et al. Glioma Groups Based on 1p/19q, IDH, and TERT Promoter Mutations in Tumors. *N Engl J Med* 2015;372:2499-2508.
- ⁵Cancer Genome Atlas Research N, Brat DJ, Verhaak RG, et al. Comprehensive, Integrative Genomic Analysis of Diffuse Lower-Grade Gliomas. *N Engl J Med* 2015;372:2481-2498.
- ⁶Dubbink HJ, Atmodimedjo PN, Kros JM, et al. Molecular classification of anaplastic oligodendroglioma using next-generation sequencing: a report of the prospective randomized EORTC Brain Tumor Group 26951 phase III trial. *Neuro Oncol* 2016;18:388-400.
- ⁷Horbinski C. What do we know about IDH1/2 mutations so far, and how do we use it? *Acta Neuropathol* 2013;125:621-636.
- ⁸Hartmann C, Meyer J, Balss J, et al. Type and frequency of IDH1 and IDH2 mutations are related to astrocytic and oligodendroglial differentiation and age: a study of 1,010 diffuse gliomas. *Acta Neuropathol* 2009;118:469-474.
- ⁹Yan H, Parsons DW, Jin G, et al. IDH1 and IDH2 mutations in gliomas. *N Engl J Med* 2009;360:765-773.
- ¹⁰Sanson M, Marie Y, Paris S, et al. Isocitrate dehydrogenase 1 codon 132 mutation is an important prognostic biomarker in gliomas. *J Clin Oncol* 2009;27:4150-4154.
- ¹¹Hartmann C, Hentschel B, Wick W, et al. Patients with IDH1 wild type anaplastic astrocytomas exhibit worse prognosis than IDH1-mutated glioblastomas, and IDH1 mutation status accounts for the unfavorable prognostic effect of higher age: implications for classification of gliomas. *Acta Neuropathol* 2010;120:707-718.
- ¹²Houillier C, Wang X, Kaloshi G, et al. IDH1 or IDH2 mutations predict longer survival and response to temozolomide in low-grade gliomas. *Neurology* 2010;75:1560-1566.
- ¹³Jenkins RB, Blair H, Ballman KV, et al. A t(1;19)(q10;p10) mediates the combined deletions of 1p and 19q and predicts a better prognosis of patients with oligodendroglioma. *Cancer Res* 2006;66:9852-9861.
- ¹⁴Burger PC, Minn AY, Smith JS, et al. Losses of chromosomal arms 1p and 19q in the diagnosis of oligodendroglioma. A study of paraffin-embedded sections. *Mod Pathol* 2001;14:842-853.
- ¹⁵Labussiere M, Idhahbi A, Wang XW, et al. All the 1p19q codeleted gliomas are mutated on IDH1 or IDH2. *Neurology* 2010;74:1886-1890.
- ¹⁶Sahm F, Reuss D, Koelsche C, et al. Farewell to oligoastrocytoma: in situ molecular genetics favor classification as either oligodendroglioma or astrocytoma. *Acta Neuropathol* 2014;128:551-559.
- ¹⁷van den Bent MJ, Brandes AA, Taphoorn MJ, et al. Adjuvant procarbazine, lomustine, and vincristine chemotherapy in newly diagnosed anaplastic oligodendroglioma: long-term follow-up of EORTC brain tumor group study 26951. *J Clin Oncol* 2013;31:344-350.
- ¹⁸Cairncross G, Wang M, Shaw E, et al. Phase III Trial of Chemoradiotherapy for Anaplastic Oligodendroglioma: Long-Term Results of RTOG 9402. *J Clin Oncol* 2013;31:337-343.
- ¹⁹Esteller M, Garcia-Foncillas J, Andion E, et al. Inactivation of the DNA-repair gene MGMT and the clinical response of gliomas to alkylating agents. *N Engl J Med* 2000;343:1350-1354.
- ²⁰Vlassenbroeck I, Califice S, Diserens AC, et al. Validation of real-time methylation-specific PCR to determine O6-methylguanine-DNA methyltransferase gene promoter methylation in glioma. *J Mol Diagn* 2008;10:332-337.
- ²¹Xie H, Tubbs R, Yang B. Detection of MGMT promoter methylation in glioblastoma using pyrosequencing. *Int J Clin Exp Pathol* 2015;8:636-642.
- ²²Bady P, Sciuscio D, Diserens AC, et al. MGMT methylation analysis of glioblastoma on the Infinium methylation BeadChip identifies two distinct CpG regions associated with gene silencing and outcome, yielding a prediction model for comparisons across datasets, tumor grades, and CIMP-status. *Acta Neuropathol* 2012;124:547-560.
- ²³Hegi ME, Diserens AC, Gorlia T, et al. MGMT gene silencing and benefit from temozolomide in glioblastoma. *N Engl J Med* 2005;352:997-1003.
- ²⁴Malmstrom A, Gronberg BH, Marosi C, et al. Temozolomide versus standard 6-week radiotherapy versus hypofractionated radiotherapy in patients older than 60 years with glioblastoma: the Nordic randomised, phase 3 trial. *Lancet Oncol* 2012;13:916-926.
- ²⁵Wick W, Platten M, Meisner C, et al. Temozolomide chemotherapy alone versus radiotherapy alone for malignant astrocytoma in the elderly: the NOA-08 randomised, phase 3 trial. *Lancet Oncol* 2012;13:707-715.

Note: All recommendations are category 2A unless otherwise indicated.**Clinical Trials:** NCCN believes that the best management of any patient with cancer is in a clinical trial. Participation in clinical trials is especially encouraged.[Continued](#)

PRINCIPLES OF BRAIN TUMOR PATHOLOGY REFERENCES

- ²⁶Koschmann C, Calinescu AA, Nunez FJ, et al. ATRX loss promotes tumor growth and impairs nonhomologous end joining DNA repair in glioma. *Sci Transl Med* 2016;8:328ra328.
- ²⁷Reuss DE, Sahm F, Schrimpf D, et al. ATRX and IDH1-R132H immunohistochemistry with subsequent copy number analysis and IDH sequencing as a basis for an "integrated" diagnostic approach for adult astrocytoma, oligodendroglioma and glioblastoma. *Acta Neuropathol* 2015;129:133-146.
- ²⁸Arita H, Narita Y, Fukushima S, et al. Upregulating mutations in the TERT promoter commonly occur in adult malignant gliomas and are strongly associated with total 1p19q loss. *Acta Neuropathol* 2013;126:267-276.
- ²⁹Nikiforova MN, Wald AI, Melan MA, et al. Targeted next-generation sequencing panel (GliOSeq) provides comprehensive genetic profiling of central nervous system tumors. *Neuro Oncol* 2016;18:379-387.
- ³⁰Killela PJ, Reitman ZJ, Jiao Y, et al. TERT promoter mutations occur frequently in gliomas and a subset of tumors derived from cells with low rates of self-renewal. *Proc Natl Acad Sci U S A* 2013;110:6021-6026.
- ³¹Arita H, Yamasaki K, Matsushita Y, et al. A combination of TERT promoter mutation and MGMT methylation status predicts clinically relevant subgroups of newly diagnosed glioblastomas. *Acta Neuropathol Commun* 2016;4:79.
- ³²Schwartzentruber J, Korshunov A, Liu XY, et al. Driver mutations in histone H3.3 and chromatin remodelling genes in paediatric glioblastoma. *Nature* 2012;482:226-231.
- ³³Sturm D, Witt H, Hovestadt V, et al. Hotspot mutations in H3F3A and IDH1 define distinct epigenetic and biological subgroups of glioblastoma. *Cancer Cell* 2012;22:425-437.
- ³⁴Wu G, Broniscer A, McEachron TA, et al. Somatic histone H3 alterations in pediatric diffuse intrinsic pontine gliomas and non-brainstem glioblastomas. *Nat Genet* 2012;44:251-253.
- ³⁵Bechet D, Gielen GG, Korshunov A, et al. Specific detection of methionine 27 mutation in histone 3 variants (H3K27M) in fixed tissue from high-grade astrocytomas. *Acta Neuropathol* 2014;128:733-741.
- ³⁶Meyronet D, Esteban-Mader M, Bonnet C, et al. Characteristics of H3 K27M-mutant gliomas in adults. *Neuro Oncol* 2017;19:1127-1134.
- ³⁷Khuong-Quang DA, Buczkowicz P, Rakopoulos P, et al. K27M mutation in histone H3.3 defines clinically and biologically distinct subgroups of pediatric diffuse intrinsic pontine gliomas. *Acta Neuropathol* 2012;124:439-447.
- ³⁸Horbinski C. To BRAF or not to BRAF: is that even a question anymore? *J Neuropathol Exp Neurol* 2013;72:2-7. ³⁹Qaddoumi I, Orisme W, Wen J, et al. Genetic alterations in uncommon low-grade neuroepithelial tumors: BRAF, FGFR1, and MYB mutations occur at high frequency and align with morphology. *Acta Neuropathol* 2016;131:833-845.
- ⁴⁰Chappe C, Padovani L, Scavarda D, et al. Dysembryoplastic neuroepithelial tumors share with pleomorphic xanthoastrocytomas and gangliogliomas BRAF(V600E) mutation and expression. *Brain Pathol* 2013;23:574-583.
- ⁴¹Hawkins C, Walker E, Mohamed N, et al. BRAF-KIAA1549 fusion predicts better clinical outcome in pediatric low-grade astrocytoma. *Clin Cancer Res* 2011;17:4790-4798.
- ⁴²Horbinski C, Nikiforova MN, Hagenkord JM, et al. Interplay among BRAF, p16, p53, and MIB1 in pediatric low-grade gliomas. *Neuro Oncol* 2012;14:777-789.
- ⁴³Horbinski C, Hamilton RL, Nikiforov Y, Pollack IF. Association of molecular alterations, including BRAF, with biology and outcome in pilocytic astrocytomas. *Acta Neuropathol* 2010;119:641-649.
- ⁴⁴Parker M, Mohankumar KM, Punchedewa C, et al. C11orf95-RELA fusions drive oncogenic NF-kappaB signalling in ependymoma. *Nature* 2014;506:451-455.
- ⁴⁵Pajtler KW, Witt H, Sill M, et al. Molecular Classification of Ependymal Tumors across All CNS Compartments, Histopathological Grades, and Age Groups. *Cancer Cell* 2015;27:728-743.
- ⁴⁶Olsen TK, Panagopoulos I, Gorunova L, et al. Novel fusion genes and chimeric transcripts in ependymal tumors. *Genes Chromosomes Cancer* 2016;55:944-953.
- ⁴⁷Kool M, Korshunov A, Remke M, et al. Molecular subgroups of medulloblastoma: an international meta-analysis of transcriptome, genetic aberrations, and clinical data of WNT, SHH, Group 3, and Group 4 medulloblastomas. *Acta Neuropathol* 2012;123:473-484.
- ⁴⁸Northcott PA, Buchhalter I, Morrissy AS, et al. The whole-genome landscape of medulloblastoma subtypes. *Nature* 2017;547:311-317.
- ⁴⁹Ellison DW, Kocak M, Dalton J, et al. Definition of disease-risk stratification groups in childhood medulloblastoma using combined clinical, pathologic, and molecular variables. *J Clin Oncol* 2011;29:1400-1407. Available at: <https://www.ncbi.nlm.nih.gov/pubmed/20921458>
- ⁵⁰Schwalbe EC, Williamson D, Lindsey JC, et al. DNA methylation profiling of medulloblastoma allows robust subclassification and improved outcome prediction using formalin-fixed biopsies. *Acta Neuropathol* 2013;125:359-371.
- ⁵¹Taylor MD, Northcott PA, Korshunov A, et al. Molecular subgroups of medulloblastoma: the current consensus. *Acta Neuropathol* 2012;123:465-472.
- ⁵²Zhukova N, Ramaswamy V, Remke M, et al. Subgroup-specific prognostic implications of TP53 mutation in medulloblastoma. *J Clin Oncol* 2013;31:2927-2935.

Note: All recommendations are category 2A unless otherwise indicated.

Clinical Trials: NCCN believes that the best management of any patient with cancer is in a clinical trial. Participation in clinical trials is especially encouraged.

Discussion

The Overview and Gliomas sections have been updated to correspond with the updated algorithms. The rest of the discussion update is in progress and was last updated 08/27/14.

NCCN Categories of Evidence and Consensus

Category 1: Based upon high-level evidence, there is uniform NCCN consensus that the intervention is appropriate.

Category 2A: Based upon lower-level evidence, there is uniform NCCN consensus that the intervention is appropriate.

Category 2B: Based upon lower-level evidence, there is NCCN consensus that the intervention is appropriate.

Category 3: Based upon any level of evidence, there is major NCCN disagreement that the intervention is appropriate.

All recommendations are category 2A unless otherwise indicated.

Table of Contents

Overview	MS-2
Tumor Types.....	MS-2
Principles of Management	MS-2
Treatment Principles	MS-2
Gliomas	MS-3
Molecular Profiling for Gliomas.....	MS-3
Low-Grade Infiltrative Astrocytomas and Oligodendrogliomas...	MS-6
Anaplastic Gliomas and Glioblastomas.....	MS-10
Intracranial and Spinal Ependymomas	MS-17
Treatment Overview	MS-17
NCCN Recommendations	MS-18

Medulloblastoma and Supratentorial PNET	MS-19
Treatment Overview	MS-19
NCCN Recommendations	MS-19
Primary CNS Lymphomas	MS-20
Treatment Overview	MS-21
NCCN Recommendations	MS-22
Primary Spinal Cord Tumors	MS-24
Treatment Overview	MS-25
NCCN Recommendations	MS-26
Meningiomas	MS-26
Imaging.....	MS-26
Treatment Overview	MS-27
NCCN Recommendations	MS-28
Brain Metastases	MS-28
Treatment Overview	MS-29
NCCN Recommendations	MS-32
Leptomeningeal Metastases	MS-33
Treatment Overview	MS-34
NCCN Recommendations	MS-34
Metastatic Spinal Tumors	MS-36
Treatment Overview	MS-37
NCCN Recommendations	MS-39
References	MS-41

Overview

The Overview and Gliomas sections and corresponding references have been updated to correspond with the updated algorithms.

In the year 2018, an estimated 23,880 people in the United States will be diagnosed with a primary malignant brain tumor or other central nervous system (CNS) neoplasms.¹ These tumors will be responsible for approximately 16,830 deaths. The incidence of primary brain tumors has been increasing over the last 30 years, especially in older adults.²

Tumor Types

The NCCN Guidelines for CNS Cancers focus on management of the following adult CNS cancers: low-grade infiltrative supratentorial astrocytomas, oligodendrogliomas, anaplastic gliomas and glioblastoma, ependymomas, medulloblastoma, brain metastases, leptomeningeal metastases, non–AIDS-related primary CNS lymphomas (PCNSLs), metastatic spinal tumors, meningiomas, and primary spinal cord tumors. These guidelines are updated annually to include new information or treatment philosophies as they become available. However, because this field continually evolves, practitioners should use all of the available information to determine the best clinical options for their patients.

Principles of Management

Primary brain tumors are a heterogeneous group of neoplasms with varied outcomes and management strategies. Primary malignant brain tumors range from pilocytic astrocytomas, which are very uncommon, noninvasive, and surgically curable, to glioblastoma, the most common intraparenchymal brain tumor in adults, which is highly invasive and virtually incurable. Likewise, patients with metastatic brain disease may have rapidly progressive systemic disease or no systemic cancer at all. These patients may have one or dozens of brain metastases, and they may have a malignancy that is highly responsive or, alternatively, highly

resistant to radiation therapy (RT) or chemotherapy. Because of this marked heterogeneity, the prognostic features and treatment options for primary brain tumors must be carefully reviewed on an individual basis and sensitively communicated to each patient. In addition, these CNS tumors are associated with a range of symptoms and complications such as edema, seizures, endocrinopathy, fatigue, psychiatric disorders, and venous thromboembolism that can seriously impact patients' quality of life. The involvement of an interdisciplinary team, including neurosurgeons, RT therapists, oncologists, neurologists, and neuroradiologists, is a key factor in the appropriate management of these patients. For any subtype of malignant brain tumors, the NCCN Panel encourages thorough multidisciplinary review of each patient's case once the pathology is available. Further discussion of multidisciplinary care and allied services, as well as guidelines on medical management of various disease complications, can be found in the algorithm section, *Principles of Brain and Spine Tumor Management*. In 2016, the panel added a section describing guiding principles for CNS tumor pathology, given the recent addition of molecular parameters in the WHO classification of CNS tumors.³

Treatment Principles

Several important principles guide surgical treatment and RT for adults with brain tumors. Regardless of tumor histology, neurosurgeons generally provide the best outcome for their patients if they remove as much tumor as safely possible (ideally achieving a gross total resection [GTR]) and thereby providing sufficient representative tumor tissue to ensure an accurate diagnosis. Decisions regarding aggressiveness of surgery for primary brain tumors are complex and depend on the: 1) age and performance status (PS) of the patient; 2) proximity to “eloquent” areas of the brain; 3) feasibility of decreasing the mass effect with aggressive surgery; 4) resectability of the tumor (including the

number and location of lesions); and 5) time since last surgery in patients with recurrent disease.⁴

The surgical options include stereotactic biopsy, open biopsy, subtotal resection (STR), or complete resection (GTR). The pathologic diagnosis is critical and may be difficult to accurately determine without sufficient tumor tissue. Review by an experienced neuropathologist is highly recommended. In addition, a postoperative brain MRI scan should be obtained 24 to 72 hours after surgery to document the extent of residual disease after surgical intervention.

Radiation oncologists use several different treatment modalities in patients with primary brain tumors, including brachytherapy, fractionated stereotactic RT, and stereotactic radiosurgery (SRS). Standard fractionated external beam RT (EBRT) is the most common approach. Hypofractionated radiation is an appropriate option for select patients (ie, older adults and patients with a poor PS). RT for patients with primary brain tumors is administered within a limited field (tumor and surround), while whole brain RT (WBRT) and SRS are used primarily for brain metastases.

Enrollment in a clinical trial is the preferred treatment for eligible patients. Clinicians are advised to consult the algorithm sections, *Principles of Brain and Spine Tumor Imaging*, *Principles of Brain Tumor Surgery*, and *Principles of Brain Tumor Pathology* for further discussion of surgical management and diagnosis. The dose of RT administered varies depending on the pathology as seen in *Principles of Brain and Spinal Cord Tumor Radiation Therapy*. Appropriate chemotherapeutic and biologic regimens for each tumor subtype are listed under *Principles of Brain and Spinal Cord Tumor Systemic Therapy*.

Gliomas

The NCCN Guidelines for CNS Cancers include recommendations for management of grade II gliomas (ie, diffuse astrocytomas and oligodendrogliomas), grade III gliomas (ie, anaplastic astrocytoma and oligodendroglioma), and grade IV gliomas (ie, glioblastoma).³

Molecular Profiling for Gliomas

In 2016, *Principles of Brain Tumor Pathology* was added to the NCCN Guidelines for CNS Cancers to provide guidance for histopathologic and molecular characterization of gliomas, which should now be standard practice. Molecular/genetic characterization complements standard histologic analysis, providing additional diagnostic and prognostic information that may improve diagnostic accuracy and aid in treatment selection.

Updated Classification of Gliomas Based on Histology and Molecular Features

Key changes to the WHO classification system for version 2016 for grade II–III gliomas are as follows: 1) oligodendrogliomas are defined as only tumors that have 1p19q codeletion and *IDH* mutation (unless molecular data are not available and cannot be obtained, in which case designation can be based on histology; 2) anaplastic gliomas are further subdivided according to *IDH* mutation status; and 3) oligoastrocytoma is no longer a valid designation unless molecular data (1p19q deletion and *IDH* mutation status) are not available and cannot be obtained, or there are phenotypic and genotypic evidence of spatially distinct oligodendroglioma (1p19q codeleted) and astrocytoma (1p19q intact or deletion of only 1p or 19q) components in the same tumor.³ It is important to note that correlations between the molecularly defined 2016 WHO categories and the histology-based 2007 WHO categories are limited and vary across studies.^{5–8} Thus, the change from 2007

WHO to 2016 WHO reclassifies a significant proportion of grade II–IV gliomas.

Multiple independent studies on glioma tissue removed from the brain have conducted genome-wide analyses evaluating an array of molecular features (eg, DNA copy number, DNA methylation, protein expression) in large populations of patients with grade II–IV disease.^{7,9-12} Unsupervised clustering analyses, an unbiased method for identifying molecularly similar tumors, have been used to identify subgroups of gliomas with distinct molecular profiles.^{7,9,10,12} Remarkably, further analysis showed that these molecular subgroups could be distinguished based on only a handful of molecular features, including mutation of *IDH1/2* and 1p19q codeletion, biomarkers independently verified by many studies as hallmarks for distinguishing molecular subgroups in grade II–III gliomas.^{5-8,10,11,13-22} Using these markers alone, the majority of grade II–III tumors can be divided into 3 molecular subtypes: 1) mutation of either *IDH1* or *IDH2* (*IDH*-mut) with 1p19q codeletion (1p19q-codel); 2) *IDH*-mut with no 1p19q codeletion or with isolated deletion of 1p or 19q; and 3) no mutation of *IDH1* or *IDH2* (*IDH*-wt).⁷ Multiple studies have shown that the 1p19q codeletion is strongly associated with *IDH* mutations, such that 1p19q codeletion in *IDH*-wt tumors is rare.^{5,6,18,20,23,24} In a tumor that is equivocal, the presence of an *IDH* mutation indicates at least a grade II diffusely infiltrative glioma.²⁵ Grade I non-infiltrative gliomas do not have *IDH* mutations.²⁵

Correspondingly, beginning with the 2017 version of the NCCN Guidelines, “anaplastic oligodendroglioma” was limited to patients with 1p19q-codeleted tumors, and “anaplastic astrocytoma” to those with 1p19q intact or deletion of only 1p or 19q tumors. “Anaplastic oligoastrocytoma” corresponds to the 2016 WHO category “anaplastic oligoastrocytoma, NOS,” and should include only: 1) patients with mixed histology and no available molecular data (ie, no tissue available for

analysis) for determining whether to classify as oligodendroglioma versus astrocytoma; or 2) rare instances in which the tumor has region(s) with histologic features of oligoastrocytoma with 1p19q codeletion, and distinct region(s) with histologic features of anaplastic astrocytoma and no 1p19q codeletion.³

Other mutations commonly detected in gliomas can have diagnostic and prognostic value, such as mutations in the histone chaperone protein *ATRX*, which can be found in grade II–III gliomas and secondary glioblastomas.^{26,27} *ATRX* loss is robustly associated with *IDH* mutations, and this combination is strongly suggestive of astrocytoma.²⁸ Moreover, *ATRX* loss is nearly always mutually exclusive with 1p/19q codeletion. Therefore, a glioma that has loss of *ATRX* is unlikely to be an oligodendroglioma. Mutations in the telomerase reverse transcriptase (*TERT*) gene occur frequently in glioblastomas and oligodendrogliomas.^{29,30} *TERT* mutations in gliomas are associated with 1p19q codeletion, *IDH* mutations, and amplification of epidermal growth factor receptor (*EGFR*).^{29,30} When coupled with a 1p19q codeletion and an *IDH* mutation, *TERT* mutations are indicative of oligodendroglioma. *H3K27M* mutations are found in diffuse gliomas in both children and adults. These tumors tend to have a midline location, and are classified as grade IV gliomas.³¹ Patients with these *H3K27M* mutated gliomas have a very poor prognosis.³¹

Analyses of large molecular databases have also suggested a number of other molecular markers as being potential characteristic/prognostic features of specific molecular subgroups.^{6,8,10,11,18,23,28} Molecular features suggested as markers for subtyping grade II–III gliomas include: mutations in *NOTCH1*, *CIC*, *FUBP1*; mutation in or overexpression of *TP53*; *PTEN* loss or promoter methylation; loss/deletion of *CDKN2A/B*; amplification of *EGFR*; and chromosome 7 gain, chromosome 10 loss.^{5,7-9,11,19} Due to variability in results across

studies, these molecular markers are not currently widely accepted as useful for classifying gliomas.

Prognostic Relevance of Molecular Subgroups in Glioma

The specific markers used to define molecular subgroups among grade II–III gliomas have been shown to have prognostic value. Numerous large studies of patients with brain tumors have determined that, among grade II–III gliomas, 1p19q-codeletion is significantly correlated with improved progression-free survival (PFS) and overall survival (OS).^{6,10,14,16,20,32–35} For *IDH* mutation status, although a few analyses did not find a significant correlation with PFS,^{6,16} many more studies found that *IDH* mutations were associated with improved survival outcomes in patients with grade II–III glioma, including in several multivariate analyses.^{5–11,16,18,20,23,32–38} Analyses within single treatment arms showed that the *IDH* status is prognostic for outcome across a variety of postoperative adjuvant options. For example, in the NOA-04 phase III randomized trial in newly diagnosed anaplastic gliomas, *IDH* mutation was associated with improved PFS, time to treatment failure (TTF), and OS in each of the 3 treatment arms: standard RT (n = 160); combination therapy with procarbazine, lomustine, and vincristine (PCV; RT upon progression; n = 78); and temozolomide (TMZ; RT upon progression; n = 80).³³

Multiple independent studies have shown that subdividing gliomas by molecular subtype, especially *IDH1/2* and 1p19q status, yields greater prognostic separation than subdivision based on histology (as defined by WHO 2007). These include very large studies covering multiple grades and histology-based subtypes of gliomas,^{7,9,10,32} as well as smaller studies limited to 1 to 2 grades or histologic subtypes.^{6,11,13,37,39} Multiple studies have also shown that, among patients with grade II–III gliomas, the *IDH*-mut+1p19q-codeletion group has the best prognosis, with significantly better PFS and OS than the *IDH*-wt group, which has

the worst prognosis of the three; outcomes for the group with *IDH* mutation and 1p19q intact or deletion of only 1p or 19q usually lie somewhere in between that of the *IDH*-mut+1p19q-codeletion and *IDH*-wt groups.^{6–9,20,32–34} Analyses within single treatment arms have confirmed this trend in prognosis across a variety of postoperative adjuvant treatment options.^{6,33,34,39} *TERT* mutations in patients with high-grade glioma are associated with lower OS, compared to tumors without a *TERT* mutation,³⁰ especially in patients with tumors that are *IDH*-wt.^{8,40} However, a multivariate analysis of data from 291 patients with *IDH*-mut+1p19q-codeleted oligodendrogliomas showed that absence of a *TERT* mutation was associated with worse OS, compared to patients with *TERT*-mutated oligodendrogliomas (HR, 2.72; 95% CI, 1.05–7.04; *P* = .04).⁴¹

MGMT (O-6-methylguanine-DNA methyltransferase) is a DNA repair enzyme that can cause resistance to DNA-alkylating drugs.⁴² MGMT promoter methylation is associated with better survival outcomes in patients with high-grade glioma and is a predictive factor for response to treatment with alkylating chemotherapy such as TMZ or lomustine,^{43,44} even in older adult patients.^{45,46} Tumors with *H3K27M* mutations are less likely to be MGMT promoter methylated³¹ and are associated with worse prognosis.^{47,48} Patients with glioblastomas with *H3F3A* G34 mutations, however, do not have worse prognosis.⁴⁸

About two out of three pilocytic astrocytomas in pediatric patients contain *BRAF* fusions, and gliomas with *BRAF* fusions are rarely high grade.⁴⁹ The likelihood of a *BRAF* fusion in a pilocytic astrocytoma decreases with age.⁴⁹ The *BRAF* V600E mutation is associated with pleomorphic xanthoastrocytomas, though it has also been found in some other pediatric low-grade gliomas, such as gangliogliomas.^{49,50} *BRAF* fusion may be associated with better prognosis in pediatric low-grade astrocytoma.^{49,51,52} Retrospective studies have shown that *BRAF*

V600E may be associated with increased risk of progression in pediatric low-grade gliomas,⁵³ but one study found that this association was not statistically significant ($N = 198$; $P = .07$).⁵² Some studies have shown that tumors with a *BRAF* V600E mutation may respond to BRAF inhibitors such as vemurafenib,^{54,55} but ongoing studies will further clarify targeted treatment options in the presence of a *BRAF* fusion or mutation (eg, NCT03224767, NCT03430947). *BRAF* fusion and/or mutation testing may be considered as clinically indicated in patients with low-grade glioma.

NCCN Molecular Testing Recommendations for Glioma

Recommendations for molecular testing of glioma tumors are provided in the *Principles of Brain Tumor Pathology* section of the NCCN Guidelines for Central Nervous System Cancers. Based on studies showing that *IDH* status is associated with better prognosis in patients with grade II–III glioma,^{23,32,33,36} the panel recommends *IDH* mutation testing in patients with glioma. Patients with oligodendroglioma should also undergo 1p19q testing. However, since 1p19q codeletion is strongly associated with *IDH* mutation,^{20,23,24} 1p19q testing is not necessary in tumors that are *IDH*-wt, and tumors without an *IDH* mutation should not be regarded as 1p/19q codeleted, despite testing results indicating otherwise. Mutation testing for *ATRX* and *TERT* are also recommended, given the diagnostic value of these mutations.^{26,28-30} Testing for *H3F3A* mutations and *BRAF* fusion and/or mutation testing may be carried out as clinically indicated.

Grade III–IV gliomas should undergo testing for MGMT promoter methylation, since MGMT promoter-methylated tumors may respond better to alkylating chemotherapy, compared to unmethylated tumors.^{43,45,46} To date, there are no targeted agents that have shown efficacy in the treatment of glioblastoma. Nevertheless, molecular testing of glioblastoma tumors is still encouraged by the panel, as

patients with a detected driver mutation may be treated with a targeted therapy on a compassionate use basis. Detection of a mutation could also increase clinical trial options.

Low-Grade Infiltrative Astrocytomas and Oligodendrogliomas

Diffusely infiltrative low-grade gliomas (ie, astrocytomas, oligodendrogliomas) are a diverse group of relatively uncommon malignancies classified as grade II under the WHO grading system.³ Factors prognostic for PFS or OS in patients with grade II gliomas include age, tumor diameter, tumor crossing midline, neurologic or PS prior to surgery, and the presence of certain molecular markers (see section above on *Molecular Profiling for Gliomas*).^{6,16,56-63} Seizure is a common symptom (81%) of low-grade gliomas, and is more frequently associated with oligodendrogliomas.⁶⁴ The median duration from onset of symptoms to diagnosis ranges from 6 to 17 months.

Diffuse astrocytomas are poorly circumscribed and invasive, and most gradually evolve into higher-grade astrocytomas. Although these were traditionally considered benign, they can behave aggressively and will undergo anaplastic transformation within 5 years in approximately half of patients.^{65,66} The most common non-infiltrative astrocytomas are pilocytic astrocytomas, which are circumscribed, often surgically resectable, and rarely transform. However, the NCCN algorithm currently does not encompass pilocytic astrocytomas because these tumors are curable by surgery alone.

Oligodendrogliomas are thought to arise from oligodendrocytes. Radiographically, low-grade oligodendrogliomas appear well demarcated, occasionally contain calcifications, and do not enhance with contrast. The typical “fried egg” appearance of these tumors is evident in paraffin but not in frozen sections. Grade II

oligodendrogliomas have a much better 5-year survival rate (70%) than mixed gliomas (56%) and astrocytomas (37%).⁶⁷

Treatment Overview

Surgery

Surgery remains an important diagnostic and therapeutic modality. The primary surgical goal is to provide adequate tissue for a pathologic diagnosis and grading. Needle biopsies are often performed when lesions are in deep or critical regions of the brain. Biopsy results can be misleading, because gliomas often have varying degrees of cellularity, mitoses, or necrosis from one region to another; thus, small samples can provide a lower histologic grade.

The role of maximal tumor resection in low-grade astrocytomas remains unresolved. Because these tumors are relatively uncommon, published series generally include patients treated for decades, which introduces additional variables. For example, the completeness of surgical excision was based on the surgeon's report in older studies. This approach is relatively unreliable when compared with assessment by modern postoperative imaging studies. Furthermore, most patients also received RT, and thus the net effect of the surgical procedure on outcome is difficult to evaluate. Multivariate analyses from a number of studies in patients with primary low-grade gliomas show that extent of resection is a significant prognostic factor for PFS and/or OS.^{58-63,68-72}

Maximal safe resection may also delay or prevent malignant progression⁷³⁻⁷⁵ and recurrence.⁷⁶ Patients who undergo an STR, open biopsy, or stereotactic biopsy are, therefore, considered to be at higher risk for progression.

Biological considerations also favor an attempt at a complete excision of an astrocytoma. First, the tumor may contain higher-grade foci, which

may not be reflected in a small specimen. Second, complete excision may decrease the risk of future dedifferentiation to a more malignant astrocytoma.⁷³ Third, a large tumor burden is removed, which also may enhance the effect of RT. As a result of these considerations, the general recommendation for treating an astrocytoma is to first attempt as complete an excision of tumor as possible (based on postsurgical MRI verification) without compromising function. Low-grade oligodendrogliomas are often amenable to total excision due to their location in the frontal lobes and distinct tumor margins. However, for tumors that involve eloquent areas, a total removal may not be feasible and an aggressive approach could result in neurologic deficits.

Adjuvant Therapy

A large meta-analysis, including data from phase 3 trials (EORTC 22844 and 22845,^{58,77} and NCCTG 86-72-51⁶⁰), confirmed that surgery followed by RT significantly improves PFS but not OS in patients with low-grade gliomas.⁷⁸ Early versus late postoperative RT did not significantly affect OS, however, suggesting that observation is a reasonable option for some patients with newly diagnosed gliomas.⁷⁷

Final results of a phase 3 randomized clinical trial, RTOG 9802, which assessed the efficacy of adjuvant RT versus RT followed by 6 cycles of PCV in patients with newly diagnosed supratentorial WHO grade II gliomas and at least one of 2 risk factors for disease progression (STR or age ≥ 40 years)⁷⁹ showed significant improvements in both PFS and OS with the addition of PCV.⁸⁰ The median survival time increased from 7.8 years to 13.3 years ($P = .02$), and the 10-year survival rate increased from 41% to 62%. It is important to note, however, that roughly three-quarters of the study participants had a Karnofsky Performance Status (KPS) score of 90 to 100, and the median age was around 40 years.⁷⁹ Exploratory analyses based on histologic subgroups showed a statistically significant improvement in OS for all subgroups

except for patients with astrocytoma.⁸⁰ Given that the study participants treated with PCV after RT experienced a significantly higher incidence of grade 3 or 4 adverse events (specifically neutropenia, gastrointestinal disorder, and fatigue),^{79,80} PCV may be difficult to tolerate in patients who are older or with poor PS.

Combined treatment with RT plus TMZ is supported by a phase 2 multicenter trial (RTOG 0424) in patients with supratentorial WHO grade II tumors and additional risk factors (age ≥ 40 years, astrocytoma, bi-hemispherical, tumor diameter ≥ 6 cm, neurologic function status > 1).⁸¹ However, since the historical controls included patients treated in an earlier time period using different RT protocols, prospective controlled trials are needed to determine whether treatment with TMZ concurrently and following RT is as efficacious as PCV following radiation. There are currently no phase III data to support the use of RT and TMZ over RT and PCV for the treatment of patients with newly diagnosed high-risk low-grade glioma. The phase 3 randomized EORTC 22033-26033 trial showed that PFS is not significantly different for adjuvant RT versus dose-dense TMZ in patients with resected or biopsied supratentorial grade II glioma and more than one risk factor (N = 477).¹⁷ However, analyses of OS have not yet been reported for this trial.

Radiation Therapy

When RT is given to patients with low-grade gliomas, it is administered with restricted margins. A T2-weighted and/or fluid-attenuated inversion recovery (FLAIR) MRI scan is the best means for evaluating tumor extent, because these tumors enhance weakly or not at all. The clinical target volume (CTV) is defined by the FLAIR or T2-weighted tumor with a 1- to 2-cm margin. Every attempt should be made to decrease the RT dose outside the target volume. This can be achieved with 3-dimensional planning or intensity-modulated RT (IMRT). The recommended dosing for postoperative RT is based on results from two

phase 3 randomized trials showing that higher dose RT had no significant effect on OS or time to progression,^{58,60} and several retrospective analyses showing similar results.^{59,61,82} Because higher doses offer no clear advantages, the CNS Panel recommends low-dose RT (45–54 Gy) for treatment of low-grade gliomas (Grades I/II), including high-risk cases. However, whole genome sequencing analysis of 1,122 diffuse grade II-IV gliomas showed that low-grade gliomas that are *IDH*-wt may have similar survival outcomes compared to glioblastomas that are *IDH*-wt.⁸³ Therefore, an RT dose of 59.4 to 60 Gy may be considered for this subset of patients with low-grade glioma.

Recurrent or Progressive Disease

Data from phase II trials inform recommendations for chemotherapy treatment of patients with recurrent or progressive low-grade glioma.⁸⁴⁻⁸⁸ There are very little data to inform treatment of patients with recurrent or progressive low-grade glioma who have not had prior RT treatment, as most of the studies of recurrent or progressive low-grade gliomas include those who have had prior RT. Results of the RTOG 9802 trial^{79,80} support use of RT with chemotherapy for these patients.

NCCN Recommendations

Primary and Adjuvant Treatment

When possible, maximal safe resection is recommended for low-grade infiltrative astrocytomas and oligodendrogliomas,^{89,90} and the actual extent of resection should be documented with a T2-weighted or FLAIR MRI scan within 72 hours after surgery.

For treatment recommendations for newly diagnosed low-grade gliomas, the panel used the RTOG 9802^{79,80} criteria for determining if a patient is considered to be at low or high risk for tumor progression: patients are categorized as being at low risk if they are 40 years or

younger and underwent a GTR; high-risk patients are >40 years of age and/or underwent a subtotal resection. However, the panel acknowledges that other prognostic factors have been used to guide adjuvant treatment choice in other studies of patients with low-grade glioma,⁹⁰ such as tumor size, presence of neurologic deficits, or the *IDH* mutation status of the tumor.^{17,56} In the event that these other risk factors are considered, and treatment of a patient is warranted, the panel recommends that the patient be treated as high risk.

Patients with low-risk and low-grade glioma may be observed following surgery. Close follow-up is essential as over half of these patients will develop tumor progression within five years.⁶³ Following surgery, the panel recommends that patients with low-grade glioma who are considered to be at high risk for tumor progression be treated with RT followed by PCV. This category 1 recommendation is based on the practice-changing results from the RTOG 9802 study,^{79,80} as discussed above. Panel members are divided regarding endorsement of the treatment options of RT + adjuvant TMZ or RT + concurrent and adjuvant TMZ (both category 2B recommendations) due to the lack of prospective randomized phase 3 data for the use of radiation and TMZ in patients with low-grade glioma. Because PCV is generally a more difficult chemotherapy regimen to tolerate than TMZ, it may be reasonable to treat an elderly patient or a patient with multiple comorbidities with RT and TMZ instead of RT and PCV, but there are currently no data to show that doing so would result in similar improvement in OS. Since the design of RTOG 9802^{79,80} did not address whether all patients should be treated with RT followed by PCV immediately after a tissue diagnosis (an observation arm was not included in the study), observation after tissue diagnosis may be a reasonable option for some patients with high-risk low-grade glioma who are neurologically asymptomatic or who have stable disease.

However, close monitoring of such patients with brain MRIs is important.

Recurrence

At the time of recurrence, surgery is recommended if resectable disease is present. Because recurrence on neuroimaging may be confounded by treatment effects, biopsy of unresectable disease should be considered to confirm recurrence. There is a propensity for low-grade gliomas to undergo transformation to higher grade gliomas over time. Therefore, documenting histopathologically the transformation of a grade II glioma to a grade III or IV glioma may also enable patients to have clinical trial opportunities, since most clinical trials in the recurrent setting are for patients with high-grade gliomas. Moreover, sampling of tumor tissue to confirm recurrence is encouraged to obtain tissue for next-generation sequencing, the results of which may inform treatment selection and/or clinical trial eligibility.

Surgery for recurrent disease may be followed by chemotherapy if patients have previously had fractionated EBRT. At progression following chemotherapy, the options are: 1) a different chemotherapy regimen; 2) consider reirradiation; and 3) palliative/best supportive care. Reirradiation is a good choice if the patient had been progression-free for over 2 years after prior RT, the new lesion is outside the target of previous RT, or the recurrence is small and geometrically favorable.

Based on the strength of the RTOG 9802 results,^{79,80} RT with chemotherapy is a treatment option for patients with recurrent or progressive low-grade gliomas who have not had prior RT. Options include RT + adjuvant PCV, RT + adjuvant TMZ, and RT + concurrent and adjuvant TMZ. RT alone is generally not the preferred treatment option except in select cases, such as a patient with a poor PS, or who does not want to undergo chemotherapy treatment.

Anaplastic Gliomas and Glioblastomas

High-grade gliomas are the most common type of brain cancer, accounting for more than half of all malignant primary tumors of the brain and CNS.⁹¹ Whereas the prognosis for glioblastoma (grade IV glioma) is grim (5-year survival rates between 1%–19%, depending on age), outcomes for anaplastic gliomas (grade III gliomas) are typically better, depending on the molecular features.⁹¹

High-grade astrocytomas diffusely infiltrate surrounding tissues and frequently cross the midline to involve the contralateral brain. Patients with these neoplasms often present with symptoms of increased intracranial pressure, seizures, or focal neurologic findings related to the size and location of the tumor and associated vasogenic edema. These tumors usually do not have associated hemorrhage or calcification but produce considerable edema and mass effect and enhance after the administration of intravenous contrast. Tumor cells have been found in the peritumoral edema, which corresponds to the T2-weighted MRI abnormalities. As a result, this volume is frequently used to define RT portals.

It can be difficult to assess the results of therapy by MRI scans, because the extent and distribution of contrast enhancement, edema, and mass effect are a function of blood-brain barrier (BBB) integrity. Thus, other factors that increase permeability of the BBB (such as surgery, RT, and tapering of corticosteroids) can mimic tumor progression radiographically by increasing the presence of contrast enhancement and associated vasogenic edema.

Treatment Overview

Surgery

The goals of surgery are to obtain a diagnosis, alleviate symptoms related to increased intracranial pressure or compression, increase survival, and decrease the need for corticosteroids. A prospective study of 565 patients with malignant glioma showed that aggressive surgery is a strong prognostic factor when compared with biopsy alone ($P < .001$).⁹² Retrospective analyses also suggest that GTR lengthens survival and is especially effective in patients with good PS.⁹³⁻⁹⁵ Unfortunately, the infiltrative nature of high-grade astrocytomas frequently renders GTR difficult. On the other hand, GTR is often possible for oligodendrogliomas, because most occur in the frontal lobes, and the tumors are frequently well demarcated.

Unfortunately, nearly all high-grade gliomas recur. At recurrence, reoperation may improve the outcome for select patients.⁹⁶ According to an analysis by Park et al,⁹⁷ tumor involvement in specific critical brain areas, poor KPS score, and large tumor volume were associated with unfavorable re-resection outcomes.

Radiation Therapy

Conformal RT techniques including 3-dimensional conformal RT and IMRT partial brain irradiation are recommended. Several randomized controlled trials conducted in the 1970s showed that radiation improved both local control and survival in patients with newly diagnosed high-grade gliomas.^{98,99} Sufficient radiation doses are required to maximize this survival benefit. However, radiation dose escalation alone above 60 Gy has not been shown to be beneficial.¹⁰⁰ The recommended radiation dose for high-grade astrocytomas are 60 Gy in 2.0 Gy fractions with an initial RT plan to 46 Gy in 2 Gy/fraction followed by a boost plan of 14 Gy in 2 Gy/fraction.¹⁰⁰

Anaplastic oligodendrogliomas are conventionally treated to a similar dose. Given the improved prognosis in these patients, radiation treatments are generally administered in a lower dose per fraction (1.8 Gy/fraction vs. 2.0 Gy/fraction) to theoretically decrease the risk of late side effects. Accordingly, as per recent trials such as RTOG 9813,³⁶ these gliomas are treated to 50.4 Gy in 1.8 Gy fractions for 28 fractions followed by a five-fraction boost of 1.8 Gy/fraction to a total of 59.4 Gy. Proton therapy has also been used to reduce long-term toxicity including neurocognitive dysfunction.¹⁰¹

RT targets for high-grade gliomas are generated from a gross tumor volume (GTV), CTV, and planning target volume (PTV). The GTV encompasses any gross tumor remaining after maximal safe resection as well as the surgical cavity as determined by postoperative imaging. The CTV is an expansion on the GTV to account for subclinical disease and this is then expanded to a PTV to account for setup error. Strategies for GTV definition vary with respect to the inclusion of edema in an initial target volume. When edema is included in an initial phase of treatment, fields are usually reduced for the last phase of treatment. The boost target volume will typically encompass only the gross residual tumor and the resection cavity. There is a range of acceptable clinical target volume margins. Both strategies appear to produce similar outcomes.¹⁰⁰

Special attention has been given to determine the optimal therapy in older adults, given their especially poor prognosis and limited functional status. Overall, the approach in these patients has been to reduce treatment time while attempting to maintain treatment efficacy. Roa et al randomized patients 60 years or older with a poor PS (KPS < 70) to 60 Gy given over 6 weeks versus 40 Gy given over 3 weeks and found no difference in survival between these two regimens.¹⁰² Subsequent studies in older adult patients have confirmed dose-fractionation

regimens of 40 Gy in 15 fractions and 34 Gy in 10 fractions, all showing non-inferiority compared to the standard 60 Gy regimen.⁴⁵ Interestingly, more recent data from Roa et al suggest that an even more hypofractionated regimen of 25 Gy in 5 fractions may be no less inferior to the previously mentioned hypofractionated regimen (40 Gy in 15 fractions) in a particularly poor prognosis subgroup of patients.¹⁰³

The EORTC 26062-22061/NCIC CTG randomized trial of hypofractionated RT with concurrent and adjuvant TMZ versus hypofractionated RT regimen alone in older adult patients showed an improvement in OS and PFS with the addition of concurrent and adjuvant TMZ.¹⁰⁴ The largest benefit was noted in patients with MGMT promoter methylation. Ultimately, quality of life remains an important consideration in the optimal management of this patient population.

Systemic Therapy

Anaplastic Oligodendroglioma

Anaplastic oligodendrogliomas are relatively rare; they are characterized by high cellularity, nuclear pleomorphism, frequent mitosis, endothelial proliferation, and necrosis, and have a distinct molecular signature. While these tumors can be confused with glioblastoma histopathologically, if molecular analysis detects that the tumor is 1p19q codeleted and IDH 1 or 2 mutated, then the tumor is an anaplastic oligodendroglioma.³ This distinct subtype has a much better prognosis compared to other high-grade gliomas (anaplastic astrocytomas and glioblastomas). In the revised 2016 WHO Classification of Tumors of the CNS,³ oligoastrocytoma is no longer a valid diagnosis; however, “oligoastrocytoma, NOS” may continue to be used if a tumor has features of mixed histology and molecular testing is not possible or in the rare instance that the tumor has distinct histologic

regions of oligodendroglioma that are 1p19q codeleted and astrocytoma that are not 1p19q codeleted.³

The addition of PCV to RT for the treatment of newly diagnosed anaplastic oligodendrogliomas is supported by results from two phase III trials, one which tested RT followed by PCV for 6 cycles (EORTC 26951^{105,106}) and the other which assessed 4 cycles of dose-intensive PCV administered prior to RT (RTOG 9402^{34,107,108}). Both studies compared the combination therapy to RT alone, and found significant increases in median OS when PCV was added to RT for the upfront management of 1p19q codeleted tumors.

The EORTC 26951 trial showed that, among the entire group of 368 histopathologically diagnosed study patients with anaplastic oligodendroglioma or anaplastic oligoastrocytoma, RT followed by 6 cycles of PCV significantly improved median PFS and OS (42.3 vs. 30.6 months; HR, 0.75; 95% CI, 0.60–0.95; $P = .018$) compared with RT alone.¹⁰⁶ Moreover, in an exploratory subgroup analysis of the 80 patients whose tumors were 1p19q codeleted, the benefit was even more pronounced (OS not reached in the RT + PCV group vs. 112 months in the RT group; HR, 0.56; 95% CI, 0.31–1.03).^{23,105,106}

RTOG 9402 randomized 291 patients with histopathologically diagnosed anaplastic oligodendroglioma or anaplastic oligoastrocytoma to PCV followed by immediate RT or RT alone.¹⁰⁸ In contrast to the EORTC 26951 study, no difference in median OS was observed between the two arms (4.6 years vs. 4.7 years; HR, 0.79; 95% CI, 0.60–1.04; $P = .10$). However, an unplanned subgroup analysis of the 126 patients whose tumors were 1p19q co-deleted found a doubling in median OS (14.7 vs. 7.3 years; HR, 0.59; 95% CI, 0.37–0.95; $P = .03$) when PCV was added to RT as upfront treatment.

As would be predicted, in both studies, toxicity was higher in the treatment arms that included PCV. In EORTC 26951, 70% of patients in the RT followed by PCV arm did not complete the planned 6 cycles of treatment.^{105,106} In RTOG 9402, there was also a high rate of study treatment discontinuation and acute toxicities (mainly hematologic), including 2 early deaths attributed to PCV-induced neutropenia in the intense PCV arm followed by RT.^{107,108}

The phase III CODEL study was designed to assess the efficacy of TMZ for the treatment of newly diagnosed anaplastic oligodendrogliomas. The initial treatment arms were RT alone, RT + TMZ, and TMZ alone.¹⁰⁹ However, when the results of RTOG 9402 and EORTC 26951 were reported showing significant improvement in median OS with RT + PCV upfront, The CODEL study was redesigned to compare RT + PCV to RT + TMZ in patients with anaplastic oligodendroglioma as well as low-grade oligodendroglioma. This study is ongoing.

Anaplastic Astrocytoma

The RTOG 9813 trial showed that RT with concurrent TMZ results in similar outcomes as RT with concurrent nitrosourea in patients with newly diagnosed anaplastic astrocytomas, with perhaps slightly better PFS with TMZ (HR, 0.70; 95% CI, 0.50–0.98; $P = .039$).³⁶ The toxicity of nitrosourea was far worse than for TMZ, and resulted in higher rates of discontinuation due to toxicity (79% vs. 40%, respectively; $P < .001$). The ongoing CATNON phase 3 randomized trial is testing RT alone, as well as RT with adjuvant TMZ, concurrent TMZ, or both, in patients with anaplastic astrocytoma. A recently published interim analysis showed adjuvant TMZ significantly improved PFS (HR, 0.62; 95% CI, 0.50–0.76) and OS (HR, 0.67; 95% CI, 0.51–0.88).¹¹⁰ Median OS for the group of patients treated with post-RT TMZ had not been reached, but median OS at 5 years was 55.9% (95% CI, 47.2–63.8) with and 44.1% (36.3–

51.6) without adjuvant TMZ. Further follow-up is needed to determine whether TMZ concurrent with RT provides any clinical benefit and which of the 3 RT + TMZ combination regimens provides the best outcomes.

Glioblastoma

TMZ is recommended in conjunction with postoperative RT for patients with glioblastoma and good PS. Stupp et al¹¹¹ conducted the phase III, randomized EORTC-NCIC study that assessed the drug in 573 patients with glioblastoma with age ≤70 years with a WHO PS of 2 or less. Patients received either 1) daily TMZ administered concomitantly with postoperative RT followed by 6 cycles of adjuvant TMZ; or 2) RT alone. The chemoradiation arm resulted in a statistically better median survival (14.6 vs. 12.1 months) and 2-year survival (26.5% vs. 10.4%) when compared with RT. Final analysis confirmed the survival advantage at 5 years (10% vs. 2%).¹⁰⁴ However, the study design does not shed light on which component is responsible for the improvement: TMZ administered with RT, TMZ following RT, or possibly both.

The TMZ dose used in the EORTC-NCIC trial is 75 mg/m² daily concurrent with RT, then 150 to 200 mg/m² post-irradiation on a 5-day schedule every 28 days. Alternate schedules such as a 21/28 dose-dense regimen or a 50 mg/m² continuous daily schedule have been explored in a phase II trial for newly diagnosed glioblastoma.¹¹² However, a comparison of the dose-dense 21/28 and standard 5/28 schedules in the RTOG 0525 phase III study showed no difference in PFS, OS, or by MGMT methylation status with the post-radiation dose-dense TMZ, compared to the standard post-radiation TMZ dose.¹¹³ A pooled analysis of individual patient data from 4 randomized trials^{111,113-115} of patients with newly diagnosed glioblastoma determined that treating with post-radiation TMZ beyond 6 cycles does not improve OS, even for patients whose tumors are MGMT promoter methylated.¹¹⁶

For older adults with newly diagnosed glioblastoma, building on the findings that hypofractionated RT alone has similar efficacy and is better tolerated compared to standard RT alone, a phase III randomized trial with 562 newly diagnosed patients 65 years of age or older compared hypofractionated RT with concurrent and adjuvant TMZ to hypofractionated radiation alone. Patients in the combination therapy arm had greater PFS (5.3 months vs. 3.9 months; HR, 0.50; 95% CI, 0.41–0.60; $P < .001$) and median OS (9.3 months vs. 7.6 months; HR, 0.67; 95% CI, 0.56–0.80; $P < .001$) compared to patients treated with hypofractionated RT alone.¹¹⁷ The greatest improvement in median OS was seen in patients with MGMT promoter-methylated tumors (13.5 months RT + TMZ vs. 7.7 months RT alone; HR, 0.53; 95% CI, 0.38–0.73; $P < .001$). The benefit of adding TMZ to RT was smaller in patients with MGMT promoter-unmethylated tumors and did not quite reach statistical significance (10.0 months vs. 7.9 months, respectively; HR, 0.75; 95% CI, 0.56–1.01; $P = .055$; $P = .08$ for interaction).

Two phase III studies in elderly newly diagnosed glioblastoma patients assessed treatment with TMZ alone versus radiation.^{45,46} The Nordic trial randomized 291 patients aged 60 years and older with good PS across 3 treatment groups: TMZ, hypofractionated RT, or standard RT.⁴⁵ Patients older than 70 years had better survival with TMZ or hypofractionated RT compared to standard RT, and patients whose tumors were MGMT promoter-methylated benefitted more from treatment with TMZ compared to patients with MGMT promoter-unmethylated tumors (median OS 9.7 vs. 6.8 months; HR, 0.56; 95% CI, 0.34–0.93; $P = .02$). The NOA-08 study assessed the efficacy of TMZ alone compared to standard RT in 373 patients aged 65 years and older.⁴⁶ TMZ was found to be non-inferior to standard RT: median OS was similar in both groups (8.6 months in the TMZ arm vs. 9.6 months in the standard RT arm; HR, 1.09, 95% CI, 0.84–1.42; P (non-inferiority)

= .033). For patients whose tumors were MGMT promoter methylated, event-free survival was longer with TMZ treatment compared to standard RT (8.4 months vs. 4.6 months). Although radiation in combination with TMZ may be recommended over single-modality therapy for newly diagnosed patients with glioblastoma who are older than 70 years of age and have good PS, the results of two phase III studies support the recommendation that TMZ alone as initial therapy may be a reasonable option for those elderly patients who have MGMT promoter-methylated tumors and would initially prefer to delay treatment with radiation.^{45,46}

Alternating Electric Field Therapy

In 2015, the FDA approved alternating electric field therapy for the treatment of newly diagnosed glioblastoma based on the results of the phase 3 EF-14 clinical trial. This portable medical device generates low-intensity alternating electric fields to stop mitosis/cell division. In the EF-14 trial, 695 patients with newly diagnosed glioblastoma were randomized to TMZ alone on a 5/28 day schedule or the same TMZ and alternating electric field therapy, following completion of standard focal brain radiation and daily TMZ.¹¹⁸ The results of the study showed an improvement in median PFS (6.7 vs. 4.0 months, respectively; HR, 0.63; 95% CI, 0.52–0.76; $P < .001$) and OS (20.9 vs. 16.0 months, respectively; HR, 0.63; 95% CI, 0.53–0.76; $P < .001$) in patients who received TMZ plus alternating electric field therapy.¹¹⁹ The number of adverse events was not statistically different between the two treatment groups except for a greater frequency of mild to moderate local skin irritation/itchiness in the patients treated with the alternating electric fields.¹²⁰ There was no increased frequency of seizures.^{121,122}

Therapy for Recurrence

Patients with malignant gliomas eventually recur or progress. Unfortunately, there is no established second-line therapy for recurrent

gliomas. If there has been a long interval of time between stopping temozolomide and tumor progression, it is reasonable to restart a patient on temozolomide,¹²³ particularly if the patient's tumor is MGMT methylated. Similarly, a nitrosourea, such as carmustine or lomustine,¹²⁴⁻¹²⁷ would be a reasonable second-line therapy, especially in a patient whose tumor is MGMT methylated. Although no studies of bevacizumab in patients with recurrent glioblastoma have demonstrated an improvement in survival, bevacizumab is FDA approved for the treatment of recurrent glioblastoma based on improvement in PFS.^{128,129} Of note, improvement in PFS may be due to bevacizumab's ability to decrease BBB permeability (resulting in less contrast enhancement and vasogenic edema) rather than a true anti-tumor effect.¹³⁰

Other routes of chemotherapy delivery have been evaluated. Local administration of carmustine using a biodegradable polymer (wafer) placed intraoperatively in the surgical cavity has demonstrated a statistically significant improvement in survival for patients with recurrent high-grade gliomas (31 vs. 23 weeks; adjusted HR, 0.67; $P = .006$).¹³¹ Clinicians and patients should be aware that treatment with the carmustine wafer may prevent participation in a clinical trial involving a locally delivered investigational agent.

Alternating electric field therapy is also FDA approved for treating recurrent glioblastoma based on the safety results of this medical device from the EF-11 clinical trial.¹³² This phase III study randomized 237 patients with recurrent glioblastoma to alternating electric field therapy or the treating oncologist's choice of chemotherapy. The study did not meet its primary endpoint of demonstrating an improvement in survival in the cohort of patients treated with alternating electric field therapy. Although median OS was similar in both of the treatment arms (6.6 vs. 6 months), the study had not been powered for non-inferiority determination. Due to lack of clear efficacy data for alternating electric

field therapy in EF-11, the panel is divided about recommending it for the treatment of recurrent glioblastoma.

To improve local control in patients with local recurrence, re-irradiation is an option.

NCCN Recommendations

Primary Treatment

When a patient presents with a clinical and radiologic picture suggestive of high-grade glioma, neurosurgical input is needed regarding the feasibility of maximal safe tumor resection. For first-line treatment of high-grade glioma, the NCCN Guidelines recommend maximal safe resection whenever possible. One exception is when CNS lymphoma is suspected; a biopsy should be performed first and management should follow the corresponding pathway if the diagnosis is confirmed. When maximal resection is performed, the extent of tumor debulking should be documented with a postoperative MRI scan with and without contrast performed within 72 hours after surgery. Multidisciplinary consultation is encouraged once the pathology is available.

Adjuvant Therapy

RT, unless PS precludes treatment, is uniformly indicated after maximal safe resection in the treatment of high-grade gliomas to improve local control and survival. For postoperative treatment of anaplastic gliomas in patients with good PS (KPS \geq 60), combination therapy with fractionated EBRT combined with PCV or TMZ are among the recommended options. For patients with 1p/19q co-deleted anaplastic oligodendroglioma, fractionated EBRT plus PCV, given before or after RT, is a category 1 recommendation, based on the results of the RTOG 9402^{34,108} and EORTC 26951 studies.^{105,106} The panel advises administering PCV after RT as per EORTC 26951 instead of the dose-

intensive PCV used prior to RT in the RTOG 9402 study¹⁰⁸ due to better patient tolerance. Fractionated RT plus concurrent and adjuvant TMZ is also recommended, particularly if it is predicted that the patient might have significant difficulty tolerating PCV due to age or coexisting medical conditions.

In the case of anaplastic astrocytoma and anaplastic oligoastrocytoma (not otherwise specified; NOS) with good PS, fractionated RT followed by adjuvant TMZ is recommended based on the interim analysis results of the CATNON trial showing improvement in survival of RT followed by 12 cycles of TMZ compared to RT alone.¹¹⁰ Other acceptable treatment options include fractionated RT with concurrent and adjuvant temozolomide or fractionated RT and PCV.¹¹⁰

For patients with anaplastic gliomas and a poor PS (KPS < 60), treatment options recommended in the NCCN Guidelines are limited to single-modality therapies due to concerns about the ability of these patients to tolerate the toxicity associated with combination regimens. Patients with a poor PS can be managed by RT (hypofractionation is preferred over standard fractionation), TMZ alone (considered for tumors that are MGMT promoter methylated), or palliative/best supportive care. TMZ alone is a category 2B option for these patients.

For patients diagnosed with glioblastoma, the adjuvant options mainly depend on the patient PS (as defined by KPS), age, and MGMT promoter methylation status.^{45,104,133,134} Category 1 recommendations for patients aged 70 years or younger with a good PS, regardless of the tumor's MGMT methylation status, include fractionated standard brain RT plus concurrent and adjuvant TMZ with or without alternating electric field therapy. Since patients with newly diagnosed glioblastoma whose MGMT promoter-unmethylated tumors are likely to experience less clinical benefit from treatment with TMZ, RT alone is included as a

reasonable option, particularly if the patient is eligible to participate in a clinical trial, which omits the use of upfront TMZ.

Category 1 treatment recommendations for patients older than 70 years of age with newly diagnosed glioblastoma, a good PS, and MGMT promoter-methylated tumors include hypofractionated brain RT plus concurrent and adjuvant TMZ¹¹⁷ or standard brain RT plus concurrent and adjuvant TMZ and alternating electric field therapy. For those patients older than age 70 with newly diagnosed glioblastoma, a good PS, and with MGMT unmethylated or indeterminant tumors, standard brain RT plus concurrent and adjuvant TMZ and alternating electric field therapy is a category 1 option.^{118,119} The complete list of recommendations that the panel did not consider category 1 can be found in the treatment algorithms for patients with glioblastoma who are older than age 70.

Treatment recommendations for patients with newly diagnosed glioblastoma and KPS below 60 (regardless of age) include hypofractionated brain RT (preferred for patients who are age 70 or younger, possibly with concurrent and adjuvant TMZ), TMZ alone (for MGMT promoter-methylated tumors), or palliative/best supportive care.

Follow-up and Recurrence

Patients should be followed closely with serial brain MRI scans (at 2–6 weeks post-irradiation, then every 2–4 months for 3 years, then every 6 months indefinitely) after the completion of RT. Because RT can produce additional BBB dysfunction, scans may appear worse during the first 3 months after completion of RT even though there may be no actual tumor progression. Early MRI scans allow for appropriate titration of corticosteroid doses, based on the extent of mass effect and brain edema. Later scans are used to identify tumor recurrence. Early detection of recurrence is warranted, because local and systemic

treatment options are available for patients with recurrent disease. Biopsy, MR spectroscopy, MR perfusion, or brain PET/CT can be considered to try to determine if the changes seen on brain MRI are due to RT-induced necrosis or “pseudoprogression” versus actual disease progression.^{135,136}

Management of recurrent tumors depends on the extent of disease and patient condition. The efficacy of current treatment options for recurrent disease remains poor; therefore, enrollment in a clinical trial, whenever possible, is preferred for management of recurrent disease. A patient with a poor PS should receive palliative/best supportive care without further active treatment.

Intracranial and Spinal Ependymomas

Ependymomas constitute up to 4% of adult CNS tumors and 10% of pediatric CNS tumors.¹³⁷ In adults, ependymomas occur more often in the spinal canal than in the intracranial compartment (two-thirds infratentorial). These tumors can cause hydrocephalus and increased intracranial pressure, mimic brainstem lesions, cause multiple cranial nerve palsies, produce localizing cerebellar deficits, and cause neck stiffness and head tilt if they infiltrate the upper portion of the cervical cord.^{138,139} This section focuses on adult intracranial and spinal grade II differentiated (termed ependymomas) and grade III (termed anaplastic ependymomas) ependymomas. Grade I ependymomas (subependymomas and myxopapillary) are non-infiltrative and can be cured by resection alone.

Treatment Overview

Surgery

There is a paucity of robust studies regarding this uncommon disease, but multiple case series have reported that patients with totally resected tumors tend to have the best survival for both low- and high-grade ependymomas.¹⁴⁰⁻¹⁴⁴ Supratentorial ependymomas generally have a poorer prognosis than their infratentorial counterparts, because a greater proportion of supratentorial lesions are of high grade and because larger volumes of residual disease tend to be present after surgical resection at this location.

Radiation Therapy

The survival benefits of RT following surgical recovery have been established for anaplastic ependymomas and suboptimally resected tumors, although much of the data are derived from pediatric patients. Rodriguez et al¹⁴⁵ reviewed over 2400 cases of ependymomas in the SEER database and reported the lack of RT to be a poor prognostic

factor in partially resected patients (HR = 1.75; $P = .024$). The short-term and 10-year survival rate after RT reached over 70% and 50%, respectively.¹⁴⁶⁻¹⁴⁸ The value of RT is more controversial for differentiated ependymomas,^{141,149} with data demonstrating improved survival mainly for subtotally resected tumors.^{142,145}

In the past, the standard practice was to irradiate the entire craniospinal axis or administer WBRT. However, studies have demonstrated that: 1) local recurrence is the primary pattern of failure; 2) spinal seeding is uncommon in the absence of local failure; 3) the patterns of failure are similar in patients with high-grade tumors who are treated with local fields or craniospinal axis irradiation; and 4) spinal metastases may not be prevented by prophylactic treatment.¹⁵⁰⁻¹⁵² Prophylactic craniospinal or WBRT does not lead to improvement in survival compared to conformal regional RT with higher doses in modern studies of non-disseminated disease.^{143,149,153} Typical craniospinal irradiation scheme includes 36 Gy in 1.8 Gy fractions to the whole brain and spine, followed by limited field irradiation to spine lesions to 45 Gy. For intracranial ependymomas, the primary brain site should receive a total of 54 to 59.4 Gy in 1.8 to 2.0 Gy fractions. For spinal ependymomas, patients should receive 45 to 50.4 Gy in 1.8 Gy fractions. Higher doses up to 60 Gy are reasonable for spinal tumors below the conus medullaris. Proton beam craniospinal irradiation may be considered when toxicity is a concern.

SRS has been used as a boost after EBRT or to treat recurrence with some success, although long-term results are still lacking.¹⁵⁴⁻¹⁵⁶

Systemic Therapy

Research on chemotherapeutic regimens has also centered on pediatric ependymomas, while the role of chemotherapy in the treatment of adult patients remains poorly defined. No study has demonstrated a survival

advantage with the addition of chemotherapy to irradiation in newly diagnosed tumors. However, chemotherapy is sometimes considered as an alternative to palliative/best supportive care or RT in the recurrence setting. Possible options include platinum-based regimens (cisplatin or carboplatin),^{157,158} etoposide,¹⁵⁹ lomustine or carmustine,¹⁵⁸ bevacizumab,¹⁶⁰ and temozolomide.

NCCN Recommendations

Primary and Adjuvant Treatment

Whenever possible, maximal safe resection should be attempted with contrast-enhanced brain image verification within 24 to 72 hours. Spine MRI should be delayed by at least 2 to 3 weeks after surgery to avoid post-surgical artifacts. Due to the established relationship between the extent of resection and outcome, multidisciplinary review and re-resection (if possible) should be considered if MRI shows that initial resection is incomplete. If maximal resection is not feasible at diagnosis due to anatomic or other factors, biopsy (stereotactic or open) or STR should be performed. If feasible, reoperation should be considered to complete resection.

The adjuvant treatment algorithm revolves around the extent of surgical resection, histology, and staging by cranial spinal MRI and cerebrospinal fluid (CSF) cytology. For spinal ependymomas, brain MRI is necessary to determine if these are drop metastases from the brain. CSF dissemination develops in up to 15% of intracranial ependymomas. Lumbar puncture for CSF cytology, delayed at least 2 weeks after surgery, should be performed for anaplastic ependymoma and/or if resection is suboptimal. CSF analysis is also indicated for grade II ependymomas following GTR if spine MRI is negative. However, lumbar puncture may be contraindicated in some cases (for example, posterior fossa mass). Patients who have undergone GTR and have negative findings for MRI and CSF may be observed if the tumor is supratentorial

or spinal or consider adjuvant limited-field fractionated EBRT if the tumor is intracranial or myxopapillary. Patients with spinal ependymomas that have been totally resected usually do not require adjuvant RT as the recurrence rate is low. Limited-field fractionated EBRT is the appropriate postoperative management for patients with anaplastic ependymoma and/or STR, provided MRI (spine MRI for intracranial ependymoma and brain MRI for spinal ependymoma) and CSF findings are both negative. Craniospinal RT is mandatory when MRI spine or CSF results reveal metastatic disease, regardless of histology and extent of resection.

Follow-up and Recurrence

Follow-up of ependymoma depends on the extent and location of the disease. For localized disease, contrast-enhanced brain and spine MRI (if initially positive) should be done 2 to 3 weeks postoperatively and then every 3 to 4 months for one year. The interval can then be extended to every 4 to 6 months in the second year and then every 6 to 12 months, depending on the physician's concern regarding the extent of disease, histology, and other relevant factors. If tumor recurrence in the brain or spine is noted on one of these scans, restaging by brain and spine MRI as well as CSF analysis is necessary. Resection is recommended if possible. RT should be administered (after surgery if performed) if not given originally; SRS may be considered in geometrically favorable cases.

Upon disease progression, several options are available depending on the histologic type, extent of disease, age of the patient, and PS: 1) RT (including SRS or reirradiation of previously irradiated sites); 2) chemotherapy for patients who are refractory to surgery or RT; or 3) palliative or best supportive care.

Medulloblastoma and Supratentorial PNET

Cranial PNETs are embryonal neoplasms showing varying degrees of differentiation. They are described by their location as infratentorial (medulloblastomas) and supratentorial (cerebral neuroblastoma, pineoblastoma, or esthesioneuroblastoma). The WHO classification system further divided these tumors into histologic variants.¹⁶¹ CNS PNETs are infrequent in children and very rare in adults, with an overall incidence of 0.26 per 100,000 person-years reported by the Central Brain Tumor Registry of the United States (CBTRUS).¹⁶² Overall, it represents only 1.8% of all brain tumors, although it is the most common type among pediatric brain malignancies.

About half of the affected patients will present with elevated intracranial pressure. Headache, ataxia, and nausea are commonly observed symptoms.¹⁶³ All PNETs of the brain are WHO grade IV, as they are invasive and rapidly growing. They also have the tendency to disseminate through the CSF. Larger retrospective case series of adult patients reported a 10-year survival of 48% to 55% with frequent recurrence beyond 5 years, commonly in the posterior fossa.^{164,165}

Treatment Overview

Surgery

Evidence in adult patients is meager for this rare disease and there are no randomized trial data, but there is general consensus that surgical resection should be the routine initial treatment to establish diagnosis, relieve symptoms, and maximize local control. Complete resection can be achieved in half of the patients^{163,166,167} and is associated with improved survival.^{166,168} In addition, surgical placement of a ventriculoperitoneal shunt can be used to treat hydrocephalus.

Radiation Therapy

Adjuvant RT following surgery is the current standard of care, although most studies are based on the pediatric population. The conventional dose is 30 to 36 Gy of craniospinal irradiation and a boost to a total of 54 to 55.8 Gy to the primary brain site.^{166,168} A lower craniospinal dose of 23.4 Gy, combined with chemotherapy, has gained popularity for average-risk patients to lessen side effects while maintaining 54 to 55.8 Gy to the posterior fossa,^{164,169,170} although one randomized trial found an increased relapse risk with dose reduction.¹⁷¹ It is reasonable to consider proton beam for craniospinal irradiation where available as it is associated with less toxicity.¹⁷² SRS demonstrated safety and efficacy in a small series of 12 adult patients with residual or recurrent disease.¹⁷³

Systemic Therapy

The use of post-irradiation chemotherapy to allow RT dose reduction is becoming increasingly common especially for children,^{169,170} but optimal use of adjuvant chemotherapy is still unclear for adult patients.^{163-165,174,175} A phase III study that enrolled more than 400 patients between ages 3 and 21 to receive post-irradiation cisplatin-based chemotherapy regimens recorded an encouraging 86% 5-year survival.¹⁷⁶

Several regimens are in use in the recurrence setting, most of which include etoposide.¹⁷⁷⁻¹⁷⁹ Temozolomide has also been used in this setting.⁸⁵ High-dose chemotherapy in combination with autologous stem cell transplantation is a feasible strategy for patients who have had good response with lower doses.^{179,180}

NCCN Recommendations

Primary Treatment

MRI scan is the gold standard in the assessment and diagnosis of PNET. The typical tumor shows enhancement and heterogeneity.

Fourth ventricular floor infiltration is a common finding related to worse prognosis.^{164,165,175} Multidisciplinary consultation before treatment initiation is advised. Maximal safe resection is recommended wherever possible. Contrast-enhanced brain MRI should be performed within 24 to 72 hours following surgery, but spinal MRI should be delayed by 2 to 3 weeks. Because of the propensity of PNET to CSF seeding, CSF sampling after spine imaging via lumbar puncture is also necessary for staging. Medulloblastoma should be staged according to the modified Chang system using information from both imaging and surgery.^{181,182}

Adjuvant Therapy

Patients should be stratified according to recurrence risk for planning of adjuvant therapy (reviewed by Brandes et al¹⁸³). The NCCN Panel agrees that patients with large cell or anaplastic medulloblastoma, supratentorial PNET, disease dissemination, unresectable tumors, or residual tumors more than 1.5 cm² postsurgery are at heightened risk. These patients should undergo irradiation of the neuraxis followed by chemotherapy. Collection of stem cells before RT may be considered on the condition that RT is not delayed for potential future autologous stem cell reinfusion at disease progression. For patients at average risk, craniospinal RT alone or craniospinal RT with chemotherapy followed by post-irradiation chemotherapy are both viable options.

Recurrence and Progression

There are no robust data supporting an optimal follow-up schedule for PNETs. General guidelines include brain MRI every 3 months for the first 2 years, biannual brain MRI for the next 3 years, then yearly brain scans. If recurrent disease is detected on these scans, CSF sampling is also required. Concurrent spine imaging should be performed as clinically indicated for patients with previous spinal disease. Bone scans, CT scans, and bone marrow biopsies should be conducted as indicated.

Maximal safe resection should be attempted on recurrent brain tumors. High-dose chemotherapy with autologous stem cell rescue may be considered for patients showing no evidence of disease following resection or conventional reinduction chemotherapy. On disease progression, options include chemotherapy alone, RT alone (including SRS), and chemoradiation. Patients with metastases should be managed by chemotherapy or best supportive care such as palliative RT.

Primary CNS Lymphomas

PCNSL accounts for approximately 3% of all primary CNS tumors. It is an aggressive form of non-Hodgkin's lymphoma that develops within the brain, spinal cord, eye, or leptomeninges without evidence of systemic involvement. Its age-adjusted incidence has seen a three-fold increase over the past 20 years from 0.15 to 0.48 per 100,000, in part due to the impact of HIV infections.¹⁸⁴ Non-immunosuppressed patients have a better prognosis than AIDS-related cases,¹⁸⁵ and survival of this group has improved over the years with treatment advances.¹⁸⁶

Pathologically, PCNSL is an angiocentric neoplasm composed of a dense monoclonal proliferation of lymphocytes, usually diffuse large B-cells.¹⁸⁷ The tumor is infiltrative and typically extends beyond the primary lesion, as shown by CT or MRI scans, into regions of the brain with an intact BBB. The brain parenchyma is involved in more than 90% of all PCNSL patients, and the condition can be multifocal in more than 50% of cases. Leptomeningeal involvement may occur, either localized to adjacent parenchymal sites or in diffuse form (that is, positive cytology) in up to 30% of patients. Ocular involvement may develop independently in 10% to 20% of patients. Patients with PCNSL can present with various symptoms because of the multifocal nature of the disease. In a retrospective review of 248 immunocompetent patients,

43% had mental status changes, 33% showed signs of elevated intracranial pressure, 14% had seizures, and 4% suffered visual symptoms at diagnosis.¹⁸⁸

Treatment Overview

Steroid Administration

Steroids can rapidly alleviate signs and symptoms of PCNSL and improve PS. However, as these drugs are cytolytic, they can significantly decrease enhancement and size of tumors on CT and MRI scans as well as affect the histologic appearance. In the absence of significant mass effect, it is recommended that steroids be withheld or used judiciously until diagnostic tissue can be obtained if PCNSL is suspected.

Stereotactic Biopsy

In contrast to the principles previously outlined for invasive astrocytomas and other gliomas, the surgical goals for PCNSL are more modest, with the goal of obtaining diagnostic tissue under minimal risk of morbidity. Currently, most authors recommend stereotactic biopsy as the surgical method of choice.¹⁸⁹ This approach stems from the fact that data do not demonstrate a survival advantage for patients who have had a complete resection or extensive STR when compared with those who have had only a stereotactic biopsy. In addition, STR is associated with risk for postoperative neurologic deficits.¹⁸⁸

Systemic Therapy

Methotrexate is the most effective agent against PCNSL. It is commonly used in combination with other drugs such as vincristine, procarbazine, cytarabine, rituximab, and ifosfamide, but it may also be administered as monotherapy if toxicity tolerance is a concern.¹⁹⁰⁻¹⁹⁸ High doses of intravenous methotrexate are necessary (3.5 g/m² or higher) to overcome the BBB. Intrathecal methotrexate, when given as

prophylaxis in addition to intravenous methotrexate in primary treatment, confers no clinical advantage and is not recommended,¹⁹⁹ but can be useful where CSF cytology yields positive findings.

Renal dysfunction induced by high-dose methotrexate therapy is a potentially lethal medical emergency due to heightened toxicities resulting from a delay in methotrexate excretion. Early intervention with glucarpidase, a recombinant bacterial enzyme that provides an alternative route for methotrexate clearance, has shown efficacy in rapidly reducing plasma concentrations of methotrexate and preventing severe toxicity.^{200,201}

Chemotherapy is usually followed by consolidation RT as initial treatment to maximize response and improve outcome. Pre-irradiation chemotherapy, as opposed to post-irradiation chemotherapy, has been emphasized for several theoretical reasons. Chemotherapy given before RT may be less neurotoxic than if given after RT. Also, drug delivery to a PCNSL may be increased before RT, when the BBB is maximally disrupted by the tumor. RT results in tumor regression as well as partial repair and closure of the BBB behind the regressing tumor. Finally, pre-irradiation chemotherapy allows one to assess the efficacy of chemotherapy without the confounding variable of RT.

Because patients older than 60 years often suffer from significant and sometimes lethal neurotoxic effects from consolidation RT,^{194,202,203} a number of phase II trials have adopted the approach of chemotherapy with deferred RT.^{190,194,204-208} Complete response to chemotherapy ranged from 42% to 61%, with overall survival between 14 and 55 months. However, a high fraction of patients who have forgone initial RT—typically older or with significant comorbidities—will fail to achieve complete response to chemotherapy and later require WBRT.

Unfortunately, even for patients who initially achieved complete response, half of them will eventually relapse. Re-treatment with high-dose methotrexate may be useful in patients who achieved complete response with prior exposure.²⁰⁹ Several other regimens, including temozolomide,^{210,211} rituximab,²¹² rituximab plus temozolomide,²¹³ topotecan,²¹⁴ high-dose cytarabine,²¹⁵ dexamethasone plus high-dose cytarabine and cisplatin,²¹⁶ and pemetrexed²¹⁷ have also shown activity in the recurrence or progressive disease setting, but none has been established as a standard of care. Several groups have tested high-dose chemotherapy with autologous stem cell transplantation with some success,²¹⁸⁻²²⁰ although evidence of its advantage over conventional treatment is lacking. The panel included this as a category 2B option to consider for progressive or recurrent disease.

There has been discussion among panel members regarding the role of intra-arterial therapy with mannitol disruption of the BBB.^{221,222} A series of 149 patients reported a response rate of 82% and overall survival reaching 3.1 years.²²¹ However, given the complexity of the procedure and the high level of expertise required for safety, the panel opted not to recommend this technique at the present time.

Radiation Therapy

Historically, WBRT has been the treatment standard to cover the multifocal nature of the disease. The majority of studies demonstrated the limitation of high-dose RT and led to the currently recommended dose of 24 to 36 Gy in 1.8 to 2.0 Gy fractions to the whole brain, without a boost.^{192,195,223-226} Although RT alone is useful for initial tumor control, frequent and rapid relapse of the disease led to a short overall survival of 12 to 17 months.^{185,225} This dismal outcome has prompted the addition of pre-irradiation methotrexate-based combination chemotherapy in later studies. This approach yields impressive response rates of up to 94% and improved overall survival ranging from

33 to 60 months.^{192-195,202,203,223,227,228} However, excessive grade 3 and 4 hematologic toxicity (up to 78%) as well as RT-induced delayed neurotoxicity (up to 32%) sometimes leading to deaths are primary concerns, although most of these studies utilized a high RT dose of more than or equal to 40 Gy. Of note, younger patients (age <60) consistently fare better, and there is a higher incidence of late neurotoxic effects in older patients.

Thiel and colleagues¹⁹⁶ conducted a randomized, phase III, non-inferiority trial of high-dose methotrexate plus ifosfamide with or without WBRT in 318 patients with PCNSL. There was no difference in overall survival (HR, 1.06; 95% CI, 0.80–1.40; *P* = .71), but the primary hypothesis (0.9 non-inferiority margin) was not proven. Patients who received WBRT had a higher rate of neurotoxicity than those who did not (49% vs. 26%).

Although WBRT alone is seldom sufficient as primary treatment and is primarily reserved for patients who cannot tolerate multimodal treatment, it can be effective as second-line therapy following chemotherapy failure, with response rates reaching nearly 75%.²²⁹

NCCN Recommendations

Initial Evaluation

Neuroradiologic evaluation is important in the diagnosis of PCNSL and to evaluate the effectiveness of subsequent therapy. With MRI, the tumor is often isointense or hypointense on T1- and T2-weighted images and enhances frequently.²³⁰ In addition, restricted diffusion can be seen in the area of the enhancing abnormality on diffusion-weighted imaging sequences. On a CT scan, PCNSL is usually isodense or hyperdense compared to the brain and enhances in most cases. Hallmark features include a periventricular distribution, ring enhancement, multiple lesions, and a smaller amount of edema than

might otherwise be expected from a similar-sized metastatic tumor or glioma. If enhanced-contrasted MRI (or contrast CT if MRI is contraindicated) suggests PCNSL, clinicians are advised to hold the use of steroids if possible before diagnosis is established, since the imaging and histologic features of PCNSL can be profoundly affected by these drugs.

A lumbar puncture with evaluation of CSF should be considered, if it can be done safely and without concern for herniation from increased intracranial pressure. The yield for a positive diagnostic test can be increased by the use of molecular markers of monoclonality, such as an immunoglobulin gene rearrangement. If the CSF is negative, consider an ophthalmologic evaluation including a slit-lamp examination to exclude an obvious malignant uveitis. Ocular biopsy should follow suspicious findings. Despite CSF or uveal evaluation, the intracranial lesion often requires a brain biopsy for a definitive diagnosis.¹⁸⁹ Because the role of maximal surgical resection is limited to alleviating symptoms of raised intracranial pressure or preventing herniation,¹⁸⁸ stereotactic biopsy is generally preferred to minimize invasiveness. Even with molecular marker testing, however, a biopsy can occasionally be falsely negative, particularly if the patient had been treated previously with steroids. Thus, if a biopsy is nondiagnostic, the panel recommended that the steroids be tapered and that the patient be followed closely, both clinically and radiographically. If and when the lesion recurs, the lesion should be promptly rebiopsied before the initiation of steroids. If, on the other hand, no definitive diagnosis of lymphoma is made from biopsy and the patient has not received steroid therapy, workup for other diagnoses (for example, inflammatory processes) or rebiopsy is recommended.

Staging Workup

Once the diagnosis of PCNSL is established, the patient should undergo a thorough staging workup detailed by The International PCNSL Collaborative Group.¹⁸⁹ This workup involves a complete CNS evaluation including imaging of the entire neuraxis (MRI of the spine with contrast). This should be done before CSF analysis is attempted to avoid post-lumbar puncture artifacts that can be mistaken for leptomeningeal disease on imaging. A slit-lamp eye examination, if not previously performed, should also be done, as well as a lumbar puncture for CSF flow cytometry. In addition, blood work (CBC and chemistry panel) and a CT of the chest, abdomen, and pelvis are required to rule out systemic involvement.

An HIV blood test should also be performed, because both prognosis and treatment of patients with HIV-related PCNSL may be different than that of patients who are otherwise immunocompetent. HIV-positive patients should consider highly active retroviral therapy.

More elaborate tests such as bone marrow biopsy, testicular ultrasound for older men, and body PET scan²³¹ may be considered (category 2B), although their value in routine workup is still under debate.

Primary Treatment

Treatment should be initiated as soon as possible following confirmation of diagnosis. Given the dramatic effect of steroids on symptom relief, they are commonly administered concurrently with workup. Selection of primary therapy depends on the general health condition and age of the patient. For healthier patients with KPS 40 or higher, a high-dose methotrexate-containing regimen is recommended. In the case of methotrexate induced-renal dysfunction, consider urgent glucarpidase to aid clearance.

Whether one performs WBRT after systemic chemotherapy depends on the responsiveness of the disease to chemotherapy and on the clinical judgment of the medical and radiation oncologists. WBRT may increase neurotoxicity, especially in patients older than 60 years, and may be withheld in the primary setting. If a patient is found to have malignant uveitis, RT to the globe has been the standard recommendation because of poor penetration of systemic chemotherapy into the uveal fluid. However, there are reports of clearance of ocular lymphoma in patients who were treated with systemic high-dose methotrexate.¹⁹⁰ Therefore, with a PCNSL patient who has asymptomatic ocular involvement, a reasonable strategy is to delay RT to the globe in order to see if high-dose methotrexate is effective. Intraocular injection of chemotherapy (category 2B) is also an option. Additionally, if the patient is found to have a malignant pleocytosis in the CSF, direct intrathecal chemotherapy can be considered (category 2B).

Patients with KPS below 40 are too weak to undergo multi-modal treatment. However, these patients are potentially eligible for a change to more aggressive therapy if their PS improves following steroid therapy. If the health condition remains poor, it is recommended that treatment consist of WBRT in order to rapidly induce a response, diminish neurologic morbidity, and optimize quality of life. RT to the globe is advised if ocular involvement is detected. Chemotherapy is also an option; non-methotrexate-based regimens may be used if the patient cannot tolerate methotrexate. If the lumbar puncture or spinal MRI is positive, consider intra-CSF chemotherapy plus focal spinal RT. Best supportive care is another option.

Progressive Disease

For patients who are treated with prior WBRT and ultimately relapse, they may consider further chemotherapy (systemic and/or intrathecal),

reirradiation, or palliative/best supportive care. High-dose therapy with stem cell rescue can also be considered (category 2B).

For patients who were initially treated with high-dose methotrexate-based chemotherapy but did not receive WBRT, the decision about whether to use more chemotherapy or proceed to RT at the time of relapse depends on the duration of response to initial chemotherapy. If a patient had experienced a relatively long-term response of one year or more, then treating either with the same or another regimen is reasonable. However, for patients who either have no response or relapsed within a very short time after systemic therapy, recommendations include WBRT or involved-field RT, with or without chemotherapy.²²⁹ In either case, palliative/best supportive care remains an option, or high-dose chemotherapy with stem cell transplantation may be considered (category 2B).

Primary Spinal Cord Tumors

Spinal tumors are classified according to their anatomic location as extradural, intradural-extramedullary, and intradural-intramedullary. Extradural tumors are primarily due to metastatic disease and are discussed in the section *Metastatic Spinal Tumors*. This section focuses on intradural primary spinal tumors.

Primary spinal cord tumors are a histologically diverse set of disease that represents 2% to 4% of all primary CNS tumors. The overall incidence is 0.74 per 100,000 person-years with a 10-year survival rate of 64%.²³² Extramedullary lesions, most commonly benign meningiomas, account for 70% to 80% of spinal cord tumors.²³³ Astrocytomas (more prevalent in children) and ependymomas (more prevalent in adults) are the most common intramedullary tumors. Clinicians are advised to refer to the corresponding sections in these

guidelines for further details regarding these subtypes, as intracranial and spinal lesions are biologically similar.

Individuals with type I neurofibromatosis, type II neurofibromatosis, and von Hippel-Lindau syndrome are predisposed to form, respectively, spinal astrocytomas, spinal peripheral nerve sheath tumors, spinal ependymomas, and intramedullary hemangioblastomas.

Since 70% of primary spinal cord tumors are low-grade and slow-growing,²³² it is common for patients to suffer from pain for months to years before diagnosis. Pain that worsens at night is a classic symptom for intramedullary lesions. Progressive motor weakness occurs in half of the patients, and patients may experience sensory loss with late autonomic dysfunction (incontinence).

Treatment Overview

Observation

Many asymptomatic primary tumors of the spinal cord, especially grade I meningiomas and peripheral nerve sheath tumors, follow an indolent course and can be followed by observation without immediate intervention.

Surgery

Surgery is the preferred treatment when the tumor is symptomatic. For lesions that are radiographically well defined, such as ependymoma, WHO grade I astrocytoma, hemangioblastoma, schwannoma, and WHO grade I meningioma, potentially curative, maximal, safe resection is the goal. En bloc total resection yielded excellent local control rates of more than 90%.²³⁴⁻²³⁷

GTR is seldom feasible with grade II or higher astrocytomas because they are infiltrative and poorly circumscribed. In a study of 202 patients

with intramedullary tumors, over 80% of grade I astrocytomas were completely resected, while total resection was achieved in only 12% of grade II tumors.²³⁸ Nevertheless, Benes et al²³⁹ conducted a review of 38 studies on spinal astrocytomas and concluded that maximal safe resection should be attempted whenever possible based on reports of survival benefit.

Radiation Therapy

RT is not recommended as primary therapy because of limited response, unknown histology without surgery, and low RT tolerance of the spinal cord. It is also not advisable following GTR, as tumors that can be excised completely have a low local recurrence rate.

A large retrospective analysis including over 1700 patients with primary spinal gliomas found an association between RT and worse cause-specific and overall survival, although there may be a bias that patients who received RT had more adverse factors.²⁴⁰ The role of adjuvant RT following incomplete excision or biopsy remains controversial.^{239,241,242} One exception is primary spinal myxopapillary ependymoma, for which postoperative RT has been demonstrated to reduce the rate of tumor progression.^{243,244} On the other hand, EBRT is considered a viable option at disease progression or recurrence. SRS has also shown safety and efficacy in several patient series.²⁴⁵⁻²⁴⁷

Systemic Therapy

Unfortunately, evidence on efficacious chemotherapeutic agents for primary spinal cord tumors is too scant for specific recommendations. The panel agrees that chemotherapy should be an option where surgery and RT fail, but there is no consensus on the best regimen. Chemotherapy is best given in the setting of a clinical trial.

NCCN Recommendations

MRI imaging is the gold standard for diagnosis of spinal cord lesions. Asymptomatic patients may be observed (especially for suspected low-grade) or resected, while all symptomatic patients should undergo some form of surgery. The surgical plan and outcome is influenced by whether a clear surgical plane is available.²⁴⁸ Whenever possible, maximal safe resection should be attempted. Postoperative adjuvant RT is appropriate if symptoms persist after incomplete resection or biopsy, or for patients with asymptomatic, intramedullary, low-grade glioma. Adjuvant RT may also be considered for patients with myxopapillary ependymoma that has been incompletely resected. Patients should be managed according to the pathology results (see *Low-Grade Infiltrative Astrocytomas & Oligodendrogliomas, Anaplastic Gliomas and Glioblastomas, and Intracranial and Spinal Ependymomas*). Those diagnosed with hemangioblastoma should consider screening for von Hippel-Lindau syndrome including neuraxis imaging.

All patients should be followed by sequential MRI scans. At progression or recurrence, re-resection is the first choice. If this is not feasible, conventional EBRT or SRS is the next option. Chemotherapy is reserved for cases where both surgery and RT are contraindicated.

Meningiomas

Meningiomas are extra-axial CNS tumors arising from the arachnoid cap cells in the meninges. They are most often discovered in middle-to-late adult life, and have a female predominance. The annual incidence for males and females reported by CBTRUS are 1.8 and 3.4 per 100,000 people, respectively.¹⁶² In a review of 319 cases using the WHO grading scale, 92% of meningiomas are grade I (benign), 6% are grade II (atypical), and 2% are grade III (malignant).²⁴⁹ Small tumors are

often asymptomatic, incidental findings.²⁵⁰ Seizure is a common presenting symptom occurring in 27% of patients.²⁵¹

Imaging

Brain imaging with contrast-enhanced CT or MRI is the most common method of diagnosing, monitoring, and evaluating response to treatment (review by Campbell et al²⁵²). The CT scan best reveals the chronic effects of slowly growing mass lesions on bone remodeling. Calcification in the tumor (seen in 25%) and hyperostosis of the surrounding skull are features of an intracranial meningioma that can be easily identified on a non-contrast CT scan. Nonetheless, MR imaging reveals a number of imaging characteristics highly suggestive of meningioma, and in stereotactic RT articles, MR has been used to operationally define pathology. These MR findings include a tumor that is dural-based and isointense with gray matter, demonstrates prominent and homogeneous enhancement (>95%), has frequent CSF/vascular cleft(s), and often has an enhancing dural tail (60%). However, approximately 10% to 15% of meningiomas have an atypical MRI appearance mimicking metastases or malignant gliomas. In particular, secretory meningiomas may have a significant amount of peritumoral edema. Cerebral angiography is occasionally performed, often for surgical planning, as meningiomas are vascular tumors prone to intraoperative bleeding. In some instances preoperative embolization is helpful for operative hemostasis management. Angiographic findings consistent with a meningioma include a dual vascular supply with dural arteries supplying the central tumor and pial arteries supplying the tumor periphery. A “sunburst effect” may be seen due to enlarged and multiple dural arteries, and a prolonged vascular stain or so-called “blushing” can be seen, which results from intratumoral venous stasis and expanded intratumoral blood volume.

Meningiomas are also known to have high somatostatin receptor density, which allows for the use of octreotide brain scintigraphy to help delineate extent of disease and to pathologically define an extra-axial lesion.²⁵³⁻²⁵⁵ Octreotide imaging with radiolabeled indium or, more recently, gallium may be particularly useful in distinguishing residual tumor from postoperative scarring in subtotally resected/recurrent tumors.

Treatment Overview

Observation

Studies that examined the growth rate of incidental meningiomas in otherwise asymptomatic patients suggested that many asymptomatic meningiomas may be followed safely with serial brain imaging until either the tumor enlarges significantly or becomes symptomatic.^{256,257}

These studies confirm the tenet that many meningiomas grow very slowly and that a decision not to operate is justified in selected asymptomatic patients. As the growth rate is unpredictable in any individual, repeat brain imaging is mandatory to monitor an incidental asymptomatic meningioma.

Surgery

The treatment of meningiomas is dependent upon both patient-related factors (ie, age, PS, medical comorbidities) and treatment-related factors (ie, reasons for symptoms, resectability, goals of surgery). Most patients diagnosed with surgically accessible symptomatic meningioma undergo surgical resection to relieve neurologic symptoms. Complete surgical resection may be curative and is therefore the treatment of choice. Both the tumor grade and the extent of resection impact the rate of recurrence. In a cohort of 581 patients, 10-year progression-free survival was 75% following GTR but dropped to 39% for patients receiving STR.²⁵⁸ Short-term recurrences reported for grade I, II, and III meningiomas were 1% to 16%, 20% to 41%, and 56% to 63%,

respectively.²⁵⁹⁻²⁶¹ The Simpson classification scheme that evaluates meningioma surgery based on extent of resection of the tumor and its dural attachment (grades I to V in decreasing degree of completeness) correlates with local recurrence rates.²⁶² First proposed in 1957, it is still being widely used by surgeons today.

Radiation Therapy

Safe GTR is sometimes not feasible due to tumor location. In this case, STR followed by adjuvant EBRT has been shown to result in long-term survival comparable to GTR (86% vs. 88%, respectively), compared to only 51% with incomplete resection alone.²⁶³ Of 92 patients with grade I tumors, Soyuer and colleagues found that RT following STR reduced progression compared to incomplete resection alone, but has no effect on overall survival.²⁶⁴

Because high-grade meningiomas have a significant probability of recurrence even following GTR,²⁶⁵ postoperative high-dose EBRT (>54 Gy) has become the accepted standard of care for these tumors to improve local control.²⁶⁶ A review of 74 patients showed that adjuvant RT improves survival in patients with grade III meningioma and in those with grade II disease with brain invasion.²⁶⁷ The role of post-GTR RT in benign cases remains controversial.

Technical advances have enabled stereotactic administration of RT by linear accelerator (LINAC), Leksell Gamma Knife™, or CyberKnife™ radiosurgery. The use of stereotactic RT (either single fraction or fractionated) in the management of meningiomas continues to evolve. Advocates have suggested this therapy in lieu of EBRT for small (<35 mm), recurrent, or partially resected tumors. In addition, it has been used as primary therapy in surgically inaccessible tumors (ie, base-of-skull meningiomas) or in patients deemed poor surgical candidates because of advanced age or medical comorbidities. A study of about

200 patients compared surgery with SRS as primary treatment for small meningiomas.²⁶⁸ The SRS arm had similar 7-year progression-free survival compared to GTR and superior survival over incomplete resection. In another study, Kondziolka and colleagues followed a cohort of 972 meningioma patients managed by SRS over 18 years.²⁶⁹ Half of the patients have undergone previous surgery. SRS provided excellent tumor control (93%) in patients with grade I tumors. For grade II and III meningiomas, tumor control was 50% and 17%, respectively. Another smaller study of 72 patients also reported good 5-year overall and progression-free survival for grade 0 and I meningioma (79% and 95%, respectively).²⁷⁰ These results suggest that stereotactic RT is effective as primary and second-line treatment for meningiomas smaller than 3.5 cm.

Systemic Therapy

Targeted therapies that have shown partial efficacy in refractory meningiomas are somatostatin analogues^{271,272} and alpha interferon²⁷³.

NCCN Recommendations

Initial Treatment

Meningiomas are typically diagnosed by CT or MRI imaging. Biopsy or octreotide scan may be considered for confirmation. For treatment planning, multidisciplinary panel consultation is encouraged. Patients are stratified by the presence or absence of symptoms and the tumor size. Most asymptomatic patients with small tumors (<30 mm) are best managed by observation. If neurologic impairment is imminent, surgery (if accessible) or RT (EBRT or SRS) is feasible. Asymptomatic tumors 30 mm or larger should be surgically resected or observed.

Symptomatic disease requires active treatment by surgery whenever possible. Non-surgical candidates should undergo RT.

Regardless of tumor size and symptom status, all patients with surgically resected grade III meningioma (even after GTR) should receive adjuvant RT to enhance local control. Postoperative RT should be considered for the following: 1) asymptomatic grade II tumors; 2) large asymptomatic grade I tumors that have been incompletely resected; and 3) large symptomatic grade I or II tumors that have been incompletely resected. SRS may be used in lieu of conventional RT as adjuvant or primary therapy in asymptomatic cases.

Follow-up and Recurrence

In the absence of data, panelists have varying opinions on the best surveillance scheme and clinicians should follow patients based on individual clinical conditions. Generally, malignant or recurrent meningiomas are followed more closely than grade I and II tumors. A typical schedule for low-grade tumors is MRI every 3 months in year 1, then every 6 to 12 months for another 5 years. Less frequent imaging is required beyond 5 to 10 years.

Upon detection of recurrence, the lesion should be resected whenever possible, followed by RT. Non-surgical candidates should receive RT. Chemotherapy is reserved for patients with an unresectable recurrence refractory to RT. Regimen options include somatostatin analogues (for somatostatin receptor-positive tumors only) and interferon alfa (category 2B). Observation is an option if there is no clinical indication for treatment at recurrence.

Brain Metastases

Metastases to the brain are the most common intracranial tumors in adults and may occur up to 10 times more frequently than primary brain tumors. Population-based data reported that about 8% to 10% of cancer patients are affected by symptomatic metastatic tumors in the brain.^{274,275} A much higher incidence based on autopsy has been

reported. As a result of advances in the diagnosis and treatment, many patients improve with proper management and do not die of progression of these metastatic lesions. Primary lung cancers are the most common source, accounting for half of intracranial metastases, although melanoma has been documented to have the highest predilection to spread to the brain. Diagnosis of CNS involvement is becoming more common in patients with breast cancer as therapy for metastatic disease is improving.²⁷⁶

Nearly 80% of brain metastases occur in the cerebral hemispheres, an additional 15% occur in the cerebellum, and 5% occur in the brainstem.²⁷⁷ These lesions typically follow a pattern of hematogenous spread to the gray-white junction where the relatively narrow caliber of the blood vessels tends to trap tumor emboli. The majority of cases have multiple brain metastases evident on MRI scans. The presenting signs and symptoms of metastatic brain lesions are similar to those of other mass lesions in the brain, such as headache, seizures, and neurologic impairment.

Treatment Overview

Surgery

Advances in surgical technique have rendered upfront resection followed by WBRT the standard of care for solitary brain metastases. A retrospective analysis of 13,685 patients admitted for resection of metastatic brain lesions showed a decline in in-hospital mortality from 4.6% in the period of 1988 through 1990 to 2.3% in the period of 1997 through 2000.²⁷⁸ High-volume hospitals and surgeons produced superior outcomes.

Patchell conducted a study that randomized 95 patients with single intracranial metastases to complete resection alone or surgery plus adjuvant WBRT.²⁷⁹ Postoperative RT was associated with dramatic

reduction in tumor recurrence (18% vs. 70%; $P < .001$) and likelihood of neurologic deaths (14% vs. 44%; $P = .003$). Overall survival, a secondary endpoint, showed no difference between the arms. Comparison of surgery plus WBRT versus WBRT alone is discussed in the WBRT section.

In the case of multiple lesions, the role of surgery is more restricted to obtaining biopsy samples or relieving mass effect due to large symptomatic metastases. However, evidence from retrospective series suggested survival benefits from tumor resection for selected patients of good prognosis with up to three metastatic sites.^{280,281}

Stereotactic Radiosurgery

The advent of SRS offered a minimally invasive option as opposed to surgery. Patients undergoing SRS avoid the risk of surgery-related morbidity. Late side effects such as edema and RT necrosis are uncommon.²⁸²

Accumulating evidence suggests that low disease volume is a better selection criterion for SRS than a low number of metastatic lesions. A multivariate analysis of 205 patients who received SRS for 4 or more brain metastases demonstrated total treatment volume to be the most significant prognostic factor of survival, while the number of metastases did not reach significance.²⁸³ The same group conducted another analysis that identified a favorable subgroup of patients with a total treatment volume less than 7 cc and less than 7 brain lesions. These patients had significantly prolonged median survival (13 months) than other patients (6 months; $P < .00005$).²⁸⁴ A cohort study revealed that patients with a total SRS-treated volume of less than 5 cc or 5 to 10 cc survived longer than those with a total treated volume greater than 10 cc.²⁸⁵ No survival difference was observed between patients with a single metastasis or multiple metastases. Another group analyzed

patients divided by their number of brain lesions and found no difference in survival times or local control rates among the groups after SRS treatment.²⁸⁶ However, patients with more than 15 lesions had a higher risk of developing new lesions and distant disease progression.

Taken together, patients with multiple lesions but a low total volume of disease may be amenable to SRS. Additionally, patients with a favorable histology of the primary tumor (such as breast cancer) or controlled primary tumors can often benefit from SRS regardless of the number of brain metastases present.^{287,288} Some brain metastases of radio-resistant primary tumors such as melanoma and renal cell carcinoma have also been shown to achieve good local control with SRS.²⁸⁹ Other predictors of longer survival with SRS include younger age, good PS, and primary tumor control.^{283,287,288,290}

In a randomized Japanese study of 132 patients with 1 to 4 metastatic brain tumors smaller than 3 cm, addition of WBRT to SRS did not prolong median survival compared to SRS alone (7.5 months vs. 8.0 months, respectively).²⁹¹ However, 1-year brain recurrence rate was lowered in the WBRT plus SRS arm (47% vs. 76%; $P < .001$). Another small randomized trial of 58 patients with 1 to 3 brain metastases was stopped early due to a significant decline in learning and memory function among the group receiving both SRS and WBRT compared to the SRS group (52% vs. 24%).²⁹² Analysis showed that SRS plus WBRT was associated with better 1-year recurrence-free survival (73% than SRS alone (27%). A third trial recruited 359 patients with 1 to 3 metastatic brain lesions who underwent surgery or SRS.²⁹³ They were randomized to either adjuvant WBRT or observation. Compared to the observation arm, intracranial relapse rates and neurologic mortality were lower in the WBRT arm, but overall survival and duration of functional independence were similar. A meta-analysis concluded no overall survival improvement with the addition of WBRT to SRS.²⁹⁴

Retrospective comparative studies showed that SRS plus WBRT resulted in equivalent if not better survival compared with surgery and WBRT.²⁹⁵⁻²⁹⁷ SRS also conferred a significant improvement in local control, especially for patients with radiosensitive tumors or solitary brain lesions. A prospective observational study of 1194 patients reported no difference in overall survival between patients with 2 to 4 metastatic brain lesions and those with 5 to 10 lesions treated with SRS alone (HR, 0.97; 95% CI, 0.81–1.18; P non-inferiority $< .0001$).²⁹⁸ SRS alone compared to resection plus WBRT was evaluated in a randomized controlled trial by Muacevic et al.²⁹⁹ The study was stopped prematurely due to poor accrual. In the final analysis based on 64 patients with solitary brain metastases, radiosurgery alone was less invasive and resulted in equivalent survival and local control, but it was associated with a higher rate of distant relapse.

Several patient series have demonstrated local control rates greater than 70% with SRS in the recurrence setting for patients with good PS and stable disease who have received prior WBRT.³⁰⁰⁻³⁰⁵

Whole Brain Radiation Therapy

Historically, WBRT was the mainstay of treatment for metastatic lesions in the brain. It continues to play multiple roles in the modern era, such as primary intervention where surgery or SRS is not feasible (eg, polymetastatic brain metastases), as adjunctive therapy to prevent recurrence, and as treatment for recurrent disease.

Three randomized trials investigated the effectiveness of WBRT with or without surgery in patients with single brain metastases. In a study of 48 patients, Patchell et al³⁰⁶ demonstrated that surgery followed by WBRT lengthened overall survival (40 vs. 15 weeks in WBRT arm; $P < .01$) and functional dependence (38 vs. 8 weeks; $P < .005$), as well as decreased recurrence (20% vs. 52%; $P < .02$) compared to RT alone.

Similarly, combined treatment led to longer survival and functional independence in another randomized study by Vecht and colleagues (n=63).³⁰⁷ The greatest difference was observed in patients with stable disease; median survival was 12 months versus 7 months, and functional independence was 9 months versus 4 months. A third study of 84 patients found no difference in survival between the two strategies; however, patients with extensive systemic disease and lower performance level were included, which likely resulted in poorer outcomes in the surgical arm.³⁰⁸

The impact of SRS boost in addition to WBRT was evaluated in two published randomized controlled studies. A multi-institutional trial by RTOG (RTOG 9508) randomly assigned 333 patients with 1 to 3 brain metastases to WBRT plus SRS or WBRT only.³⁰⁹ Despite the inclusion of larger tumors (3–4 cm) that are not favorable to SRS, the authors found a significant survival benefit in the combined arm (6.5 vs. 4.9 months; $P = .04$) when treating a single metastases; this benefit was not observed in patients with multiple (2 or 3) lesions. A much smaller trial of 27 patients with 2 to 4 lesions found no significant difference in survival, although SRS did extend time to local failure (36 vs. 6 months; $P = .0005$).³¹⁰ Overall, no difference in overall survival was reported between the 2 approaches in a meta-analysis of the 2 trials.³¹¹ However, the addition of SRS to WBRT significantly improved local control and PS. SRS plus WBRT also prolonged overall survival of patients with single brain metastasis compared to WBRT alone (6.5 vs. 4.9 months; $P = .04$).

Taken together, WBRT in conjunction with surgery or SRS leads to better clinical outcomes than WBRT alone for good performance patients with solitary metastatic intracranial lesions. However, many patients are not candidates for resection because of the inaccessibility

of the tumor, extensive systemic disease, or other factors. WBRT is the main choice of primary therapy for this patient group.

No randomized data are available in the recurrent setting, but case series reported 31% to 70% of symptom-relieving response to irradiation.³¹²⁻³¹⁴

Systemic Therapy

Systemic therapy is rarely used as primary therapy for brain metastases. In randomized studies, addition of carboplatin or temozolomide to WBRT did not improve overall survival compared to RT alone,^{315,316} although there have been reports of increase in progression-free survival or radiologic response with temozolomide.^{316,317} Many tumors that metastasize to the brain are not very chemosensitive or have been already heavily pretreated with organ-specific effective agents. Poor penetration through the BBB is an additional concern. As such, chemotherapy is usually considered as a last line of therapy for recurrent disease when other options have been exhausted (ie, surgery, SRS, RT). The choice of agent depends on the histology of the primary tumor. Carmustine wafer implantation is a reasonable option at recurrence when resection is considered.³¹⁸

Among various agents, temozolomide may be useful in some patients with previously untreated brain metastases from metastatic melanoma.³¹⁹ Temozolomide given on a prolonged schedule in combination with thalidomide has been tested in a phase II study of patients with brain metastases, but the high toxicity and lack of response rendered the regimen inappropriate.³²⁰

A study of high-dose methotrexate in patients mostly with breast cancer achieved disease control in 56% of patients.³²¹ Other agents shown to

have activity in breast cancer include platinum plus etoposide^{322,323} and capecitabine with or without lapatinib.³²⁴⁻³²⁶

A phase I/II study of topotecan plus WBRT has shown a 72% response rate in 75 patients with brain metastases.³²⁷ Unfortunately, a follow-up phase III trial was closed early due to slow accrual.³²⁸

Rapid advancements in melanoma have produced effective systemic options for metastatic disease. These immunotherapeutic agents (ipilimumab) and BRAF inhibitors (dabrafenib and vemurafenib) have demonstrated activity in melanoma that has metastasized to the brain.³²⁹⁻³³¹

NCCN Recommendations

Workup

Patients who present with a single mass or multiple lesions on MRI or CT imaging suggestive of metastatic cancer to the brain, and who do not have a known primary, require a careful systemic workup with chest x-ray or CT, abdominal or pelvic CT, or other tests as indicated. FDG-PET can be considered if there is more than one brain lesion and no primary has yet been found. If no other readily accessible tumor is available for biopsy, a stereotactic or open biopsy resection is indicated to establish a diagnosis. Among patients with a known history of cancer and if there are concerns regarding the diagnosis of CNS lesions, a stereotactic or open biopsy resection or STR is also needed. Because brain metastases are often managed by multiple modalities, the NCCN Panel encourages multidisciplinary consultation prior to treatment for optimal planning.

Treatment for Limited (1–3) Metastatic Lesions

For patients with limited systemic disease or for whom reasonable systemic treatment options exist, aggressive management should be

strongly considered. For surgical candidates, high-level evidence supports category 1 recommendations for surgical resection plus postoperative WBRT and for SRS plus WBRT if only one brain lesion is involved. Other options include SRS alone or SRS following resection (category 2B). Macroscopic total removal is the objective of surgery. The choice between open resection and SRS depends on multiple factors such as tumor size and location. The best outcome for SRS is achieved for small, deep lesions at institutions with experienced staff. If the tumor is unresectable, WBRT and/or radiosurgery can be used.

Patients with progressive extracranial disease whose survival is <3 months should consider best supportive care or be treated with WBRT alone, but surgery may be considered for symptom relief. In patients with systemic cancers and druggable targets (eg, epidermal growth factor receptor [EGFR] mutations in non-small cell lung cancer; BRAF mutations in metastatic melanoma), targeted therapy in neurologically asymptomatic patients with brain metastases is considered reasonable before administration of radiotherapy.

Patients should be followed with MRI every 2 to 3 months for 1 year and then as clinically indicated. Closer follow-up every 2 months is particularly helpful for patients treated with SRS alone.²⁹² Recurrence on radiograph can be confounded by treatment effects of SRS. Consider tumor tissue sampling if there is a high index of suspicion of recurrence. Upon detection of recurrent disease, prior therapy clearly influences the choice of further therapies. Patients with recurrent CNS disease should be assessed for local versus systemic disease, because therapy will differ. For local recurrences, patients who were previously treated with surgery only can receive the following options: 1) surgery, 2) single-dose or fractionated SRS, 3) WBRT, or 4) chemotherapy. However, patients who previously received WBRT probably should not undergo WBRT at recurrence due to concern regarding neurotoxicity. If

the patient had previous SRS with a durable response for >6 months, reconsider SRS if imaging supports active tumor and not necrosis. Repeat SRS to a prior location is a category 2B recommendation. The algorithm for distant brain recurrences branches depending on whether patients have either 1 to 3 lesions or more than 3 lesions. In both cases, patients may receive WBRT or consider local/systemic chemotherapy, but patients with 1 to 3 recurrent tumors have the additional options of surgery or SRS.

WBRT should be used (30–45 Gy, given in 1.8–3.0 Gy fractions) depending on the patient's PS, if this modality was not used for initial therapy. Local or systemic chemotherapy may be considered for select patients, if the multiple lesions cannot be controlled by a combination of surgery and radiosurgery.³³²

If systemic CNS disease progression occurs in the setting of limited systemic treatment options and poor PS, palliative or best supportive care is the first option. WBRT may be administered if the patients have not been previously irradiated. For patients who have received prior WBRT, re-irradiation is an option only if they had a positive response to the first course of RT treatment.

Treatment for Multiple (>3) Metastatic Lesions

All patients diagnosed with more than three metastatic lesions should be treated with WBRT or SRS as primary therapy. The standard regimens for WBRT are 30 Gy in 10 fractions or 37.5 Gy in 15 fractions. For patients with poor neurologic performance, a more rapid course of RT can be considered (20 Gy, delivered in 5 fractions). SRS may be considered in patients with good PS and low overall tumor volume. Palliative neurosurgery should be considered if a lesion is causing a life-threatening mass effect, hemorrhage, or hydrocephalus.

After WBRT or SRS, patients should have a repeat contrast-enhanced MRI scan every 3 months for 1 year. If a recurrence is found, the algorithm branches depending on whether patients have 1) systemic disease progression with limited systemic treatment options; or 2) stable systemic disease or reasonable systemic treatment options. For patients with systemic disease progression, options include palliative/best supportive care or reirradiation. For patients with stable systemic disease, options include surgery, reirradiation, or chemotherapy.

Leptomeningeal Metastases

Leptomeningeal metastasis or neoplastic meningitis refers to the multifocal seeding of the leptomeninges by malignant cells. It is known as leptomeningeal carcinomatosis or carcinomatous meningitis when these cells originate from a solid tumor. When it is related to a systemic lymphoma, it is called lymphomatous meningitis, and when associated with leukemia, it is termed leukemic meningitis. Leptomeningeal metastasis occurs in approximately 5% of patients with cancer.³³³ This disorder is being diagnosed with increasing frequency as patients live longer and as neuroimaging studies improve. Most cases arise from breast and lung cancers; melanoma has the highest rate of leptomeningeal spread.^{334,335}

Tumor cells gain access to the leptomeninges by hematogenous dissemination, lymphatic spread, or direct extension. Once these cells reach the CSF, they are disseminated throughout the neuraxis by the constant flow of CSF. Infiltration of the leptomeninges by any malignancy is a serious complication that results in substantial morbidity and mortality. Cranial nerve palsies, headaches, cerebral disturbances, mental changes, and motor weakness are among the most common presenting symptoms.³³³ The median survival of patients diagnosed

with this disorder is <3 months with death resulting from progressive neurologic dysfunction, but may be extended by early detection and intervention.^{334,335}

Treatment Overview

The goals of treatment in patients with leptomeningeal metastases are to improve or stabilize the neurologic status of the patient and to prolong survival. Unfortunately, there is a lack of standard treatments due to meager evidence in literature. Because treatment is palliative, aggressive chemotherapy should only be given to patients most likely to benefit (see *Patient Stratification*).

Radiation Therapy

RT is mainly given for symptom alleviation, CSF flow correction, or for debulking to facilitate chemotherapy.³³⁵⁻³³⁷

Surgery

The role of neurosurgery for leptomeningeal metastases is mainly to place an intraventricular catheter and subcutaneous reservoir for drug administration.³³⁸ This is preferred over lumbar punctures because of improved drug delivery, safety, superior pharmacokinetics, lower inter-patient variability, and patient comfort.³³⁹

Systemic Therapy

Chemotherapy can reach the whole neuraxis and can improve outcome of patients. Intrathecal (intra-CSF) chemotherapy is widely used, although drugs with good CNS penetration, particularly organ-specific targeted therapies, may be administered systemically in high doses. Intrathecal therapy can involve either administration via a lumbar puncture or intraventricular injections via an Ommaya reservoir. However, both intra-CSF therapy and high-dose systemic therapy are

associated with significant toxicity or complications and are therefore restricted to patients with good PS.

Agents used for intra-CSF therapy are often organ-specific with good penetration capacity. The panel included options deemed appropriate based on moderate benefit: methotrexate for breast cancer, lymphoma, and leukemia³⁴⁰⁻³⁴²; cytarabine and liposomal cytarabine for lymphoma and leukemia³⁴¹; thiotepa,³⁴² rituximab for lymphoma³⁴³; topotecan³⁴⁴; etoposide³⁴⁵; trastuzumab for breast cancer³⁴⁶; and interferon alfa.³⁴⁷ Interferon alfa received a category 2B designation due to concerns of its toxicity and limited evidence of efficacy.

Breast cancers³²¹ and lymphomas³⁴⁸ are also particularly responsive to high-dose methotrexate. In addition, weekly pulse erlotinib has been used for metastatic non-small cell lung cancer with EGFR exon 19 or exon 21 deletions (category 2B).³⁴⁹

NCCN Recommendations

Patient Evaluation

Patients present with signs and symptoms ranging from injury to nerves that traverse the subarachnoid space, direct tumor invasion of the brain or spinal cord, alter the local blood supply, obstruct normal CSF flow pathways leading to increased intracranial pressure, or interfere with normal brain function. Patients should have a physical examination with a careful neurologic evaluation and neuraxis imaging. MRI of the brain and spine should also be performed if intra-CSF chemotherapy is being considered. A definitive diagnosis is most commonly made by lumbar puncture if it is safe for the patient. The CSF protein is typically increased, and there may be a pleocytosis or decreased glucose levels. The CSF cytology is positive approximately 50% of the time with the first lumbar puncture, and 90% of the time after repeated CSF examinations in affected patients.³³⁷ Clinicians should be aware that

lumbar punctures may be contraindicated in patients with anticoagulation, thrombocytopenia, or bulky intracranial disease. In these cases, suspicious CSF biochemical results combined with suggestive clinical and/or radiologic features should be taken into consideration. Although a positive CSF cytology in patients with solid tumors is virtually always diagnostic, reactive lymphocytes from infections (for example, herpes zoster infection) can often be mistaken for malignant lymphocytes.

Patient Stratification

Once the diagnosis has been established, the patient's overall status should be carefully assessed to determine how aggressively the carcinomatous or lymphomatous meningitis should be treated. Unfortunately, this disease is most common in patients with advanced, treatment-refractory systemic malignancies for whom treatment options are limited. In general, fixed neurologic deficits (such as cranial nerve palsies or paraplegia) do not resolve with therapy, although encephalopathies may improve dramatically. As a result, patients should be stratified into "poor-risk" and "good-risk" groups. The poor-risk group includes patients with KPS below 60; multiple, serious, major neurologic deficits; extensive systemic disease with few treatment options; bulky CNS disease; and neoplastic meningitis related to encephalopathy. The good-risk group includes patients with KPS greater than or equal to 60, no major neurologic deficits, minimal systemic disease, and reasonable systemic treatment options. Many patients fall in between these 2 groups, and clinical judgment will dictate how aggressive their treatment should be.

Treatment

Patients in the poor-risk group are usually offered palliative/supportive care measures. Fractionated EBRT to symptomatic sites (eg, to the

whole brain for increased intracranial pressure or to the lumbosacral spine for a developing cauda equina syndrome) can be considered.

Good-risk patients should receive fractionated EBRT to symptomatic sites and to areas of bulky disease identified on neuroimaging studies. If an intraventricular catheter was placed, a CSF flow scan should be strongly considered to ensure correct flow of chemotherapy.

For patients with a normal CSF flow scan and otherwise stable disease, surgical implantation of a subcutaneous reservoir and ventricular catheter (SRVC) should be considered for intrathecal chemotherapy administration. Induction intrathecal chemotherapy should be given for 4 to 6 weeks. Alternately, patients with breast cancer or lymphoma may receive high-dose methotrexate or craniospinal RT. Craniospinal RT is also an appropriate option for patients with leukemia. The patient should be reassessed clinically and with a repeat CSF cytology. Because the cytology is much less likely to be positive from the SRVC than from the lumbar subarachnoid space, it is critical that it be sampled from the lumbar spine. Neuraxis imaging can also be considered for sites that were previously positive on a radiograph.

If negative cytology is achieved after induction, continue the induction chemotherapy for another month before switching to maintenance intrathecal chemotherapy. The CSF cytology status should be followed every month. If the patient is clinically stable or improving after induction and there is no clinical or radiologic evidence of progressive leptomeningeal disease, the patient should receive another 4 weeks of "induction" intrathecal chemotherapy or should consider switching intrathecal drugs for 4 weeks. This regimen should be followed by maintenance therapy and monthly cytology if the cytology has converted to negative or is improving (still positive) while the patient is clinically stable.

CSF flow abnormalities are common in patients with neoplastic meningitis and often lead to increased intracranial pressure. Administering chemotherapy into the ventricle of a patient with a ventricular outlet obstruction increases the patient's risk for leukoencephalopathy. In addition, the agent administered will not reach the lumbar subarachnoid space where the original CSF cytology was positive. CSF flow scans are easily performed in most nuclear medicine departments. Indium-111-DTPA is administered into the SRVC, imaging of the brain and spine is performed immediately after injection, and then imaging is done again at 4 and 24 hours. If significant flow abnormalities are seen, fractionated EBRT can be administered to the sites of obstruction before repeating a CSF flow scan. High-dose methotrexate remains an option for patients with breast cancer or lymphoma, as normal CSF flow is not required to reach cytotoxic concentrations. Patients with breast cancer, leukemia, or lymphoma may receive craniospinal RT as an alternative. If CSF flow normalizes after RT, which occurs most commonly in radiosensitive neoplasms, intrathecal chemotherapy commences. If significant flow abnormalities remain, then the patient should be treated as a poor-risk patient (ie, with supportive measures or RT).

Progressive Disease

If the patient's clinical status is deteriorating from progressive leptomeningeal disease or if the cytology is persistently positive, the clinician has several options: 1) RT to symptom sites, 2) systemic chemotherapy, or 3) palliative or best supportive care.

Metastatic Spinal Tumors

Bone metastases are a growing problem among cancer patients due to increasing life expectancy, with the spine being the most frequently affected site. In a report of 832 patients who died of malignancies,

vertebral involvement was found in 36% upon autopsy.³⁵⁰ Spinal metastases primarily arise from breast, lung, prostate, and renal cancers.^{351,352} Extradural lesions account for about 95% of spinal tumors, mostly in the thoracic region.

Some patients are found to have vertebral involvement as an asymptomatic, incidental finding. However, for most affected patients, pain is the primary presenting symptom preceding neurologic dysfunction. Three types of pain have been classically defined. Local pain due to tumor growth is often described as a constant, deep aching that improves with steroid medications. Mechanical back pain varies with movement and position and is attributed to structural spinal instability. While seldom responsive to steroids, mechanical pain can be alleviated by surgical stabilization. Radicular pain is a sharp or stabbing sensation that occurs when nerve roots are compressed by the tumor. Patients may experience any one or a combination of these types of pain.

Spinal cord compression is the most debilitating complication of spine metastases. It affects 5% to 10% of all patients with cancer, with more than 20,000 cases diagnosed each year in the United States.³⁵³ The majority of patients initially complain of progressive radicular pain.³⁵⁴ This is followed by neurologic symptoms such as motor weakness and sensory loss, and may even include autonomic bladder dysfunction. If left untreated, neurologic deficits rapidly progress to paralysis. Unfortunately, a study of 319 patients with cord compression revealed significant delay in the report of initial pain (3 months) as well as diagnosis (2 months) that can lead to irreversible spinal cord damage.³⁵⁵ Therefore, it is paramount that the clinician watches for early suspicious signs and establishes prompt diagnosis by spine MRI. Once diagnosed, spinal cord compression is considered a medical

emergency; intervention should be implemented immediately to prevent further neurologic decline.

Treatment Overview

Dissemination to the spinal column is largely incurable. Therefore, the goals of treatment are palliation and improvement of quality of life through preservation of neurologic function, pain relief, and stabilization of mechanical structure. One exception is slow-growing cancers (mainly renal cell carcinoma) with solitary spinal metastasis, for which surgery may achieve possible cure.³⁵⁶

The type and aggressiveness of the primary tumor often dictates the choice of treatment, as different cancers have varying sensitivities to systemic therapy and RT. In addition, patient characteristics including PS and comorbidities will determine whether they can tolerate surgery and, if so, which surgical technique should be used.

Surgery

There is general consensus that a patient should have a life expectancy of at least three months to be a surgical candidate. Paraplegia for over 24 hours is an exclusion criterion due to low chances of improvement when prolonged neurologic deficits exist before surgery.³⁵⁷ Patients with hematologic malignancies should also be excluded, as they are best managed by RT or chemotherapy. Because estimation of life expectancy can be difficult, several groups have developed prognostic scoring systems to help predict surgical outcomes.³⁵⁸⁻³⁶¹

Posterior laminectomy has been widely used in the past but is now obsolete due to frequent complications and lack of benefit. Modern surgical techniques enable surgeons to achieve 360° decompression of the spinal cord, and stabilization can be performed concomitantly, if required. The development of a plethora of spinal implants composed of

high-quality materials such as titanium greatly improve reconstruction outcome. The surgical approach—anterior, posterior, or combined/circumferential—is primarily determined by disease anatomy.^{362,363}

Sundaresan and colleagues³⁵⁶ reported favorable results using a variety of surgical approaches on 80 patients with solitary spine metastases. Both pain and mobility were improved in the majority of patients. Overall survival reached 30 months, with 18% of patients surviving 5 years or more. The best outcome was observed in patients with kidney and breast cancers.

Surgery followed by adjuvant EBRT has emerged as a highly effective approach in relieving spinal cord compression and restoring function, especially for solid tumors. A meta-analysis including 24 surgery cohort studies and 4 RT studies found that patients are twice as likely to regain ambulatory function after surgery than RT alone.³⁶⁴ However, data also revealed significant surgery-related mortality (6.3%) and morbidity (23%). In another review of literature from 1964 to 2005, anterior decompression with stabilization plus RT was associated with superior outcome over RT alone or laminectomy, achieving 75% mean improvement in neurologic function. However, high surgical mortality rate (mean 10%) was also reported.³⁶⁵

To date, only one relevant randomized trial has been reported.³⁶⁶ Approximately 100 patients with metastatic spinal compression were randomized to surgery plus postoperative RT or RT alone. Compared to the RT group, significantly more patients in the surgery group regained walking ability (84% vs. 57%; $P = .001$) and for a longer period of time (median 122 days vs. 13 days; $P = .003$). The impressive results were obtained with strict eligibility criteria. The study excluded patients with radiosensitive tumors, neurologic deficits for 24 hours, multiple spinal

tumors, lesions only compressing spinal roots, and prior RT to the vertebrae. Although studies demonstrated high efficacy of surgery, the formidable complications related to surgery cannot be overlooked. Using the Nationwide Inpatient Sample all-payor database, Patil et al³⁶⁷ reviewed data of over 26,000 patients who had undergone surgery for spinal metastases. The in-hospital mortality and complication rates were 5.6% and 22%, respectively. The most common complications were pulmonary (6.7%) and hemorrhages or hematomas (5.9%). Clearly, careful individual patient selection based on life expectancy and overall health is warranted.

Radiation Therapy

Traditionally, EBRT has been the main form of treatment for spinal metastases. In the modern surgery era, RT alone is often not sufficient in achieving decompression or stabilization (see above), but it is routinely used as adjuvant therapy following surgery as it is difficult to obtain wide negative margins. Given the potential impact of RT on wound healing, most studies posed an interval of one to three weeks between resection and subsequent RT.³⁶⁸

An excellent response to RT alone for spinal compression was reported by Marazano and colleagues.³⁶⁹ Three hundred patients were randomized to a short-course (8 Gy x 2 days) or split-course (5 Gy x 3 days; 3 Gy x 5 days) schedule. After RT, 35% of nonambulatory patients regained walking ability, and pain relief was recorded in 57% of patients with a median survival of 4 months. Efficacy of RT was highly dependent on the histology: 70% of nonambulatory breast cancer patients recovered mobility compared to only 20% of hepatocellular carcinoma patients. In general, solid tumors are considered either moderately radiosensitive (eg, breast and prostate cancers) or radioresistant (eg, melanoma; osteosarcomas; cancers of the thyroid, colon, and kidney).³⁷⁰ On the other hand, hematologic malignancies

such as lymphomas and multiple myelomas are highly responsive to RT. Hence, RT alone is routinely utilized as therapy for these cancers, even in the presence of cord compression.

Where there is no compression, fracture, or instability, EBRT is effective in achieving local control as primary treatment. A mean 77% local control rate from seven retrospective studies including 885 patients was found in a systematic review by Gerszten and colleagues.³⁷⁰ RT is also a mainstay of palliative treatment for patients with poor PS, significant comorbidities, and/or limited life expectancy (<3–4 months). Klimo's meta-analysis, including 543 patients treated by RT, revealed pain control rates of 54% to 83%.³⁶⁴ Unlike surgery, RT has no immediate significant treatment-related complications and very few local recurrences. However, it increases surgical complications as it impairs wound healing.

The advent of SRS allowed precise high-dose targeting in one or two fractions while minimizing exposure of the surrounding cord. This is especially important in pre-irradiated patients. The largest prospective study involved a cohort of nearly 400 patients with 500 spinal metastases, 70% of which had previous conventional irradiation.³⁷¹ At a median follow-up of 21 months, radiosurgery resulted in long-term pain improvement and tumor control in 85% and 90% of cases, respectively. Other single-institution reports also suggest that SRS is safe and offers more durable response than conventional therapy.³⁷⁰ An ongoing phase II/III trial (RTOG 0631) is comparing single-dose stereotactic RT of 16 Gy to single-dose EBRT of 8 Gy in patients with 1 to 3 spinal metastases.

Vertebral Augmentation

Percutaneous vertebroplasty and kyphoplasty involve injection of cement (polymethyl methacrylate) into the vertebral body.

Vertebroplasty is a direct injection, while kyphoplasty involves inserting a balloon that provides a cavity for the injection. These vertebral augmentation procedures immediately reinforce and stabilize the column, thereby relieving pain and preventing further fractures.³⁷² They are suitable in poor surgical candidates with painful fractures, but are relatively contraindicated in the case of spinal cord compression because they do not achieve decompression. Symptomatic complications occur in up to 8% of patients (mostly with vertebroplasty), including embolization of the cement and local metastasis along the needle tract.

Systemic Therapy

Corticosteroids remain a routine initial prescription for patients presenting with cord compression, with a number of theoretical benefits including anti-inflammation, reduction in edema, short-term neurologic function improvement, and enhanced blood flow. However, the preference between high-dose (96 mg daily) and low-dose (10–16 mg daily) is still unclear.³⁷³⁻³⁷⁵

Chemotherapy has a limited role in metastatic spinal tumors except for chemosensitive tumors such as lymphoma, myeloma, and germ cell tumor. Agents efficacious for the primary tumor are used.

NCCN Recommendations

Workup

Initial workup depends on the presence or absence of symptoms. Patients with an incidental, asymptomatic, metastatic lesion confirmed by systemic imaging can be observed with MRI. However, biopsy and further treatment of an incidental lesion are indicated if treatment of the patient is altered as a result of treatment of the incidental lesion. In the absence of symptoms, it is not mandatory to obtain a spinal MRI for every incidental metastatic lesion seen on surveillance bone scans. The

alternate category involves severe or new back pain. Increasing intensity, duration, and changes in the character of pain should trigger an evaluation with an MRI study, even in patients with pre-existing degenerative spine conditions. Immediate spinal MRI is warranted in the occurrence of neurologic symptoms including weakness, paresthesias, and bladder or bowel incontinence. Contrast can be used to highlight and further evaluate any focal abnormality. The MRI can be used to image the entire spine or a focal area of interest. If the patient is unable to have an MRI, then a CT myelogram is recommended.

A normal neurologic examination implies that there is no spinal radiculopathy or myelopathy correlating with the patient's symptoms. In this case, other causes should be considered (eg, leptomeningeal disease). An abnormal neurologic examination includes motor abnormalities, sphincter abnormalities, and/or sensory deficits attributable to a dysfunction of nerve root(s) and/or the spinal cord. Therefore, detection of radiculopathy, myelopathy, or cauda equina syndrome is indicative of an abnormal examination. However, reflex asymmetry and/or presence of pathologic reflexes, as well as sensory deficits of a stocking/glove distribution are excluded.

Treatment

Once metastatic vertebral involvement is diagnosed, treatment is based on whether the patient is suffering from spinal cord compression, fracture, or spinal instability. In the presence of multiple metastatic spinal tumors, the one causing the patient's main symptoms is addressed first. Additional tumors can be treated at a later point according to the algorithm.

Radiographic spinal cord compression implies deformation of the spinal cord because of epidural tumor, retropulsed bone fragment, or both. It should be noted that epidural tumor may occupy part of the spinal canal

with or without partial obliteration of CSF around the spinal cord. Those cases are excluded because there is no cord deformation. For tumors occurring below L1, any canal compression of 50% or more should be considered of equal importance as spinal cord compression. Patients with radiographic cord compression should start on dexamethasone (10–100 mg) to alleviate symptoms. Decompressive surgery (concomitant stabilization if indicated) and adjuvant RT is the preferred treatment (category 1) where there is spinal instability and no surgical contraindication. Primary EBRT alone is appropriate for patients with radiosensitive cancers (hematologic malignancies) and without evidence of spinal instability. Many fractionation schemes are available (15–40 Gy in 1–15 fractions over 1 day–3 weeks); the most common is a total of 30 Gy in 3-Gy daily fractions for 10 days.^{376,377} Tolerance at the spine and/or nerve route must be considered in determining dose. Primary chemotherapy is also an option for chemo-responsive tumors in the absence of clinical myelopathy. In general, a treatment interval of at least 6 months is recommended.

Metastases to the spine without cord compression include the presence of tumor in the vertebral body, pedicle(s), lamina, transverse, or spinous process. It can also include epidural disease without cord deformation. Patients in this category should be assessed for fractures and spinal instability. Because the criteria for spinal destabilization secondary to tumor remain unclear, consultation by a surgeon is recommended. *Spinal instability* is grossly defined as the presence of significant kyphosis or spondylolisthesis (deformity) or of significantly retropulsed bone fragment. Not every pathologic fracture implies unstable structure. The degree of kyphosis or spondylolisthesis compatible with instability depends on the location of the tumor in the spine. The cross-sectional area of the vertebral body unaffected by the tumor and the patient's bone mineral density are additional factors affecting stability. In addition, vertebral

body involvement is more important than dorsal element involvement with regard to stability. Circumferential disease as well as junctional and contiguous tumor location should be taken into account when assessing spinal stability. If fracture or instability is detected, the patient should undergo surgical stabilization or minimally invasive vertebral augmentation to relieve pain. These procedures should be followed by adjuvant RT to obtain local control.

If no fracture or instability is found, EBRT is the treatment of choice. Stereotactic RT may be appropriate in select cases of limited disease. Other alternatives are chemotherapy for responsive tumors, or surgery plus adjuvant RT in select cases. Patients experiencing intractable pain or rapid neurologic decline during RT should consider surgery or SRS. Neurologic deterioration is apparent when the patient's neurologic examination is becoming worse on a daily basis and the patient's ambulatory status is threatened. Intractable pain means either that pain is not controlled with oral analgesics or that the patient cannot tolerate the medication due to side effects.

Progression and Recurrence

Follow-up involves MRI or CT imaging within one to three months post-treatment, then every three to six months as indicated. Upon detection of progression or recurrence on imaging scans, management strategy is based on previous treatment. Patients who underwent prior RT or surgery plus adjuvant RT may consider surgery or re-irradiation to the recurred area. Stereotactic RT may be appropriate for select patients. Clinicians should plan 6 months or more between treatments in consideration of tolerance of the spine and its nerve roots. Retreatment dose should be limited to no more than 10 Gy to the surface of the spinal cord. Patients previously treated by chemotherapy can consider RT.

References

1. Siegel RL, Miller KD, Jemal A. Cancer statistics, 2018. *CA Cancer J Clin* 2018;68:7-30. Available at: <https://www.ncbi.nlm.nih.gov/pubmed/29313949>.
2. Maher EA, McKee AC. Neoplasms of the central nervous system. In: Skarin AT, Canellos GP, eds. *Atlas of diagnostic oncology* (ed 3rd). London, United Kingdom: Elsevier Science Ltd; 2003.
3. Louis DN, Perry A, Reifenberger G, et al. The 2016 World Health Organization Classification of Tumors of the Central Nervous System: a summary. *Acta Neuropathol* 2016;131:803-820. Available at: <http://www.ncbi.nlm.nih.gov/pubmed/27157931>.
4. Sawaya R, Hammoud M, Schoppa D, et al. Neurosurgical outcomes in a modern series of 400 craniotomies for treatment of parenchymal tumors. *Neurosurgery* 1998;42:1044-1055; discussion 1055-1046. Available at: <http://www.ncbi.nlm.nih.gov/pubmed/9588549>.
5. Yan H, Parsons DW, Jin G, et al. IDH1 and IDH2 mutations in gliomas. *N Engl J Med* 2009;360:765-773. Available at: <http://www.ncbi.nlm.nih.gov/pubmed/19228619>.
6. Houillier C, Wang X, Kaloshi G, et al. IDH1 or IDH2 mutations predict longer survival and response to temozolomide in low-grade gliomas. *Neurology* 2010;75:1560-1566. Available at: <https://www.ncbi.nlm.nih.gov/pubmed/20975057>.
7. Cancer Genome Atlas Research Network, Brat DJ, Verhaak RG, et al. Comprehensive, integrative genomic analysis of diffuse lower-grade gliomas. *N Engl J Med* 2015;372:2481-2498. Available at: <http://www.ncbi.nlm.nih.gov/pubmed/26061751>.
8. Eckel-Passow JE, Lachance DH, Molinaro AM, et al. Glioma groups based on 1p/19q, IDH, and TERT promoter mutations in tumors. *N Engl J Med* 2015;372:2499-2508. Available at: <http://www.ncbi.nlm.nih.gov/pubmed/26061753>.
9. Wiestler B, Capper D, Sill M, et al. Integrated DNA methylation and copy-number profiling identify three clinically and biologically relevant groups of anaplastic glioma. *Acta Neuropathol* 2014;128:561-571. Available at: <https://www.ncbi.nlm.nih.gov/pubmed/25008768>.
10. Weller M, Weber RG, Willscher E, et al. Molecular classification of diffuse cerebral WHO grade II/III gliomas using genome- and transcriptome-wide profiling improves stratification of prognostically distinct patient groups. *Acta Neuropathol* 2015;129:679-693. Available at: <https://www.ncbi.nlm.nih.gov/pubmed/25783747>.
11. Gorovets D, Kannan K, Shen R, et al. IDH mutation and neuroglial developmental features define clinically distinct subclasses of lower grade diffuse astrocytic glioma. *Clin Cancer Res* 2012;18:2490-2501. Available at: <https://www.ncbi.nlm.nih.gov/pubmed/22415316>.
12. Gravendeel LA, Kouwenhoven MC, Gevaert O, et al. Intrinsic gene expression profiles of gliomas are a better predictor of survival than histology. *Cancer Res* 2009;69:9065-9072. Available at: <https://www.ncbi.nlm.nih.gov/pubmed/19920198>.
13. Everhard S, Kaloshi G, Criniere E, et al. MGMT methylation: a marker of response to temozolomide in low-grade gliomas. *Ann Neurol* 2006;60:740-743. Available at: <http://www.ncbi.nlm.nih.gov/pubmed/17192931>.
14. Kaloshi G, Benouaich-Amiel A, Diakite F, et al. Temozolomide for low-grade gliomas: predictive impact of 1p/19q loss on response and outcome. *Neurology* 2007;68:1831-1836. Available at: <http://www.ncbi.nlm.nih.gov/pubmed/17515545>.
15. Hartmann C, Meyer J, Balss J, et al. Type and frequency of IDH1 and IDH2 mutations are related to astrocytic and oligodendroglial differentiation and age: a study of 1,010 diffuse gliomas. *Acta Neuropathol* 2009;118:469-474. Available at: <https://www.ncbi.nlm.nih.gov/pubmed/19554337>.

16. Nitta M, Muragaki Y, Maruyama T, et al. Proposed therapeutic strategy for adult low-grade glioma based on aggressive tumor resection. *Neurosurg Focus* 2015;38:E7. Available at: <https://www.ncbi.nlm.nih.gov/pubmed/25599276>.

17. Baumert BG, Hegi ME, van den Bent MJ, et al. Temozolomide chemotherapy versus radiotherapy in high-risk low-grade glioma (EORTC 22033-26033): a randomised, open-label, phase 3 intergroup study. *Lancet Oncol* 2016;17:1521-1532. Available at: <https://www.ncbi.nlm.nih.gov/pubmed/27686946>.

18. Sanson M, Marie Y, Paris S, et al. Isocitrate dehydrogenase 1 codon 132 mutation is an important prognostic biomarker in gliomas. *J Clin Oncol* 2009;27:4150-4154. Available at: <https://www.ncbi.nlm.nih.gov/pubmed/19636000>.

19. Sahm F, Reuss D, Koelsche C, et al. Farewell to oligoastrocytoma: in situ molecular genetics favor classification as either oligodendroglioma or astrocytoma. *Acta Neuropathol* 2014;128:551-559. Available at: <https://www.ncbi.nlm.nih.gov/pubmed/25143301>.

20. Olar A, Wani KM, Alfaro-Munoz KD, et al. IDH mutation status and role of WHO grade and mitotic index in overall survival in grade II-III diffuse gliomas. *Acta Neuropathol* 2015;129:585-596. Available at: <https://www.ncbi.nlm.nih.gov/pubmed/25701198>.

21. Pai T, Epari S, Desai S, et al. Histological spectrum of oligodendroglial tumors: Only a subset shows 1p/19q codeletion. *Neurol India* 2017;65:113-120. Available at: <https://www.ncbi.nlm.nih.gov/pubmed/28084254>.

22. Neumann JE, Dorostkar MM, Korshunov A, et al. Distinct histomorphology in molecular subgroups of glioblastomas in young patients. *J Neuropathol Exp Neurol* 2016;75:408-414. Available at: <https://www.ncbi.nlm.nih.gov/pubmed/26975364>.

23. Dubbink HJ, Atmodimedjo PN, Kros JM, et al. Molecular classification of anaplastic oligodendroglioma using next-generation

sequencing: a report of the prospective randomized EORTC Brain Tumor Group 26951 phase III trial. *Neuro Oncol* 2016;18:388-400. Available at: <http://www.ncbi.nlm.nih.gov/pubmed/26354927>.

24. Labussiere M, Idbaih A, Wang XW, et al. All the 1p19q codeleted gliomas are mutated on IDH1 or IDH2. *Neurology* 2010;74:1886-1890. Available at: <https://www.ncbi.nlm.nih.gov/pubmed/20427748>.

25. Horbinski C. What do we know about IDH1/2 mutations so far, and how do we use it? *Acta Neuropathol* 2013;125:621-636. Available at: <https://www.ncbi.nlm.nih.gov/pubmed/23512379>.

26. Jiao Y, Killela PJ, Reitman ZJ, et al. Frequent ATRX, CIC, FUBP1 and IDH1 mutations refine the classification of malignant gliomas. *Oncotarget* 2012;3:709-722. Available at: <https://www.ncbi.nlm.nih.gov/pubmed/22869205>.

27. Leeper HE, Caron AA, Decker PA, et al. IDH mutation, 1p19q codeletion and ATRX loss in WHO grade II gliomas. *Oncotarget* 2015;6:30295-30305. Available at: <https://www.ncbi.nlm.nih.gov/pubmed/26210286>.

28. Reuss DE, Sahm F, Schrimpf D, et al. ATRX and IDH1-R132H immunohistochemistry with subsequent copy number analysis and IDH sequencing as a basis for an "integrated" diagnostic approach for adult astrocytoma, oligodendroglioma and glioblastoma. *Acta Neuropathol* 2015;129:133-146. Available at: <https://www.ncbi.nlm.nih.gov/pubmed/25427834>.

29. Arita H, Narita Y, Fukushima S, et al. Upregulating mutations in the TERT promoter commonly occur in adult malignant gliomas and are strongly associated with total 1p19q loss. *Acta Neuropathol* 2013;126:267-276. Available at: <https://www.ncbi.nlm.nih.gov/pubmed/23764841>.

30. Killela PJ, Reitman ZJ, Jiao Y, et al. TERT promoter mutations occur frequently in gliomas and a subset of tumors derived from cells

with low rates of self-renewal. Proc Natl Acad Sci U S A 2013;110:6021-6026. Available at: <https://www.ncbi.nlm.nih.gov/pubmed/23530248>.

31. Meyronet D, Esteban-Mader M, Bonnet C, et al. Characteristics of H3 K27M-mutant gliomas in adults. Neuro Oncol 2017;19:1127-1134. Available at: <https://www.ncbi.nlm.nih.gov/pubmed/28201752>.

32. Jiang H, Cui Y, Wang J, Lin S. Impact of epidemiological characteristics of supratentorial gliomas in adults brought about by the 2016 world health organization classification of tumors of the central nervous system. Oncotarget 2017;8:20354-20361. Available at: <https://www.ncbi.nlm.nih.gov/pubmed/27888628>.

33. Wick W, Roth P, Hartmann C, et al. Long-term analysis of the NOA-04 randomized phase III trial of sequential radiochemotherapy of anaplastic glioma with PCV or temozolomide. Neuro Oncol 2016;18:1529-1537. Available at: <https://www.ncbi.nlm.nih.gov/pubmed/27370396>.

34. Cairncross JG, Wang M, Jenkins RB, et al. Benefit from procarbazine, lomustine, and vincristine in oligodendroglial tumors is associated with mutation of IDH. J Clin Oncol 2014;32:783-790. Available at: <http://www.ncbi.nlm.nih.gov/pubmed/24516018>.

35. Gorlia T, Delattre JY, Brandes AA, et al. New clinical, pathological and molecular prognostic models and calculators in patients with locally diagnosed anaplastic oligodendroglioma or oligoastrocytoma. A prognostic factor analysis of European Organisation for Research and Treatment of Cancer Brain Tumour Group Study 26951. Eur J Cancer 2013;49:3477-3485. Available at: <http://www.ncbi.nlm.nih.gov/pubmed/23896377>.

36. Chang S, Zhang P, Cairncross JG, et al. Phase III randomized study of radiation and temozolomide versus radiation and nitrosourea therapy for anaplastic astrocytoma: results of NRG Oncology RTOG 9813. Neuro Oncol 2017;19:252-258. Available at: <https://www.ncbi.nlm.nih.gov/pubmed/27994066>.

37. Hartmann C, Hentschel B, Wick W, et al. Patients with IDH1 wild type anaplastic astrocytomas exhibit worse prognosis than IDH1-mutated glioblastomas, and IDH1 mutation status accounts for the unfavorable prognostic effect of higher age: implications for classification of gliomas. Acta Neuropathol 2010;120:707-718. Available at: <https://www.ncbi.nlm.nih.gov/pubmed/21088844>.

38. Chan AK, Yao Y, Zhang Z, et al. Combination genetic signature stratifies lower-grade gliomas better than histological grade. Oncotarget 2015;6:20885-20901. Available at: <https://www.ncbi.nlm.nih.gov/pubmed/26369702>.

39. Wahl M, Phillips JJ, Molinaro AM, et al. Chemotherapy for adult low-grade gliomas: clinical outcomes by molecular subtype in a phase II study of adjuvant temozolomide. Neuro Oncol 2017;19:242-251. Available at: <https://www.ncbi.nlm.nih.gov/pubmed/27571885>.

40. Arita H, Yamasaki K, Matsushita Y, et al. A combination of TERT promoter mutation and MGMT methylation status predicts clinically relevant subgroups of newly diagnosed glioblastomas. Acta Neuropathol Commun 2016;4:79. Available at: <https://www.ncbi.nlm.nih.gov/pubmed/27503138>.

41. Pekmezci M, Rice T, Molinaro AM, et al. Adult infiltrating gliomas with WHO 2016 integrated diagnosis: additional prognostic roles of ATRX and TERT. Acta Neuropathol 2017;133:1001-1016. Available at: <https://www.ncbi.nlm.nih.gov/pubmed/28255664>.

42. Mollemann M, Wolter M, Felsberg J, et al. Frequent promoter hypermethylation and low expression of the MGMT gene in oligodendroglial tumors. Int J Cancer 2005;113:379-385. Available at: <http://www.ncbi.nlm.nih.gov/pubmed/15455350>.

43. Hegi ME, Diserens AC, Gorlia T, et al. MGMT gene silencing and benefit from temozolomide in glioblastoma. N Engl J Med 2005;352:997-1003. Available at: <http://www.ncbi.nlm.nih.gov/pubmed/15758010>.

44. Hegi ME, Diserens AC, Godard S, et al. Clinical trial substantiates the predictive value of O-6-methylguanine-DNA methyltransferase promoter methylation in glioblastoma patients treated with temozolomide. *Clin Cancer Res* 2004;10:1871-1874. Available at: <https://www.ncbi.nlm.nih.gov/pubmed/15041700>.
45. Malmstrom A, Gronberg BH, Marosi C, et al. Temozolomide versus standard 6-week radiotherapy versus hypofractionated radiotherapy in patients older than 60 years with glioblastoma: the Nordic randomised, phase 3 trial. *Lancet Oncol* 2012;13:916-926. Available at: <http://www.ncbi.nlm.nih.gov/pubmed/22877848>.
46. Wick W, Platten M, Meisner C, et al. Temozolomide chemotherapy alone versus radiotherapy alone for malignant astrocytoma in the elderly: the NOA-08 randomised, phase 3 trial. *Lancet Oncol* 2012;13:707-715. Available at: <http://www.ncbi.nlm.nih.gov/pubmed/22578793>.
47. Khuong-Quang DA, Buczkowicz P, Rakopoulos P, et al. K27M mutation in histone H3.3 defines clinically and biologically distinct subgroups of pediatric diffuse intrinsic pontine gliomas. *Acta Neuropathol* 2012;124:439-447. Available at: <https://www.ncbi.nlm.nih.gov/pubmed/22661320>.
48. Sturm D, Witt H, Hovestadt V, et al. Hotspot mutations in H3F3A and IDH1 define distinct epigenetic and biological subgroups of glioblastoma. *Cancer Cell* 2012;22:425-437. Available at: <https://www.ncbi.nlm.nih.gov/pubmed/23079654>.
49. Horbinski C. To BRAF or not to BRAF: is that even a question anymore? *J Neuropathol Exp Neurol* 2013;72:2-7. Available at: <https://www.ncbi.nlm.nih.gov/pubmed/23242278>.
50. Penman CL, Faulkner C, Lowis SP, Kurian KM. Current understanding of BRAF alterations in diagnosis, prognosis, and therapeutic targeting in pediatric low-grade gliomas. *Front Oncol* 2015;5:54. Available at: <http://na1.replicon.com/NCCN/main.aspx>.
51. Hawkins C, Walker E, Mohamed N, et al. BRAF-KIAA1549 fusion predicts better clinical outcome in pediatric low-grade astrocytoma. *Clin Cancer Res* 2011;17:4790-4798. Available at: <https://www.ncbi.nlm.nih.gov/pubmed/21610142>.
52. Horbinski C, Nikiforova MN, Hagenkord JM, et al. Interplay among BRAF, p16, p53, and MIB1 in pediatric low-grade gliomas. *Neuro Oncol* 2012;14:777-789. Available at: <https://www.ncbi.nlm.nih.gov/pubmed/22492957>.
53. Mistry M, Zhukova N, Merico D, et al. BRAF mutation and CDKN2A deletion define a clinically distinct subgroup of childhood secondary high-grade glioma. *J Clin Oncol* 2015;33:1015-1022. Available at: <https://www.ncbi.nlm.nih.gov/pubmed/25667294>.
54. Chapman PB, Hauschild A, Robert C, et al. Improved survival with vemurafenib in melanoma with BRAF V600E mutation. *N Engl J Med* 2011;364:2507-2516. Available at: <http://www.ncbi.nlm.nih.gov/pubmed/21639808>.
55. McArthur GA, Chapman PB, Robert C, et al. Safety and efficacy of vemurafenib in BRAF(V600E) and BRAF(V600K) mutation-positive melanoma (BRIM-3): extended follow-up of a phase 3, randomised, open-label study. *Lancet Oncol* 2014;15:323-332. Available at: <http://www.ncbi.nlm.nih.gov/pubmed/24508103>.
56. Pignatti F, van den Bent M, Curran D, et al. Prognostic factors for survival in adult patients with cerebral low-grade glioma. *J Clin Oncol* 2002;20:2076-2084. Available at: <http://www.ncbi.nlm.nih.gov/pubmed/11956268>.
57. Daniels TB, Brown PD, Felten SJ, et al. Validation of EORTC prognostic factors for adults with low-grade glioma: a report using intergroup 86-72-51. *Int J Radiat Oncol Biol Phys* 2011;81:218-224. Available at: <http://www.ncbi.nlm.nih.gov/pubmed/21549518>.
58. Karim AB, Maat B, Hatlevoll R, et al. A randomized trial on dose-response in radiation therapy of low-grade cerebral glioma: European

Organization for Research and Treatment of Cancer (EORTC) Study 22844. *Int J Radiat Oncol Biol Phys* 1996;36:549-556. Available at: <http://www.ncbi.nlm.nih.gov/pubmed/8948338>.

59. Lo SS, Cho KH, Hall WA, et al. Does the extent of surgery have an impact on the survival of patients who receive postoperative radiation therapy for supratentorial low-grade gliomas? *Int J Cancer* 2001;96 Suppl:71-78. Available at: <http://www.ncbi.nlm.nih.gov/pubmed/11992388>.

60. Shaw E, Arusell R, Scheithauer B, et al. Prospective randomized trial of low- versus high-dose radiation therapy in adults with supratentorial low-grade glioma: initial report of a North Central Cancer Treatment Group/Radiation Therapy Oncology Group/Eastern Cooperative Oncology Group study. *J Clin Oncol* 2002;20:2267-2276. Available at: <http://www.ncbi.nlm.nih.gov/pubmed/11980997>.

61. Lo SS, Hall WA, Cho KH, et al. Radiation dose response for supratentorial low-grade glioma--institutional experience and literature review. *J Neurol Sci* 2003;214:43-48. Available at: <http://www.ncbi.nlm.nih.gov/pubmed/12972387>.

62. Jeremic B, Milicic B, Grujicic D, et al. Hyperfractionated radiation therapy for incompletely resected supratentorial low-grade glioma: a 10-year update of a phase II study. *Int J Radiat Oncol Biol Phys* 2003;57:465-471. Available at: <http://www.ncbi.nlm.nih.gov/pubmed/12957258>.

63. Shaw EG, Berkey B, Coons SW, et al. Recurrence following neurosurgeon-determined gross-total resection of adult supratentorial low-grade glioma: results of a prospective clinical trial. *J Neurosurg* 2008;109:835-841. Available at: <http://www.ncbi.nlm.nih.gov/pubmed/18976072>.

64. Chang EF, Potts MB, Keles GE, et al. Seizure characteristics and control following resection in 332 patients with low-grade gliomas. *J Neurosurg* 2008;108:227-235. Available at: <http://www.ncbi.nlm.nih.gov/pubmed/18240916>.

65. Piepmeier J, Christopher S, Spencer D, et al. Variations in the natural history and survival of patients with supratentorial low-grade astrocytomas. *Neurosurgery* 1996;38:872-878; discussion 878-879. Available at: <http://www.ncbi.nlm.nih.gov/pubmed/8727811>.

66. Afra D, Osztie E, Sipos L, Vitanovics D. Preoperative history and postoperative survival of supratentorial low-grade astrocytomas. *Br J Neurosurg* 1999;13:299-305. Available at: <http://www.ncbi.nlm.nih.gov/pubmed/10562842>.

67. CBTRUS: Statistical report: Primary Brain Tumors in the United States, 1995-1999. Chicago: Central Brain Tumor Registry of the United States; 2002.

68. Philippon JH, Clemenceau SH, Fauchon FH, Foncin JF. Supratentorial low-grade astrocytomas in adults. *Neurosurgery* 1993;32:554-559. Available at: <http://www.ncbi.nlm.nih.gov/pubmed/8474646>.

69. Kang HC, Kim IH, Eom KY, et al. The role of radiotherapy in the treatment of newly diagnosed supratentorial low-grade oligodendrogliomas: comparative analysis with immediate radiotherapy versus surgery alone. *Cancer Res Treat* 2009;41:132-137. Available at: <http://www.ncbi.nlm.nih.gov/pubmed/19809562>.

70. Kaya V, Aksu MG, Korcum AF, et al. Clinical prognostic factors of adjuvant radiation therapy for low-grade gliomas: results of 10 years survival. *Int J Clin Exp Med* 2014;7:1336-1343. Available at: <http://www.ncbi.nlm.nih.gov/pubmed/24995092>.

71. Schomas DA, Laack NN, Rao RD, et al. Intracranial low-grade gliomas in adults: 30-year experience with long-term follow-up at Mayo Clinic. *Neuro Oncol* 2009;11:437-445. Available at: <http://www.ncbi.nlm.nih.gov/pubmed/19018039>.

72. Turkoglu E, Gurer B, Sanli AM, et al. Clinical outcome of surgically treated low-grade gliomas: a retrospective analysis of a single institute.

Clin Neurol Neurosurg 2013;115:2508-2513. Available at:

<http://www.ncbi.nlm.nih.gov/pubmed/24225484>.

73. Kilic T, Ozduman K, Elmaci I, et al. Effect of surgery on tumor progression and malignant degeneration in hemispheric diffuse low-grade astrocytomas. J Clin Neurosci 2002;9:549-552. Available at:

<http://www.ncbi.nlm.nih.gov/pubmed/12383413>.

74. McGirt MJ, Chaichana KL, Attenello FJ, et al. Extent of surgical resection is independently associated with survival in patients with hemispheric infiltrating low-grade gliomas. Neurosurgery 2008;63:700-707; author reply 707-708. Available at:

<http://www.ncbi.nlm.nih.gov/pubmed/18981880>.

75. Chaichana KL, McGirt MJ, Lattera J, et al. Recurrence and malignant degeneration after resection of adult hemispheric low-grade gliomas. J Neurosurg 2010;112:10-17. Available at:

<http://www.ncbi.nlm.nih.gov/pubmed/19361270>.

76. Berger MS, Deliganis AV, Dobbins J, Keles GE. The effect of extent of resection on recurrence in patients with low grade cerebral hemisphere gliomas. Cancer 1994;74:1784-1791. Available at:

<http://www.ncbi.nlm.nih.gov/pubmed/8082081>.

77. van den Bent MJ, Afra D, de Witte O, et al. Long-term efficacy of early versus delayed radiotherapy for low-grade astrocytoma and oligodendroglioma in adults: the EORTC 22845 randomised trial. Lancet 2005;366:985-990. Available at:

<http://www.ncbi.nlm.nih.gov/pubmed/16168780>.

78. Gorlia T, Wu W, Wang M, et al. New validated prognostic models and prognostic calculators in patients with low-grade gliomas diagnosed by central pathology review: a pooled analysis of EORTC/RTOG/NCCTG phase III clinical trials. Neuro Oncol 2013;15:1568-1579. Available at:

<http://www.ncbi.nlm.nih.gov/pubmed/24049111>.

79. Shaw EG, Wang M, Coons SW, et al. Randomized trial of radiation therapy plus procarbazine, lomustine, and vincristine chemotherapy for supratentorial adult low-grade glioma: initial results of RTOG 9802. J Clin Oncol 2012;30:3065-3070. Available at:

<http://www.ncbi.nlm.nih.gov/pubmed/22851558>.

80. Buckner JC, Shaw EG, Pugh SL, et al. Radiation plus procarbazine, CCNU, and vincristine in low-grade glioma. N Engl J Med 2016;374:1344-1355. Available at:

<https://www.ncbi.nlm.nih.gov/pubmed/27050206>.

81. Fisher BJ, Hu C, Macdonald DR, et al. Phase 2 study of temozolomide-based chemoradiation therapy for high-risk low-grade gliomas: preliminary results of Radiation Therapy Oncology Group 0424. Int J Radiat Oncol Biol Phys 2015;91:497-504. Available at:

<http://www.ncbi.nlm.nih.gov/pubmed/25680596>.

82. Shaw EG, Daumas-Duport C, Scheithauer BW, et al. Radiation therapy in the management of low-grade supratentorial astrocytomas. J Neurosurg 1989;70:853-861. Available at:

<http://www.ncbi.nlm.nih.gov/pubmed/2715812>.

83. Ceccarelli M, Barthel FP, Malta TM, et al. Molecular profiling reveals biologically discrete subsets and pathways of progression in diffuse glioma. Cell 2016;164:550-563. Available at:

<https://www.ncbi.nlm.nih.gov/pubmed/26824661>.

84. Kesari S, Schiff D, Drappatz J, et al. Phase II study of protracted daily temozolomide for low-grade gliomas in adults. Clin Cancer Res 2009;15:330-337. Available at:

<http://www.ncbi.nlm.nih.gov/pubmed/19118062>.

85. Nicholson HS, Kretschmar CS, Krailo M, et al. Phase 2 study of temozolomide in children and adolescents with recurrent central nervous system tumors: a report from the Children's Oncology Group. Cancer 2007;110:1542-1550. Available at:

<http://www.ncbi.nlm.nih.gov/pubmed/17705175>.

86. Soffietti R, Ruda R, Bradac GB, Schiffer D. PCV chemotherapy for recurrent oligodendrogliomas and oligoastrocytomas. *Neurosurgery* 1998;43:1066-1073. Available at:

<http://www.ncbi.nlm.nih.gov/pubmed/9802850>.

87. Moghrabi A, Friedman HS, Ashley DM, et al. Phase II study of carboplatin (CBDCA) in progressive low-grade gliomas. *Neurosurg Focus* 1998;4:e3. Available at:

<http://www.ncbi.nlm.nih.gov/pubmed/17168503>.

88. Brandes AA, Basso U, Vastola F, et al. Carboplatin and teniposide as third-line chemotherapy in patients with recurrent oligodendroglioma or oligoastrocytoma: a phase II study. *Ann Oncol* 2003;14:1727-1731. Available at:

<http://www.ncbi.nlm.nih.gov/pubmed/14630676>.

89. Jakola AS, Skjulsvik AJ, Myrnes KS, et al. Surgical resection versus watchful waiting in low-grade gliomas. *Ann Oncol* 2017;28:1942-1948. Available at:

<https://www.ncbi.nlm.nih.gov/pubmed/28475680>.

90. van den Bent MJ, Smits M, Kros JM, Chang SM. Diffuse infiltrating oligodendroglioma and astrocytoma. *J Clin Oncol* 2017;35:2394-2401. Available at:

<https://www.ncbi.nlm.nih.gov/pubmed/28640702>.

91. Ostrom QT, Gittleman H, Xu J, et al. CBTRUS Statistical Report: Primary Brain and Other Central Nervous System Tumors Diagnosed in the United States in 2009-2013. *Neuro Oncol* 2016;18:v1-v75. Available at:

<https://www.ncbi.nlm.nih.gov/pubmed/28475809>.

92. Laws ER, Parney IF, Huang W, et al. Survival following surgery and prognostic factors for recently diagnosed malignant glioma: data from the Glioma Outcomes Project. *J Neurosurg* 2003;99:467-473. Available at:

<http://www.ncbi.nlm.nih.gov/pubmed/12959431>.

93. Simpson JR, Horton J, Scott C, et al. Influence of location and extent of surgical resection on survival of patients with glioblastoma multiforme: results of three consecutive Radiation Therapy Oncology Group (RTOG) clinical trials. *Int J Radiat Oncol Biol Phys* 1993;26:239-244. Available at:

<http://www.ncbi.nlm.nih.gov/pubmed/8387988>.

94. Wood JR, Green SB, Shapiro WR. The prognostic importance of tumor size in malignant gliomas: a computed tomographic scan study by the Brain Tumor Cooperative Group. *J Clin Oncol* 1988;6:338-343. Available at:

<http://www.ncbi.nlm.nih.gov/pubmed/3339397>.

95. Lacroix M, Abi-Said D, Fourney DR, et al. A multivariate analysis of 416 patients with glioblastoma multiforme: prognosis, extent of resection, and survival. *J Neurosurg* 2001;95:190-198. Available at:

<http://www.ncbi.nlm.nih.gov/pubmed/11780887>.

96. Barker FG, 2nd, Chang SM, Gutin PH, et al. Survival and functional status after resection of recurrent glioblastoma multiforme. *Neurosurgery* 1998;42:709-720; discussion 720-703. Available at:

<http://www.ncbi.nlm.nih.gov/pubmed/9574634>.

97. Park JK, Hodges T, Arko L, et al. Scale to predict survival after surgery for recurrent glioblastoma multiforme. *J Clin Oncol* 2010;28:3838-3843. Available at:

<http://www.ncbi.nlm.nih.gov/pubmed/20644085>.

98. Kristiansen K, Hagen S, Kollevold T, et al. Combined modality therapy of operated astrocytomas grade III and IV. Confirmation of the value of postoperative irradiation and lack of potentiation of bleomycin on survival time: a prospective multicenter trial of the Scandinavian Glioblastoma Study Group. *Cancer* 1981;47:649-652. Available at:

<http://www.ncbi.nlm.nih.gov/pubmed/6164465>.

99. Walker MD, Alexander E, Jr., Hunt WE, et al. Evaluation of BCNU and/or radiotherapy in the treatment of anaplastic gliomas. A cooperative clinical trial. *J Neurosurg* 1978;49:333-343. Available at:

<http://www.ncbi.nlm.nih.gov/pubmed/355604>.

100. Cabrera AR, Kirkpatrick JP, Fiveash JB, et al. Radiation therapy for glioblastoma: Executive summary of an American Society for Radiation Oncology Evidence-Based Clinical Practice Guideline. *Pract Radiat Oncol* 2016;6:217-225. Available at:

<https://www.ncbi.nlm.nih.gov/pubmed/27211230>.

101. Adeberg S, Harrabi SB, Verma V, et al. Treatment of meningioma and glioma with protons and carbon ions. *Radiat Oncol* 2017;12:193. Available at: <https://www.ncbi.nlm.nih.gov/pubmed/29195506>.
102. Roa W, Brasher PM, Bauman G, et al. Abbreviated course of radiation therapy in older patients with glioblastoma multiforme: a prospective randomized clinical trial. *J Clin Oncol* 2004;22:1583-1588. Available at: <http://www.ncbi.nlm.nih.gov/pubmed/15051755>.
103. Roa W, Kepka L, Kumar N, et al. International Atomic Energy Agency randomized phase III study of radiation therapy in elderly and/or frail patients with newly diagnosed glioblastoma multiforme. *J Clin Oncol* 2015. Available at: <http://www.ncbi.nlm.nih.gov/pubmed/26392096>.
104. Stupp R, Hegi ME, Mason WP, et al. Effects of radiotherapy with concomitant and adjuvant temozolomide versus radiotherapy alone on survival in glioblastoma in a randomised phase III study: 5-year analysis of the EORTC-NCIC trial. *Lancet Oncol* 2009;10:459-466. Available at: <http://www.ncbi.nlm.nih.gov/pubmed/19269895>.
105. van den Bent MJ, Carpentier AF, Brandes AA, et al. Adjuvant procarbazine, lomustine, and vincristine improves progression-free survival but not overall survival in newly diagnosed anaplastic oligodendrogliomas and oligoastrocytomas: a randomized European Organisation for Research and Treatment of Cancer phase III trial. *J Clin Oncol* 2006;24:2715-2722. Available at: <http://www.ncbi.nlm.nih.gov/pubmed/16782911>.
106. van den Bent MJ, Brandes AA, Taphoorn MJ, et al. Adjuvant procarbazine, lomustine, and vincristine chemotherapy in newly diagnosed anaplastic oligodendroglioma: long-term follow-up of EORTC brain tumor group study 26951. *J Clin Oncol* 2013;31:344-350. Available at: <http://www.ncbi.nlm.nih.gov/pubmed/23071237>.
107. Cairncross G, Berkey B, Shaw E, et al. Phase III trial of chemotherapy plus radiotherapy compared with radiotherapy alone for pure and mixed anaplastic oligodendroglioma: Intergroup Radiation Therapy Oncology Group Trial 9402. *J Clin Oncol* 2006;24:2707-2714. Available at: <http://www.ncbi.nlm.nih.gov/pubmed/16782910>.
108. Cairncross G, Wang M, Shaw E, et al. Phase III trial of chemoradiotherapy for anaplastic oligodendroglioma: long-term results of RTOG 9402. *J Clin Oncol* 2013;31:337-343. Available at: <http://www.ncbi.nlm.nih.gov/pubmed/23071247>.
109. Jaeckle K, Vogelbaum M, Ballman K, et al. CODEL (Alliance-N0577; EORTC-26081/22086; NRG-1071; NCIC-CEC-2): phase III randomized study of RT vs. RT+TMZ vs. TMZ for newly diagnosed 1p/19q-codeleted anaplastic oligodendroglial tumors. *Neurology* 2016;86. Available at: http://n.neurology.org/content/86/16_Supplement/PL02.005.short.
110. van den Bent MJ, Baumert B, Erridge SC, et al. Interim results from the CATNON trial (EORTC study 26053-22054) of treatment with concurrent and adjuvant temozolomide for 1p/19q non-co-deleted anaplastic glioma: a phase 3, randomised, open-label intergroup study. *Lancet* 2017;390:1645-1653. Available at: <https://www.ncbi.nlm.nih.gov/pubmed/28801186>.
111. Stupp R, Mason WP, van den Bent MJ, et al. Radiotherapy plus concomitant and adjuvant temozolomide for glioblastoma. *N Engl J Med* 2005;352:987-996. Available at: <http://www.ncbi.nlm.nih.gov/pubmed/15758009>.
112. Clarke JL, Iwamoto FM, Sul J, et al. Randomized phase II trial of chemoradiotherapy followed by either dose-dense or metronomic temozolomide for newly diagnosed glioblastoma. *J Clin Oncol* 2009;27:3861-3867. Available at: <http://www.ncbi.nlm.nih.gov/pubmed/19506159>.
113. Gilbert MR, Wang M, Aldape KD, et al. Dose-dense temozolomide for newly diagnosed glioblastoma: a randomized phase III clinical trial. *J Clin Oncol* 2013;31:4085-4091. Available at: <http://www.ncbi.nlm.nih.gov/pubmed/24101040>.

114. Stupp R, Hegi ME, Gorlia T, et al. Cilengitide combined with standard treatment for patients with newly diagnosed glioblastoma with methylated MGMT promoter (CENTRIC EORTC 26071-22072 study): a multicentre, randomised, open-label, phase 3 trial. *Lancet Oncol* 2014;15:1100-1108. Available at:

<http://www.ncbi.nlm.nih.gov/pubmed/25163906>.

115. Nabors LB, Fink KL, Mikkelsen T, et al. Two cilengitide regimens in combination with standard treatment for patients with newly diagnosed glioblastoma and unmethylated MGMT gene promoter: results of the open-label, controlled, randomized phase II CORE study. *Neuro Oncol* 2015;17:708-717. Available at:

<http://www.ncbi.nlm.nih.gov/pubmed/25762461>.

116. Blumenthal DT, Gorlia T, Gilbert MR, et al. Is more better? The impact of extended adjuvant temozolomide in newly diagnosed glioblastoma: a secondary analysis of EORTC and NRG

Oncology/RTOG. *Neuro Oncol* 2017;19:1119-1126. Available at:

<https://www.ncbi.nlm.nih.gov/pubmed/28371907>.

117. Perry JR, Laperriere N, O'Callaghan CJ, et al. Short-course radiation plus temozolomide in elderly patients with glioblastoma. *N Engl J Med* 2017;376:1027-1037. Available at:

<https://www.ncbi.nlm.nih.gov/pubmed/28296618>.

118. Stupp R, Taillibert S, Kanner AA, et al. Maintenance therapy with tumor-treating fields plus temozolomide vs temozolomide alone for glioblastoma: a randomized clinical trial. *JAMA* 2015;314:2535-2543. Available at:

<http://www.ncbi.nlm.nih.gov/pubmed/26670971>.

119. Stupp R, Taillibert S, Kanner A, et al. Effect of tumor-treating fields plus maintenance temozolomide vs maintenance temozolomide alone on survival in patients with glioblastoma: a randomized clinical trial. *JAMA* 2017;318:2306-2316. Available at:

<https://www.ncbi.nlm.nih.gov/pubmed/29260225>.

120. Taphoorn MJB, Dirven L, Kanner AA, et al. Influence of treatment with tumor-treating fields on health-related quality of life of patients with

newly diagnosed glioblastoma: a secondary analysis of a randomized clinical trial. *JAMA Oncol* 2018;4:495-504. Available at:

<https://www.ncbi.nlm.nih.gov/pubmed/29392280>.

121. Chamberlain MC. Treatment for patients with newly diagnosed glioblastoma. *Jama* 2016;315:2348. Available at:

<https://www.ncbi.nlm.nih.gov/pubmed/27272590>.

122. Sampson JH. Alternating electric fields for the treatment of glioblastoma. *Jama* 2015;314:2511-2513. Available at:

<https://www.ncbi.nlm.nih.gov/pubmed/26670969>.

123. Perry JR, Rizek P, Cashman R, et al. Temozolomide rechallenge in recurrent malignant glioma by using a continuous temozolomide schedule: the "rescue" approach. *Cancer* 2008;113:2152-2157. Available at:

<http://www.ncbi.nlm.nih.gov/pubmed/18756530>.

124. Brandes AA, Tosoni A, Amista P, et al. How effective is BCNU in recurrent glioblastoma in the modern era? A phase II trial. *Neurology* 2004;63:1281-1284. Available at:

<https://www.ncbi.nlm.nih.gov/pubmed/15477552>.

125. Reithmeier T, Graf E, Piroth T, et al. BCNU for recurrent glioblastoma multiforme: efficacy, toxicity and prognostic factors. *BMC Cancer* 2010;10:30. Available at:

<https://www.ncbi.nlm.nih.gov/pubmed/20122270>.

126. Wick W, Puduvalli VK, Chamberlain MC, et al. Phase III study of enzastaurin compared with lomustine in the treatment of recurrent intracranial glioblastoma. *J Clin Oncol* 2010;28:1168-1174. Available at:

<http://www.ncbi.nlm.nih.gov/pubmed/20124186>.

127. Taal W, Oosterkamp HM, Walenkamp AM, et al. Single-agent bevacizumab or lomustine versus a combination of bevacizumab plus lomustine in patients with recurrent glioblastoma (BELOB trial): a randomised controlled phase 2 trial. *Lancet Oncol* 2014;15:943-953. Available at:

<https://www.ncbi.nlm.nih.gov/pubmed/25035291>.

128. Friedman HS, Prados MD, Wen PY, et al. Bevacizumab alone and in combination with irinotecan in recurrent glioblastoma. *J Clin Oncol* 2009;27:4733-4740. Available at: <http://www.ncbi.nlm.nih.gov/pubmed/19720927>.
129. Wick W, Gorlia T, Bendszus M, et al. Lomustine and bevacizumab in progressive glioblastoma. *N Engl J Med* 2017;377:1954-1963. Available at: <https://www.ncbi.nlm.nih.gov/pubmed/29141164>.
130. Wick W, Weller M, van den Bent M, Stupp R. Bevacizumab and recurrent malignant gliomas: a European perspective. *J Clin Oncol* 2010;28:e188-189; author reply e190-182. Available at: <https://www.ncbi.nlm.nih.gov/pubmed/20159801>.
131. Brem H, Piantadosi S, Burger PC, et al. Placebo-controlled trial of safety and efficacy of intraoperative controlled delivery by biodegradable polymers of chemotherapy for recurrent gliomas. The Polymer-brain Tumor Treatment Group. *Lancet* 1995;345:1008-1012. Available at: <http://www.ncbi.nlm.nih.gov/pubmed/7723496>.
132. Stupp R, Wong ET, Kanner AA, et al. NovoTTF-100A versus physician's choice chemotherapy in recurrent glioblastoma: a randomised phase III trial of a novel treatment modality. *Eur J Cancer* 2012;48:2192-2202. Available at: <http://www.ncbi.nlm.nih.gov/pubmed/22608262>.
133. Minniti G, Scaringi C, Lanzetta G, et al. Standard (60 Gy) or short-course (40 Gy) irradiation plus concomitant and adjuvant temozolomide for elderly patients with glioblastoma: a propensity-matched analysis. *Int J Radiat Oncol Biol Phys* 2015;91:109-115. Available at: <http://www.ncbi.nlm.nih.gov/pubmed/25442339>.
134. Hegi ME, Stupp R. Withholding temozolomide in glioblastoma patients with unmethylated MGMT promoter--still a dilemma? *Neuro Oncol* 2015;17:1425-1427. Available at: <https://www.ncbi.nlm.nih.gov/pubmed/26374690>.
135. Tsien C, Galban CJ, Chenevert TL, et al. Parametric response map as an imaging biomarker to distinguish progression from pseudoprogression in high-grade glioma. *J Clin Oncol* 2010;28:2293-2299. Available at: <http://www.ncbi.nlm.nih.gov/pubmed/20368564>.
136. Fink J, Born D, Chamberlain MC. Pseudoprogression: relevance with respect to treatment of high-grade gliomas. *Curr Treat Options Oncol* 2011;12:240-252. Available at: <http://www.ncbi.nlm.nih.gov/pubmed/21594589>.
137. Chamberlain MC. Ependymomas. *Curr Neurol Neurosci Rep* 2003;3:193-199. Available at: <http://www.ncbi.nlm.nih.gov/pubmed/12691623>.
138. DeVita VT, Lawrence TS, Rosenberg SA. DeVita, Hellman, and Rosenberg's Cancer: Principles and Practice of Oncology (ed 8). Philadelphia: Lippincott Williams & Wilkins; 2008.
139. Packer RJ, Hoffman HJ, Friedman HS. Tumors of the fourth ventricle. In: Levin VA, ed. *Cancer in the Nervous System*. New York: Churchill Livingstone; 1996:153-156.
140. Kawabata Y, Takahashi JA, Arakawa Y, Hashimoto N. Long-term outcome in patients harboring intracranial ependymoma. *J Neurosurg* 2005;103:31-37. Available at: <http://www.ncbi.nlm.nih.gov/pubmed/16121970>.
141. Metellus P, Figarella-Branger D, Guyotat J, et al. Supratentorial ependymomas: prognostic factors and outcome analysis in a retrospective series of 46 adult patients. *Cancer* 2008;113:175-185. Available at: <http://www.ncbi.nlm.nih.gov/pubmed/18470910>.
142. Metellus P, Barrie M, Figarella-Branger D, et al. Multicentric French study on adult intracranial ependymomas: prognostic factors analysis and therapeutic considerations from a cohort of 152 patients. *Brain* 2007;130:1338-1349. Available at: <http://www.ncbi.nlm.nih.gov/pubmed/17449478>.

143. Paulino AC, Wen BC, Buatti JM, et al. Intracranial ependymomas: an analysis of prognostic factors and patterns of failure. *Am J Clin Oncol* 2002;25:117-122. Available at: <http://www.ncbi.nlm.nih.gov/pubmed/11943886>.
144. Schwartz TH, Kim S, Glick RS, et al. Supratentorial ependymomas in adult patients. *Neurosurgery* 1999;44:721-731. Available at: <http://www.ncbi.nlm.nih.gov/pubmed/10201296>.
145. Rodriguez D, Cheung MC, Housri N, et al. Outcomes of malignant CNS ependymomas: an examination of 2408 cases through the Surveillance, Epidemiology, and End Results (SEER) database (1973-2005). *J Surg Res* 2009;156:340-351. Available at: <http://www.ncbi.nlm.nih.gov/pubmed/19577759>.
146. Mansur DB, Perry A, Rajaram V, et al. Postoperative radiation therapy for grade II and III intracranial ependymoma. *Int J Radiat Oncol Biol Phys* 2005;61:387-391. Available at: <http://www.ncbi.nlm.nih.gov/pubmed/15667957>.
147. Merchant TE, Fouladi M. Ependymoma: new therapeutic approaches including radiation and chemotherapy. *J Neurooncol* 2005;75:287-299. Available at: <http://www.ncbi.nlm.nih.gov/pubmed/16195801>.
148. Taylor RE. Review of radiotherapy dose and volume for intracranial ependymoma. *Pediatr Blood Cancer* 2004;42:457-460. Available at: <http://www.ncbi.nlm.nih.gov/pubmed/15049020>.
149. Reni M, Brandes AA, Vavassori V, et al. A multicenter study of the prognosis and treatment of adult brain ependymal tumors. *Cancer* 2004;100:1221-1229. Available at: <http://www.ncbi.nlm.nih.gov/pubmed/15022290>.
150. Goldwein JW, Corn BW, Finlay JL, et al. Is craniospinal irradiation required to cure children with malignant (anaplastic) intracranial ependymomas? *Cancer* 1991;67:2766-2771. Available at: <http://www.ncbi.nlm.nih.gov/pubmed/2025840>.
151. Vanuytsel L, Brada M. The role of prophylactic spinal irradiation in localized intracranial ependymoma. *Int J Radiat Oncol Biol Phys* 1991;21:825-830. Available at: <http://www.ncbi.nlm.nih.gov/pubmed/1831193>.
152. Vanuytsel LJ, Bessell EM, Ashley SE, et al. Intracranial ependymoma: long-term results of a policy of surgery and radiotherapy. *Int J Radiat Oncol Biol Phys* 1992;23:313-319. Available at: <http://www.ncbi.nlm.nih.gov/pubmed/1587752>.
153. Merchant TE, Li C, Xiong X, et al. Conformal radiotherapy after surgery for paediatric ependymoma: a prospective study. *Lancet Oncol* 2009;10:258-266. Available at: <http://www.ncbi.nlm.nih.gov/pubmed/19274783>.
154. Kano H, Niranjan A, Kondziolka D, et al. Outcome predictors for intracranial ependymoma radiosurgery. *Neurosurgery* 2009;64:279-287; discussion 287-278. Available at: <http://www.ncbi.nlm.nih.gov/pubmed/19190457>.
155. Lo SS, Abdulrahman R, Desrosiers PM, et al. The role of Gamma Knife Radiosurgery in the management of unresectable gross disease or gross residual disease after surgery in ependymoma. *J Neurooncol* 2006;79:51-56. Available at: <http://www.ncbi.nlm.nih.gov/pubmed/16557349>.
156. Mansur DB, Drzymala RE, Rich KM, et al. The efficacy of stereotactic radiosurgery in the management of intracranial ependymoma. *J Neurooncol* 2004;66:187-190. Available at: <http://www.ncbi.nlm.nih.gov/pubmed/15015785>.
157. Brandes AA, Cavallo G, Reni M, et al. A multicenter retrospective study of chemotherapy for recurrent intracranial ependymal tumors in adults by the Gruppo Italiano Cooperativo di Neuro-Oncologia. *Cancer* 2005;104:143-148. Available at: <http://www.ncbi.nlm.nih.gov/pubmed/15912507>.

158. Gornet MK, Buckner JC, Marks RS, et al. Chemotherapy for advanced CNS ependymoma. *J Neurooncol* 1999;45:61-67. Available at: <http://www.ncbi.nlm.nih.gov/pubmed/10728911>.

159. Chamberlain MC. Recurrent intracranial ependymoma in children: salvage therapy with oral etoposide. *Pediatr Neurol* 2001;24:117-121. Available at: <http://www.ncbi.nlm.nih.gov/pubmed/11275460>.

160. Green RM, Cloughesy TF, Stupp R, et al. Bevacizumab for recurrent ependymoma. *Neurology* 2009;73:1677-1680. Available at: <http://www.ncbi.nlm.nih.gov/pubmed/19917990>.

161. Louis DN, Ohgaki H, Wiestler OD, et al. The 2007 WHO classification of tumours of the central nervous system. *Acta Neuropathol* 2007;114:97-109. Available at: <http://www.ncbi.nlm.nih.gov/pubmed/17618441>.

162. Surawicz TS, McCarthy BJ, Kupelian V, et al. Descriptive epidemiology of primary brain and CNS tumors: results from the Central Brain Tumor Registry of the United States, 1990-1994. *Neuro Oncol* 1999;1:14-25. Available at: <http://www.ncbi.nlm.nih.gov/pubmed/11554386>.

163. Kunschner LJ, Kuttesch J, Hess K, Yung WK. Survival and recurrence factors in adult medulloblastoma: the M.D. Anderson Cancer Center experience from 1978 to 1998. *Neuro Oncol* 2001;3:167-173. Available at: <http://www.ncbi.nlm.nih.gov/pubmed/11465397>.

164. Padovani L, Sunyach MP, Perol D, et al. Common strategy for adult and pediatric medulloblastoma: a multicenter series of 253 adults. *Int J Radiat Oncol Biol Phys* 2007;68:433-440. Available at: <http://www.ncbi.nlm.nih.gov/pubmed/17498567>.

165. Carrie C, Lasset C, Alapetite C, et al. Multivariate analysis of prognostic factors in adult patients with medulloblastoma. Retrospective study of 156 patients. *Cancer* 1994;74:2352-2360. Available at: <http://www.ncbi.nlm.nih.gov/pubmed/7922986>.

166. Chan AW, Tarbell NJ, Black PM, et al. Adult medulloblastoma: prognostic factors and patterns of relapse. *Neurosurgery* 2000;47:623-631; discussion 631-622. Available at: <http://www.ncbi.nlm.nih.gov/pubmed/10981749>.

167. Frost PJ, Laperriere NJ, Wong CS, et al. Medulloblastoma in adults. *Int J Radiat Oncol Biol Phys* 1995;32:951-957. Available at: <http://www.ncbi.nlm.nih.gov/pubmed/7607969>.

168. Chargari C, Feuvret L, Levy A, et al. Reappraisal of clinical outcome in adult medulloblastomas with emphasis on patterns of relapse. *Br J Neurosurg* 2010;24:460-467. Available at: <http://www.ncbi.nlm.nih.gov/pubmed/20726753>.

169. Douglas JG, Barker JL, Ellenbogen RG, Geyer JR. Concurrent chemotherapy and reduced-dose cranial spinal irradiation followed by conformal posterior fossa tumor bed boost for average-risk medulloblastoma: efficacy and patterns of failure. *Int J Radiat Oncol Biol Phys* 2004;58:1161-1164. Available at: <http://www.ncbi.nlm.nih.gov/pubmed/15001259>.

170. Merchant TE, Kun LE, Krasin MJ, et al. Multi-institution prospective trial of reduced-dose craniospinal irradiation (23.4 Gy) followed by conformal posterior fossa (36 Gy) and primary site irradiation (55.8 Gy) and dose-intensive chemotherapy for average-risk medulloblastoma. *Int J Radiat Oncol Biol Phys* 2008;70:782-787. Available at: <http://www.ncbi.nlm.nih.gov/pubmed/17892918>.

171. Deutsch M, Thomas PR, Krischer J, et al. Results of a prospective randomized trial comparing standard dose neuraxis irradiation (3,600 cGy/20) with reduced neuraxis irradiation (2,340 cGy/13) in patients with low-stage medulloblastoma. A Combined Children's Cancer Group-Pediatric Oncology Group Study. *Pediatr Neurosurg* 1996;24:167-176; discussion 176-167. Available at: <http://www.ncbi.nlm.nih.gov/pubmed/8873158>.

172. Brown AP, Barney CL, Grosshans DR, et al. Proton beam craniospinal irradiation reduces acute toxicity for adults with

medulloblastoma. *Int J Radiat Oncol Biol Phys* 2013;86:277-284.

Available at: <http://www.ncbi.nlm.nih.gov/pubmed/23433794>.

173. Germanwala AV, Mai JC, Tomycz ND, et al. Boost Gamma Knife surgery during multimodality management of adult medulloblastoma. *J Neurosurg* 2008;108:204-209. Available at:

<http://www.ncbi.nlm.nih.gov/pubmed/18240913>.

174. Riffaud L, Saikali S, Leray E, et al. Survival and prognostic factors in a series of adults with medulloblastomas. *J Neurosurg* 2009;111:478-487. Available at: <http://www.ncbi.nlm.nih.gov/pubmed/19231932>.

175. Herrlinger U, Steinbrecher A, Rieger J, et al. Adult medulloblastoma: prognostic factors and response to therapy at diagnosis and at relapse. *J Neurol* 2005;252:291-299. Available at:

<http://www.ncbi.nlm.nih.gov/pubmed/16189725>.

176. Packer RJ, Gajjar A, Vezina G, et al. Phase III study of craniospinal radiation therapy followed by adjuvant chemotherapy for newly diagnosed average-risk medulloblastoma. *J Clin Oncol* 2006;24:4202-4208. Available at:

<https://www.ncbi.nlm.nih.gov/pubmed/16943538>.

177. Ashley DM, Meier L, Kerby T, et al. Response of recurrent medulloblastoma to low-dose oral etoposide. *J Clin Oncol* 1996;14:1922-1927. Available at:

<http://www.ncbi.nlm.nih.gov/pubmed/8656261>.

178. Chamberlain MC, Kormanik PA. Chronic oral VP-16 for recurrent medulloblastoma. *Pediatr Neurol* 1997;17:230-234. Available at:

<https://www.ncbi.nlm.nih.gov/pubmed/9390699>.

179. Dunkel IJ, Gardner SL, Garvin JH, Jr., et al. High-dose carboplatin, thiotepa, and etoposide with autologous stem cell rescue for patients with previously irradiated recurrent medulloblastoma. *Neuro Oncol* 2010;12:297-303. Available at:

<http://www.ncbi.nlm.nih.gov/pubmed/20167818>.

180. Gill P, Litzow M, Buckner J, et al. High-dose chemotherapy with autologous stem cell transplantation in adults with recurrent embryonal tumors of the central nervous system. *Cancer* 2008;112:1805-1811. Available at: <http://www.ncbi.nlm.nih.gov/pubmed/18300237>.

181. Cohen ME, Duffner P, eds. *Brain tumors in children* (ed 2). New York: McGraw-Hill; 1994.

182. Chang CH, Housepian EM, Herbert C, Jr. An operative staging system and a megavoltage radiotherapeutic technic for cerebellar medulloblastomas. *Radiology* 1969;93:1351-1359. Available at:

<http://www.ncbi.nlm.nih.gov/pubmed/4983156>.

183. Brandes AA, Franceschi E, Tosoni A, et al. Adult neuroectodermal tumors of posterior fossa (medulloblastoma) and of supratentorial sites (stPNET). *Crit Rev Oncol Hematol* 2009;71:165-179. Available at:

<http://www.ncbi.nlm.nih.gov/pubmed/19303318>.

184. Olson JE, Janney CA, Rao RD, et al. The continuing increase in the incidence of primary central nervous system non-Hodgkin lymphoma: a surveillance, epidemiology, and end results analysis. *Cancer* 2002;95:1504-1510. Available at:

<http://www.ncbi.nlm.nih.gov/pubmed/12237919>.

185. Fine HA, Mayer RJ. Primary central nervous system lymphoma. *Ann Intern Med* 1993;119:1093-1104. Available at:

<http://www.ncbi.nlm.nih.gov/pubmed/8239229>.

186. Norden AD, Drappatz J, Wen PY, Claus EB. Survival among patients with primary central nervous system lymphoma, 1973-2004. *J Neurooncol* 2010. Available at:

<http://www.ncbi.nlm.nih.gov/pubmed/20556477>.

187. Gerstner ER, Batchelor TT. Primary central nervous system lymphoma. *Arch Neurol* 2010;67:291-297. Available at:

<http://www.ncbi.nlm.nih.gov/pubmed/20212226>.

188. Bataille B, Delwail V, Menet E, et al. Primary intracerebral malignant lymphoma: report of 248 cases. *J Neurosurg* 2000;92:261-266. Available at: <http://www.ncbi.nlm.nih.gov/pubmed/10659013>.
189. Abrey LE, Batchelor TT, Ferreri AJM, et al. Report of an international workshop to standardize baseline evaluation and response criteria for primary CNS lymphoma. *J Clin Oncol* 2005;23:5034-5043. Available at: <http://www.ncbi.nlm.nih.gov/pubmed/15955902>.
190. Batchelor T, Carson K, O'Neill A, et al. Treatment of primary CNS lymphoma with methotrexate and deferred radiotherapy: a report of NABTT 96-07. *J Clin Oncol* 2003;21:1044-1049. Available at: <http://www.ncbi.nlm.nih.gov/pubmed/12637469>.
191. Chamberlain MC, Johnston SK. High-dose methotrexate and rituximab with deferred radiotherapy for newly diagnosed primary B-cell CNS lymphoma. *Neuro Oncol* 2010;12:736-744. Available at: <http://www.ncbi.nlm.nih.gov/pubmed/20511181>.
192. DeAngelis LM, Seiferheld W, Schold SC, et al. Combination chemotherapy and radiotherapy for primary central nervous system lymphoma: Radiation Therapy Oncology Group Study 93-10. *J Clin Oncol* 2002;20:4643-4648. Available at: <http://www.ncbi.nlm.nih.gov/pubmed/12488408>.
193. Ferreri AJ, Reni M, Foppoli M, et al. High-dose cytarabine plus high-dose methotrexate versus high-dose methotrexate alone in patients with primary CNS lymphoma: a randomised phase 2 trial. *Lancet* 2009;374:1512-1520. Available at: <http://www.ncbi.nlm.nih.gov/pubmed/19767089>.
194. Gavrilovic IT, Hormigo A, Yahalom J, et al. Long-term follow-up of high-dose methotrexate-based therapy with and without whole brain irradiation for newly diagnosed primary CNS lymphoma. *J Clin Oncol* 2006;24:4570-4574. Available at: <http://www.ncbi.nlm.nih.gov/pubmed/17008697>.
195. Shah GD, Yahalom J, Correa DD, et al. Combined immunochemotherapy with reduced whole-brain radiotherapy for newly diagnosed primary CNS lymphoma. *J Clin Oncol* 2007;25:4730-4735. Available at: <http://www.ncbi.nlm.nih.gov/pubmed/17947720>.
196. Thiel E, Korfel A, Martus P, et al. High-dose methotrexate with or without whole brain radiotherapy for primary CNS lymphoma (G-PCNSL-SG-1): a phase 3, randomised, non-inferiority trial. *Lancet Oncol* 2010;11:1036-1047. Available at: <http://www.ncbi.nlm.nih.gov/pubmed/20970380>.
197. Wieduwilt MJ, Valles F, Issa S, et al. Immunochemotherapy with intensive consolidation for primary CNS lymphoma: a pilot study and prognostic assessment by diffusion-weighted MRI. *Clin Cancer Res* 2012;18:1146-1155. Available at: <https://www.ncbi.nlm.nih.gov/pubmed/22228634>.
198. Gregory G, Arumugaswamy A, Leung T, et al. Rituximab is associated with improved survival for aggressive B cell CNS lymphoma. *Neuro Oncol* 2013;15:1068-1073. Available at: <http://www.ncbi.nlm.nih.gov/pubmed/23502429>.
199. Khan RB, Shi W, Thaler HT, et al. Is intrathecal methotrexate necessary in the treatment of primary CNS lymphoma? *J Neurooncol* 2002;58:175-178. Available at: <http://www.ncbi.nlm.nih.gov/pubmed/12164690>.
200. Widemann BC, Balis FM, Kim A, et al. Glucarpidase, leucovorin, and thymidine for high-dose methotrexate-induced renal dysfunction: clinical and pharmacologic factors affecting outcome. *J Clin Oncol* 2010;28:3979-3986. Available at: <http://www.ncbi.nlm.nih.gov/pubmed/20679598>.
201. Widemann BC, Balis FM, Kempf-Bielack B, et al. High-dose methotrexate-induced nephrotoxicity in patients with osteosarcoma. *Cancer* 2004;100:2222-2232. Available at: <http://www.ncbi.nlm.nih.gov/pubmed/15139068>.

202. Abrey LE, Yahalom J, DeAngelis LM. Treatment for primary CNS lymphoma: the next step. *J Clin Oncol* 2000;18:3144-3150. Available at: <http://www.ncbi.nlm.nih.gov/pubmed/10963643>.

203. Bessell EM, Lopez-Guillermo A, Villa S, et al. Importance of radiotherapy in the outcome of patients with primary CNS lymphoma: an analysis of the CHOD/BVAM regimen followed by two different radiotherapy treatments. *J Clin Oncol* 2002;20:231-236. Available at: <http://www.ncbi.nlm.nih.gov/pubmed/11773174>.

204. Gerstner ER, Carson KA, Grossman SA, Batchelor TT. Long-term outcome in PCNSL patients treated with high-dose methotrexate and deferred radiation. *Neurology* 2008;70:401-402. Available at: <http://www.ncbi.nlm.nih.gov/pubmed/18227422>.

205. Hoang-Xuan K, Taillandier L, Chinot O, et al. Chemotherapy alone as initial treatment for primary CNS lymphoma in patients older than 60 years: a multicenter phase II study (26952) of the European Organization for Research and Treatment of Cancer Brain Tumor Group. *J Clin Oncol* 2003;21:2726-2731. Available at: <http://www.ncbi.nlm.nih.gov/pubmed/12860951>.

206. Pels H, Schmidt-Wolf IG, Glasmacher A, et al. Primary central nervous system lymphoma: results of a pilot and phase II study of systemic and intraventricular chemotherapy with deferred radiotherapy. *J Clin Oncol* 2003;21:4489-4495. Available at: <http://www.ncbi.nlm.nih.gov/pubmed/14597744>.

207. Illerhaus G, Marks R, Muller F, et al. High-dose methotrexate combined with procarbazine and CCNU for primary CNS lymphoma in the elderly: results of a prospective pilot and phase II study. *Ann Oncol* 2009;20:319-325. Available at: <http://www.ncbi.nlm.nih.gov/pubmed/18953065>.

208. Juergens A, Pels H, Rogowski S, et al. Long-term survival with favorable cognitive outcome after chemotherapy in primary central nervous system lymphoma. *Ann Neurol* 2010;67:182-189. Available at: <http://www.ncbi.nlm.nih.gov/pubmed/20225195>.

209. Plotkin SR, Betensky RA, Hochberg FH, et al. Treatment of relapsed central nervous system lymphoma with high-dose methotrexate. *Clin Cancer Res* 2004;10:5643-5646. Available at: <http://www.ncbi.nlm.nih.gov/pubmed/15355887>.

210. Reni M, Mason W, Zaja F, et al. Salvage chemotherapy with temozolomide in primary CNS lymphomas: preliminary results of a phase II trial. *Eur J Cancer* 2004;40:1682-1688. Available at: <http://www.ncbi.nlm.nih.gov/pubmed/15251157>.

211. Reni M, Zaja F, Mason W, et al. Temozolomide as salvage treatment in primary brain lymphomas. *Br J Cancer* 2007;96:864-867. Available at: <http://www.ncbi.nlm.nih.gov/pubmed/17325700>.

212. Schulz H, Pels H, Schmidt-Wolf I, et al. Intraventricular treatment of relapsed central nervous system lymphoma with the anti-CD20 antibody rituximab. *Haematologica* 2004;89:753-754. Available at: <http://www.ncbi.nlm.nih.gov/pubmed/15194546>.

213. Enting RH, Demopoulos A, DeAngelis LM, Abrey LE. Salvage therapy for primary CNS lymphoma with a combination of rituximab and temozolomide. *Neurology* 2004;63:901-903. Available at: <http://www.ncbi.nlm.nih.gov/pubmed/15365145>.

214. Voloschin AD, Betensky R, Wen PY, et al. Topotecan as salvage therapy for relapsed or refractory primary central nervous system lymphoma. *J Neurooncol* 2008;86:211-215. Available at: <http://www.ncbi.nlm.nih.gov/pubmed/17896078>.

215. DeAngelis LM, Kreis W, Chan K, et al. Pharmacokinetics of ara-C and ara-U in plasma and CSF after high-dose administration of cytosine arabinoside. *Cancer Chemother Pharmacol* 1992;29:173-177. Available at: <http://www.ncbi.nlm.nih.gov/pubmed/1733548>.

216. McLaughlin P, Velasquez WS, Redman JR, et al. Chemotherapy with dexamethasone, high-dose cytarabine, and cisplatin for parenchymal brain lymphoma. *J Natl Cancer Inst* 1988;80:1408-1412. Available at: <http://www.ncbi.nlm.nih.gov/pubmed/3172268>.

217. Raizer JJ, Rademaker A, Evens AM, et al. Pemetrexed in the treatment of relapsed/refractory primary central nervous system lymphoma. *Cancer* 2012;118:3743-3748. Available at: <http://www.ncbi.nlm.nih.gov/pubmed/22179954>.

218. Colombat P, Lemevel A, Bertrand P, et al. High-dose chemotherapy with autologous stem cell transplantation as first-line therapy for primary CNS lymphoma in patients younger than 60 years: a multicenter phase II study of the GOELAMS group. *Bone Marrow Transplant* 2006;38:417-420. Available at: <http://www.ncbi.nlm.nih.gov/pubmed/16951691>.

219. Montemurro M, Kiefer T, Schuler F, et al. Primary central nervous system lymphoma treated with high-dose methotrexate, high-dose busulfan/thiotepa, autologous stem-cell transplantation and response-adapted whole-brain radiotherapy: results of the multicenter Ostdeutsche Studiengruppe Hamato-Onkologie OSHO-53 phase II study. *Ann Oncol* 2007;18:665-671. Available at: <http://www.ncbi.nlm.nih.gov/pubmed/17185743>.

220. Soussain C, Suzan F, Hoang-Xuan K, et al. Results of intensive chemotherapy followed by hematopoietic stem-cell rescue in 22 patients with refractory or recurrent primary CNS lymphoma or intraocular lymphoma. *J Clin Oncol* 2001;19:742-749. Available at: <http://www.ncbi.nlm.nih.gov/pubmed/11157026>.

221. Angelov L, Doolittle ND, Kraemer DF, et al. Blood-brain barrier disruption and intra-arterial methotrexate-based therapy for newly diagnosed primary CNS lymphoma: a multi-institutional experience. *J Clin Oncol* 2009;27:3503-3509. Available at: <http://www.ncbi.nlm.nih.gov/pubmed/19451444>.

222. Neuwelt EA, Goldman DL, Dahlborg SA, et al. Primary CNS lymphoma treated with osmotic blood-brain barrier disruption: prolonged survival and preservation of cognitive function. *J Clin Oncol* 1991;9:1580-1590. Available at: <http://www.ncbi.nlm.nih.gov/pubmed/1875220>.

223. DeAngelis LM, Yahalom J, Thaler HT, Kher U. Combined modality therapy for primary CNS lymphoma. *J Clin Oncol* 1992;10:635-643. Available at: <http://www.ncbi.nlm.nih.gov/pubmed/1548527>.

224. Fisher B, Seiferheld W, Schultz C, et al. Secondary analysis of Radiation Therapy Oncology Group study (RTOG) 9310: an intergroup phase II combined modality treatment of primary central nervous system lymphoma. *J Neurooncol* 2005;74:201-205. Available at: <http://www.ncbi.nlm.nih.gov/pubmed/16193393>.

225. Nelson DF, Martz KL, Bonner H, et al. Non-Hodgkin's lymphoma of the brain: can high dose, large volume radiation therapy improve survival? Report on a prospective trial by the Radiation Therapy Oncology Group (RTOG): RTOG 8315. *Int J Radiat Oncol Biol Phys* 1992;23:9-17. Available at: <http://www.ncbi.nlm.nih.gov/pubmed/1572835>.

226. Schultz C, Scott C, Sherman W, et al. Preirradiation chemotherapy with cyclophosphamide, doxorubicin, vincristine, and dexamethasone for primary CNS lymphomas: initial report of radiation therapy oncology group protocol 88-06. *J Clin Oncol* 1996;14:556-564. Available at: <http://www.ncbi.nlm.nih.gov/pubmed/8636771>.

227. Poortmans PM, Kluin-Nelemans HC, Haaxma-Reiche H, et al. High-dose methotrexate-based chemotherapy followed by consolidating radiotherapy in non-AIDS-related primary central nervous system lymphoma: European Organization for Research and Treatment of Cancer Lymphoma Group Phase II Trial 20962. *J Clin Oncol* 2003;21:4483-4488. Available at: <http://www.ncbi.nlm.nih.gov/pubmed/14597741>.

228. Ghesquieres H, Ferlay C, Sebban C, et al. Long-term follow-up of an age-adapted C5R protocol followed by radiotherapy in 99 newly diagnosed primary CNS lymphomas: a prospective multicentric phase II study of the Groupe d'Etude des Lymphomes de l'Adulte (GELA). *Ann Oncol* 2010;21:842-850. Available at: <http://www.ncbi.nlm.nih.gov/pubmed/19914958>.

229. Nguyen PL, Chakravarti A, Finkelstein DM, et al. Results of whole-brain radiation as salvage of methotrexate failure for immunocompetent patients with primary CNS lymphoma. *J Clin Oncol* 2005;23:1507-1513. Available at: <http://www.ncbi.nlm.nih.gov/pubmed/15735126>.
230. Coulon A, Lafitte F, Hoang-Xuan K, et al. Radiographic findings in 37 cases of primary CNS lymphoma in immunocompetent patients. *Eur Radiol* 2002;12:329-340. Available at: <http://www.ncbi.nlm.nih.gov/pubmed/11870430>.
231. Mohile NA, Deangelis LM, Abrey LE. The utility of body FDG PET in staging primary central nervous system lymphoma. *Neuro Oncol* 2008;10:223-228. Available at: <http://www.ncbi.nlm.nih.gov/pubmed/18287338>.
232. Schellinger KA, Propp JM, Villano JL, McCarthy BJ. Descriptive epidemiology of primary spinal cord tumors. *J Neurooncol* 2008;87:173-179. Available at: <http://www.ncbi.nlm.nih.gov/pubmed/18084720>.
233. Grimm S, Chamberlain MC. Adult primary spinal cord tumors. *Expert Rev Neurother* 2009;9:1487-1495. Available at: <http://www.ncbi.nlm.nih.gov/pubmed/19831838>.
234. Gezen F, Kahraman S, Canakci Z, Beduk A. Review of 36 cases of spinal cord meningioma. *Spine (Phila Pa 1976)* 2000;25:727-731. Available at: <http://www.ncbi.nlm.nih.gov/pubmed/10752106>.
235. Solero CL, Fornari M, Giombini S, et al. Spinal meningiomas: review of 174 operated cases. *Neurosurgery* 1989;25:153-160. Available at: <http://www.ncbi.nlm.nih.gov/pubmed/2671779>.
236. Volpp PB, Han K, Kagan AR, Tome M. Outcomes in treatment for intradural spinal cord ependymomas. *Int J Radiat Oncol Biol Phys* 2007;69:1199-1204. Available at: <http://www.ncbi.nlm.nih.gov/pubmed/17689025>.
237. Yang S, Yang X, Hong G. Surgical treatment of one hundred seventy-four intramedullary spinal cord tumors. *Spine (Phila Pa 1976)* 2009;34:2705-2710. Available at: <http://www.ncbi.nlm.nih.gov/pubmed/19910775>.
238. Raco A, Esposito V, Lenzi J, et al. Long-term follow-up of intramedullary spinal cord tumors: a series of 202 cases. *Neurosurgery* 2005;56:972-981; discussion 972-981. Available at: <http://www.ncbi.nlm.nih.gov/pubmed/15854245>.
239. Benes V, 3rd, Barsa P, Benes V, Jr., Suchomel P. Prognostic factors in intramedullary astrocytomas: a literature review. *Eur Spine J* 2009;18:1397-1422. Available at: <http://www.ncbi.nlm.nih.gov/pubmed/19562388>.
240. Milano MT, Johnson MD, Sul J, et al. Primary spinal cord glioma: a Surveillance, Epidemiology, and End Results database study. *J Neurooncol* 2010;98:83-92. Available at: <http://www.ncbi.nlm.nih.gov/pubmed/19898743>.
241. Sgouros S, Malluci CL, Jackowski A. Spinal ependymomas--the value of postoperative radiotherapy for residual disease control. *Br J Neurosurg* 1996;10:559-566. Available at: <http://www.ncbi.nlm.nih.gov/pubmed/9115651>.
242. Lee TT, Gromelski EB, Green BA. Surgical treatment of spinal ependymoma and post-operative radiotherapy. *Acta Neurochir (Wien)* 1998;140:309-313. Available at: <http://www.ncbi.nlm.nih.gov/pubmed/9689321>.
243. Akyurek S, Chang EL, Yu TK, et al. Spinal myxopapillary ependymoma outcomes in patients treated with surgery and radiotherapy at M.D. Anderson Cancer Center. *J Neurooncol* 2006;80:177-183. Available at: <http://www.ncbi.nlm.nih.gov/pubmed/16648988>.
244. Pica A, Miller R, Villa S, et al. The results of surgery, with or without radiotherapy, for primary spinal myxopapillary ependymoma: a retrospective study from the rare cancer network. *Int J Radiat Oncol Biol*

- Phys 2009;74:1114-1120. Available at: <http://www.ncbi.nlm.nih.gov/pubmed/19250760>.
245. Ryu SI, Kim DH, Chang SD. Stereotactic radiosurgery for hemangiomas and ependymomas of the spinal cord. *Neurosurg Focus* 2003;15:E10. Available at: <http://www.ncbi.nlm.nih.gov/pubmed/15323467>.
246. Gerszten PC, Burton SA, Ozhasoglu C, et al. Radiosurgery for benign intradural spinal tumors. *Neurosurgery* 2008;62:887-895; discussion 895-886. Available at: <http://www.ncbi.nlm.nih.gov/pubmed/18496194>.
247. Dodd RL, Ryu MR, Kamnerdsupaphon P, et al. CyberKnife radiosurgery for benign intradural extramedullary spinal tumors. *Neurosurgery* 2006;58:674-685; discussion 674-685. Available at: <http://www.ncbi.nlm.nih.gov/pubmed/16575331>.
248. Garces-Ambrossi GL, McGirt MJ, Mehta VA, et al. Factors associated with progression-free survival and long-term neurological outcome after resection of intramedullary spinal cord tumors: analysis of 101 consecutive cases. *J Neurosurg Spine* 2009;11:591-599. Available at: <http://www.ncbi.nlm.nih.gov/pubmed/19929363>.
249. Mahmood A, Caccamo DV, Tomecek FJ, Malik GM. Atypical and malignant meningiomas: a clinicopathological review. *Neurosurgery* 1993;33:955-963. Available at: <http://www.ncbi.nlm.nih.gov/pubmed/8134008>.
250. Vernooij MW, Ikram MA, Tanghe HL, et al. Incidental findings on brain MRI in the general population. *N Engl J Med* 2007;357:1821-1828. Available at: <http://www.ncbi.nlm.nih.gov/pubmed/17978290>.
251. Lieu AS, Howng SL. Intracranial meningiomas and epilepsy: incidence, prognosis and influencing factors. *Epilepsy Res* 2000;38:45-52. Available at: <http://www.ncbi.nlm.nih.gov/pubmed/10604605>.
252. Campbell BA, Jhamb A, Maguire JA, et al. Meningiomas in 2009: controversies and future challenges. *Am J Clin Oncol* 2009;32:73-85. Available at: <http://www.ncbi.nlm.nih.gov/pubmed/19194129>.
253. Nathoo N, Ugokwe K, Chang AS, et al. The role of 111indium-octreotide brain scintigraphy in the diagnosis of cranial, dural-based meningiomas. *J Neurooncol* 2007;81:167-174. Available at: <http://www.ncbi.nlm.nih.gov/pubmed/16850106>.
254. Nyuyki F, Plotkin M, Graf R, et al. Potential impact of (68)Ga-DOTATOC PET/CT on stereotactic radiotherapy planning of meningiomas. *Eur J Nucl Med Mol Imaging* 2010;37:310-318. Available at: <http://www.ncbi.nlm.nih.gov/pubmed/19763565>.
255. Gehler B, Paulsen F, Oksuz MO, et al. [68Ga]-DOTATOC-PET/CT for meningioma IMRT treatment planning. *Radiat Oncol* 2009;4:56. Available at: <http://www.ncbi.nlm.nih.gov/pubmed/19922642>.
256. Nakamura M, Roser F, Michel J, et al. The natural history of incidental meningiomas. *Neurosurgery* 2003;53:62-70; discussion 70-61. Available at: <http://www.ncbi.nlm.nih.gov/pubmed/12823874>.
257. Olivero WC, Lister JR, Elwood PW. The natural history and growth rate of asymptomatic meningiomas: a review of 60 patients. *J Neurosurg* 1995;83:222-224. Available at: <http://www.ncbi.nlm.nih.gov/pubmed/7616265>.
258. Stafford SL, Perry A, Suman VJ, et al. Primarily resected meningiomas: outcome and prognostic factors in 581 Mayo Clinic patients, 1978 through 1988. *Mayo Clin Proc* 1998;73:936-942. Available at: <http://www.ncbi.nlm.nih.gov/pubmed/9787740>.
259. Mahmood A, Qureshi NH, Malik GM. Intracranial meningiomas: analysis of recurrence after surgical treatment. *Acta Neurochir (Wien)* 1994;126:53-58. Available at: <http://www.ncbi.nlm.nih.gov/pubmed/8042555>.

260. Mathiesen T, Lindquist C, Kihlstrom L, Karlsson B. Recurrence of cranial base meningiomas. *Neurosurgery* 1996;39:2-7; discussion 8-9. Available at: <http://www.ncbi.nlm.nih.gov/pubmed/8805134>.
261. Perry A, Stafford SL, Scheithauer BW, et al. Meningioma grading: an analysis of histologic parameters. *Am J Surg Pathol* 1997;21:1455-1465. Available at: <http://www.ncbi.nlm.nih.gov/pubmed/9414189>.
262. Simpson D. The recurrence of intracranial meningiomas after surgical treatment. *J Neurol Neurosurg Psychiatry* 1957;20:22-39. Available at: <http://www.ncbi.nlm.nih.gov/pubmed/13406590>.
263. Condra KS, Buatti JM, Mendenhall WM, et al. Benign meningiomas: primary treatment selection affects survival. *Int J Radiat Oncol Biol Phys* 1997;39:427-436. Available at: <http://www.ncbi.nlm.nih.gov/pubmed/9308947>.
264. Soyuer S, Chang EL, Selek U, et al. Radiotherapy after surgery for benign cerebral meningioma. *Radiother Oncol* 2004;71:85-90. Available at: <http://www.ncbi.nlm.nih.gov/pubmed/15066300>.
265. Aghi MK, Carter BS, Cosgrove GR, et al. Long-term recurrence rates of atypical meningiomas after gross total resection with or without postoperative adjuvant radiation. *Neurosurgery* 2009;64:56-60; discussion 60. Available at: <http://www.ncbi.nlm.nih.gov/pubmed/19145156>.
266. Hug EB, Devries A, Thornton AF, et al. Management of atypical and malignant meningiomas: role of high-dose, 3D-conformal radiation therapy. *J Neurooncol* 2000;48:151-160. Available at: <http://www.ncbi.nlm.nih.gov/pubmed/11083080>.
267. Yang SY, Park CK, Park SH, et al. Atypical and anaplastic meningiomas: prognostic implications of clinicopathological features. *J Neurol Neurosurg Psychiatry* 2008;79:574-580. Available at: <http://www.ncbi.nlm.nih.gov/pubmed/17766430>.
268. Pollock BE, Stafford SL, Utter A, et al. Stereotactic radiosurgery provides equivalent tumor control to Simpson Grade 1 resection for patients with small- to medium-size meningiomas. *Int J Radiat Oncol Biol Phys* 2003;55:1000-1005. Available at: <http://www.ncbi.nlm.nih.gov/pubmed/12605979>.
269. Kondziolka D, Mathieu D, Lunsford LD, et al. Radiosurgery as definitive management of intracranial meningiomas. *Neurosurgery* 2008;62:53-58; discussion 58-60. Available at: <http://www.ncbi.nlm.nih.gov/pubmed/18300891>.
270. Compter I, Zaugg K, Houben RM, et al. High symptom improvement and local tumor control using stereotactic radiotherapy when given early after diagnosis of meningioma. A multicentre study. *Strahlenther Onkol* 2012;188:887-893. Available at: <http://www.ncbi.nlm.nih.gov/pubmed/22961046>.
271. Chamberlain MC, Glantz MJ, Fadul CE. Recurrent meningioma: salvage therapy with long-acting somatostatin analogue. *Neurology* 2007;69:969-973. Available at: <http://www.ncbi.nlm.nih.gov/pubmed/17785665>.
272. Johnson DR, Kimmel DW, Burch PA, et al. Phase II study of subcutaneous octreotide in adults with recurrent or progressive meningioma and meningeal hemangiopericytoma. *Neuro Oncol* 2011;13:530-535. Available at: <http://www.ncbi.nlm.nih.gov/pubmed/21558077>.
273. Chamberlain MC, Glantz MJ. Interferon-alpha for recurrent World Health Organization grade 1 intracranial meningiomas. *Cancer* 2008;113:2146-2151. Available at: <http://www.ncbi.nlm.nih.gov/pubmed/18756531>.
274. Barnholtz-Sloan JS, Sloan AE, Davis FG, et al. Incidence proportions of brain metastases in patients diagnosed (1973 to 2001) in the Metropolitan Detroit Cancer Surveillance System. *J Clin Oncol* 2004;22:2865-2872. Available at: <http://www.ncbi.nlm.nih.gov/pubmed/15254054>.

275. Schouten LJ, Rutten J, Huvencers HA, Twijnstra A. Incidence of brain metastases in a cohort of patients with carcinoma of the breast, colon, kidney, and lung and melanoma. *Cancer* 2002;94:2698-2705. Available at: <http://www.ncbi.nlm.nih.gov/pubmed/12173339>.

276. Lin NU, Bellon JR, Winer EP. CNS metastases in breast cancer. *J Clin Oncol* 2004;22:3608-3617. Available at: <http://www.ncbi.nlm.nih.gov/pubmed/15337811>.

277. Eichler AF, Loeffler JS. Multidisciplinary management of brain metastases. *Oncologist* 2007;12:884-898. Available at: <http://www.ncbi.nlm.nih.gov/pubmed/17673619>.

278. Barker FG, 2nd. Craniotomy for the resection of metastatic brain tumors in the U.S., 1988-2000: decreasing mortality and the effect of provider caseload. *Cancer* 2004;100:999-1007. Available at: <http://www.ncbi.nlm.nih.gov/pubmed/14983496>.

279. Patchell RA, Tibbs PA, Regine WF, et al. Postoperative radiotherapy in the treatment of single metastases to the brain: a randomized trial. *JAMA* 1998;280:1485-1489. Available at: <http://www.ncbi.nlm.nih.gov/pubmed/9809728>.

280. Paek SH, Audu PB, Sperling MR, et al. Reevaluation of surgery for the treatment of brain metastases: review of 208 patients with single or multiple brain metastases treated at one institution with modern neurosurgical techniques. *Neurosurgery* 2005;56:1021-1034; discussion 1021-1034. Available at: <http://www.ncbi.nlm.nih.gov/pubmed/15854250>.

281. Stark AM, Tscheslog H, Buhl R, et al. Surgical treatment for brain metastases: prognostic factors and survival in 177 patients. *Neurosurg Rev* 2005;28:115-119. Available at: <http://www.ncbi.nlm.nih.gov/pubmed/15609059>.

282. Suh JH. Stereotactic radiosurgery for the management of brain metastases. *N Engl J Med* 2010;362:1119-1127. Available at: <http://www.ncbi.nlm.nih.gov/pubmed/20335588>.

283. Bhatnagar AK, Flickinger JC, Kondziolka D, Lunsford LD. Stereotactic radiosurgery for four or more intracranial metastases. *Int J Radiat Oncol Biol Phys* 2006;64:898-903. Available at: <http://www.ncbi.nlm.nih.gov/pubmed/16338097>.

284. Bhatnagar AK, Kondziolka D, Lunsford LD, Flickinger JC. Recursive partitioning analysis of prognostic factors for patients with four or more intracranial metastases treated with radiosurgery. *Technol Cancer Res Treat* 2007;6:153-160. Available at: <http://www.ncbi.nlm.nih.gov/pubmed/17535022>.

285. Banfill KE, Bownes PJ, St Clair SE, et al. Stereotactic radiosurgery for the treatment of brain metastases: impact of cerebral disease burden on survival. *Br J Neurosurg* 2012;26:674-678. Available at: <http://www.ncbi.nlm.nih.gov/pubmed/22747250>.

286. Chang WS, Kim HY, Chang JW, et al. Analysis of radiosurgical results in patients with brain metastases according to the number of brain lesions: is stereotactic radiosurgery effective for multiple brain metastases? *J Neurosurg* 2010;113 Suppl:73-78. Available at: <http://www.ncbi.nlm.nih.gov/pubmed/21121789>.

287. Karlsson B, Hanssens P, Wolff R, et al. Thirty years' experience with Gamma Knife surgery for metastases to the brain. *J Neurosurg* 2009;111:449-457. Available at: <http://www.ncbi.nlm.nih.gov/pubmed/19199505>.

288. Kased N, Binder DK, McDermott MW, et al. Gamma Knife radiosurgery for brain metastases from primary breast cancer. *Int J Radiat Oncol Biol Phys* 2009;75:1132-1140. Available at: <http://www.ncbi.nlm.nih.gov/pubmed/19345514>.

289. Hanson PW, Elaimy AL, Lamoreaux WT, et al. A concise review of the efficacy of stereotactic radiosurgery in the management of melanoma and renal cell carcinoma brain metastases. *World J Surg Oncol* 2012;10:176. Available at: <http://www.ncbi.nlm.nih.gov/pubmed/22931379>.

290. Hunter GK, Suh JH, Reuther AM, et al. Treatment of five or more brain metastases with stereotactic radiosurgery. *Int J Radiat Oncol Biol Phys* 2012;83:1394-1398. Available at:

<http://www.ncbi.nlm.nih.gov/pubmed/22209150>.

291. Aoyama H, Shirato H, Tago M, et al. Stereotactic radiosurgery plus whole-brain radiation therapy vs stereotactic radiosurgery alone for treatment of brain metastases: a randomized controlled trial. *JAMA* 2006;295:2483-2491. Available at:

<http://www.ncbi.nlm.nih.gov/pubmed/16757720>.

292. Chang EL, Wefel JS, Hess KR, et al. Neurocognition in patients with brain metastases treated with radiosurgery or radiosurgery plus whole-brain irradiation: a randomised controlled trial. *Lancet Oncol* 2009;10:1037-1044. Available at:

<http://www.ncbi.nlm.nih.gov/pubmed/19801201>.

293. Kocher M, Soffietti R, Abacioglu U, et al. Adjuvant whole-brain radiotherapy versus observation after radiosurgery or surgical resection of one to three cerebral metastases: results of the EORTC 22952-26001 study. *J Clin Oncol* 2011;29:134-141. Available at:

<http://www.ncbi.nlm.nih.gov/pubmed/21041710>.

294. Tsao M, Xu W, Sahgal A. A meta-analysis evaluating stereotactic radiosurgery, whole-brain radiotherapy, or both for patients presenting with a limited number of brain metastases. *Cancer* 2012;118:2486-2493. Available at: <http://www.ncbi.nlm.nih.gov/pubmed/21887683>.

295. O'Neill BP, Iturria NJ, Link MJ, et al. A comparison of surgical resection and stereotactic radiosurgery in the treatment of solitary brain metastases. *Int J Radiat Oncol Biol Phys* 2003;55:1169-1176. Available at: <http://www.ncbi.nlm.nih.gov/pubmed/12654423>.

296. Rades D, Kueter JD, Veninga T, et al. Whole brain radiotherapy plus stereotactic radiosurgery (WBRT+SRS) versus surgery plus whole brain radiotherapy (OP+WBRT) for 1-3 brain metastases: results of a matched pair analysis. *Eur J Cancer* 2009;45:400-404. Available at:

<http://www.ncbi.nlm.nih.gov/pubmed/19062269>.

297. Schoggl A, Kitz K, Reddy M, et al. Defining the role of stereotactic radiosurgery versus microsurgery in the treatment of single brain metastases. *Acta Neurochir (Wien)* 2000;142:621-626. Available at:

<http://www.ncbi.nlm.nih.gov/pubmed/10949435>.

298. Yamamoto M, Serizawa T, Shuto T, et al. Stereotactic radiosurgery for patients with multiple brain metastases (JL GK0901): a multi-institutional prospective observational study. *Lancet Oncol* 2014;15:387-395. Available at: <http://www.ncbi.nlm.nih.gov/pubmed/24621620>.

299. Muacevic A, Wowra B, Siefert A, et al. Microsurgery plus whole brain irradiation versus Gamma Knife surgery alone for treatment of single metastases to the brain: a randomized controlled multicentre phase III trial. *J Neurooncol* 2008;87:299-307. Available at:

<http://www.ncbi.nlm.nih.gov/pubmed/18157648>.

300. Akyurek S, Chang EL, Mahajan A, et al. Stereotactic radiosurgical treatment of cerebral metastases arising from breast cancer. *Am J Clin Oncol* 2007;30:310-314. Available at:

<http://www.ncbi.nlm.nih.gov/pubmed/17551311>.

301. Loeffler JS, Kooy HM, Wen PY, et al. The treatment of recurrent brain metastases with stereotactic radiosurgery. *J Clin Oncol* 1990;8:576-582. Available at:

<http://www.ncbi.nlm.nih.gov/pubmed/2179476>.

302. Noel G, Medioni J, Valery CA, et al. Three irradiation treatment options including radiosurgery for brain metastases from primary lung cancer. *Lung Cancer* 2003;41:333-343. Available at:

<http://www.ncbi.nlm.nih.gov/pubmed/12928124>.

303. Noel G, Proudhom MA, Valery CA, et al. Radiosurgery for re-irradiation of brain metastasis: results in 54 patients. *Radiother Oncol* 2001;60:61-67. Available at:

<http://www.ncbi.nlm.nih.gov/pubmed/11410305>.

304. Sheehan J, Kondziolka D, Flickinger J, Lunsford LD. Radiosurgery for patients with recurrent small cell lung carcinoma metastatic to the

brain: outcomes and prognostic factors. *J Neurosurg* 2005;102 Suppl:247-254. Available at: <http://www.ncbi.nlm.nih.gov/pubmed/15662819>.

305. Caballero JA, Sneed PK, Lamborn KR, et al. Prognostic factors for survival in patients treated with stereotactic radiosurgery for recurrent brain metastases after prior whole brain radiotherapy. *Int J Radiat Oncol Biol Phys* 2012;83:303-309. Available at: <http://www.ncbi.nlm.nih.gov/pubmed/22079723>.

306. Patchell RA, Tibbs PA, Walsh JW, et al. A randomized trial of surgery in the treatment of single metastases to the brain. *N Engl J Med* 1990;322:494-500. Available at: <http://www.ncbi.nlm.nih.gov/pubmed/2405271>.

307. Vecht CJ, Haaxma-Reiche H, Noordijk EM, et al. Treatment of single brain metastasis: radiotherapy alone or combined with neurosurgery? *Ann Neurol* 1993;33:583-590. Available at: <http://www.ncbi.nlm.nih.gov/pubmed/8498838>.

308. Mintz AH, Kestle J, Rathbone MP, et al. A randomized trial to assess the efficacy of surgery in addition to radiotherapy in patients with a single cerebral metastasis. *Cancer* 1996;78:1470-1476. Available at: <http://www.ncbi.nlm.nih.gov/pubmed/8839553>.

309. Andrews DW, Scott CB, Sperduto PW, et al. Whole brain radiation therapy with or without stereotactic radiosurgery boost for patients with one to three brain metastases: phase III results of the RTOG 9508 randomised trial. *Lancet* 2004;363:1665-1672. Available at: <http://www.ncbi.nlm.nih.gov/pubmed/15158627>.

310. Kondziolka D, Patel A, Lunsford LD, et al. Stereotactic radiosurgery plus whole brain radiotherapy versus radiotherapy alone for patients with multiple brain metastases. *Int J Radiat Oncol Biol Phys* 1999;45:427-434. Available at: <http://www.ncbi.nlm.nih.gov/pubmed/10487566>.

311. Patil CG, Pricola K, Sarmiento JM, et al. Whole brain radiation therapy (WBRT) alone versus WBRT and radiosurgery for the treatment of brain metastases. *Cochrane Database Syst Rev* 2012;9:CD006121. Available at: <http://www.ncbi.nlm.nih.gov/pubmed/22972090>.

312. Cooper JS, Steinfield AD, Lerch IA. Cerebral metastases: value of reirradiation in selected patients. *Radiology* 1990;174:883-885. Available at: <http://www.ncbi.nlm.nih.gov/pubmed/2305074>.

313. Sadikov E, Bezjak A, Yi QL, et al. Value of whole brain re-irradiation for brain metastases--single centre experience. *Clin Oncol (R Coll Radiol)* 2007;19:532-538. Available at: <http://www.ncbi.nlm.nih.gov/pubmed/17662582>.

314. Wong WW, Schild SE, Sawyer TE, Shaw EG. Analysis of outcome in patients reirradiated for brain metastases. *Int J Radiat Oncol Biol Phys* 1996;34:585-590. Available at: <http://www.ncbi.nlm.nih.gov/pubmed/8621282>.

315. Guerrieri M, Wong K, Ryan G, et al. A randomised phase III study of palliative radiation with concomitant carboplatin for brain metastases from non-small cell carcinoma of the lung. *Lung Cancer* 2004;46:107-111. Available at: <http://www.ncbi.nlm.nih.gov/pubmed/15364138>.

316. Verger E, Gil M, Yaya R, et al. Temozolomide and concomitant whole brain radiotherapy in patients with brain metastases: a phase II randomized trial. *Int J Radiat Oncol Biol Phys* 2005;61:185-191. Available at: <http://www.ncbi.nlm.nih.gov/pubmed/15629610>.

317. Antonadou D, Paraskevaidis M, Sarris G, et al. Phase II randomized trial of temozolomide and concurrent radiotherapy in patients with brain metastases. *J Clin Oncol* 2002;20:3644-3650. Available at: <http://www.ncbi.nlm.nih.gov/pubmed/12202665>.

318. Ewend MG, Brem S, Gilbert M, et al. Treatment of single brain metastasis with resection, intracavity carmustine polymer wafers, and radiation therapy is safe and provides excellent local control. *Clin*

Cancer Res 2007;13:3637-3641. Available at:
<http://www.ncbi.nlm.nih.gov/pubmed/17575228>.

319. Agarwala SS, Kirkwood JM, Gore M, et al. Temozolomide for the treatment of brain metastases associated with metastatic melanoma: a phase II study. J Clin Oncol 2004;22:2101-2107. Available at:
<http://www.ncbi.nlm.nih.gov/pubmed/15169796>.

320. Krown SE, Niedzwiecki D, Hwu WJ, et al. Phase II study of temozolomide and thalidomide in patients with metastatic melanoma in the brain: high rate of thromboembolic events (CALGB 500102). Cancer 2006;107:1883-1890. Available at:
<http://www.ncbi.nlm.nih.gov/pubmed/16986123>.

321. Lassman AB, Abrey LE, Shah GD, et al. Systemic high-dose intravenous methotrexate for central nervous system metastases. J Neurooncol 2006;78:255-260. Available at:
<http://www.ncbi.nlm.nih.gov/pubmed/16344918>.

322. Cocconi G, Lottici R, Bisagni G, et al. Combination therapy with platinum and etoposide of brain metastases from breast carcinoma. Cancer Invest 1990;8:327-334. Available at:
<http://www.ncbi.nlm.nih.gov/pubmed/2207757>.

323. Franciosi V, Cocconi G, Michiara M, et al. Front-line chemotherapy with cisplatin and etoposide for patients with brain metastases from breast carcinoma, nonsmall cell lung carcinoma, or malignant melanoma: a prospective study. Cancer 1999;85:1599-1605. Available at:
<http://www.ncbi.nlm.nih.gov/pubmed/10193952>.

324. Rivera E, Meyers C, Groves M, et al. Phase I study of capecitabine in combination with temozolomide in the treatment of patients with brain metastases from breast carcinoma. Cancer 2006;107:1348-1354. Available at:
<http://www.ncbi.nlm.nih.gov/pubmed/16909414>.

325. Metro G, Foglietta J, Russillo M, et al. Clinical outcome of patients with brain metastases from HER2-positive breast cancer treated with

lapatinib and capecitabine. Ann Oncol 2011;22:625-630. Available at:
<http://www.ncbi.nlm.nih.gov/pubmed/20724575>.

326. Sutherland S, Ashley S, Miles D, et al. Treatment of HER2-positive metastatic breast cancer with lapatinib and capecitabine in the lapatinib expanded access programme, including efficacy in brain metastases--the UK experience. Br J Cancer 2010;102:995-1002. Available at:
<http://www.ncbi.nlm.nih.gov/pubmed/20179708>.

327. Hedde JP, Neuhaus T, Schuller H, et al. A phase I/II trial of topotecan and radiation therapy for brain metastases in patients with solid tumors. Int J Radiat Oncol Biol Phys 2007;68:839-844. Available at:
<http://www.ncbi.nlm.nih.gov/pubmed/17379446>.

328. Neuhaus T, Ko Y, Muller RP, et al. A phase III trial of topotecan and whole brain radiation therapy for patients with CNS-metastases due to lung cancer. Br J Cancer 2009;100:291-297. Available at:
<http://www.ncbi.nlm.nih.gov/pubmed/19127261>.

329. Margolin K, Ernstoff MS, Hamid O, et al. Ipilimumab in patients with melanoma and brain metastases: an open-label, phase 2 trial. Lancet Oncol 2012;13:459-465. Available at:
<http://www.ncbi.nlm.nih.gov/pubmed/22456429>.

330. Long GV, Trefzer U, Davies MA, et al. Dabrafenib in patients with Val600Glu or Val600Lys BRAF-mutant melanoma metastatic to the brain (BREAK-MB): a multicentre, open-label, phase 2 trial. Lancet Oncol 2012;13:1087-1095. Available at:
<http://www.ncbi.nlm.nih.gov/pubmed/23051966>.

331. Dummer R, Goldinger SM, Turttschi CP, et al. Vemurafenib in patients with BRAF(V600) mutation-positive melanoma with symptomatic brain metastases: final results of an open-label pilot study. Eur J Cancer 2014;50:611-621. Available at:
<http://www.ncbi.nlm.nih.gov/pubmed/24295639>.

332. Lang FF, Chang EL, Abi-Said D. Metastatic brain tumors. In: Winn H, ed. Youman's Neurological Surgery (ed 5th). Philadelphia: Saunders; 2004:1077-1097.
333. Pavlidis N. The diagnostic and therapeutic management of leptomeningeal carcinomatosis. *Ann Oncol* 2004;15 Suppl 4:iv285-291. Available at: <http://www.ncbi.nlm.nih.gov/pubmed/15477323>.
334. Waki F, Ando M, Takashima A, et al. Prognostic factors and clinical outcomes in patients with leptomeningeal metastasis from solid tumors. *J Neurooncol* 2009;93:205-212. Available at: <http://www.ncbi.nlm.nih.gov/pubmed/19043775>.
335. Clarke JL, Perez HR, Jacks LM, et al. Leptomeningeal metastases in the MRI era. *Neurology* 2010;74:1449-1454. Available at: <http://www.ncbi.nlm.nih.gov/pubmed/20439847>.
336. Liaw CC, Ng KT, Huang JS, et al. Meningeal carcinomatosis from solid tumors: clinical analysis of 42 cases. *J Formos Med Assoc* 1992;91:299-303. Available at: <http://www.ncbi.nlm.nih.gov/pubmed/1354692>.
337. Wasserstrom WR, Glass JP, Posner JB. Diagnosis and treatment of leptomeningeal metastases from solid tumors: experience with 90 patients. *Cancer* 1982;49:759-772. Available at: <http://www.ncbi.nlm.nih.gov/pubmed/6895713>.
338. Sandberg DI, Bilsky MH, Souweidane MM, et al. Ommaya reservoirs for the treatment of leptomeningeal metastases. *Neurosurgery* 2000;47:49-54; discussion 54-45. Available at: <http://www.ncbi.nlm.nih.gov/pubmed/10917346>.
339. Fleischhack G, Jaehde U, Bode U. Pharmacokinetics following intraventricular administration of chemotherapy in patients with neoplastic meningitis. *Clin Pharmacokinet* 2005;44:1-31. Available at: <http://www.ncbi.nlm.nih.gov/pubmed/15634030>.
340. Boogerd W, van den Bent MJ, Koehler PJ, et al. The relevance of intraventricular chemotherapy for leptomeningeal metastasis in breast cancer: a randomised study. *Eur J Cancer* 2004;40:2726-2733. Available at: <http://www.ncbi.nlm.nih.gov/pubmed/15571954>.
341. Glantz MJ, Jaeckle KA, Chamberlain MC, et al. A randomized controlled trial comparing intrathecal sustained-release cytarabine (DepoCyt) to intrathecal methotrexate in patients with neoplastic meningitis from solid tumors. *Clin Cancer Res* 1999;5:3394-3402. Available at: <http://www.ncbi.nlm.nih.gov/pubmed/10589750>.
342. Grossman SA, Finkelstein DM, Ruckdeschel JC, et al. Randomized prospective comparison of intraventricular methotrexate and thiotepa in patients with previously untreated neoplastic meningitis. Eastern Cooperative Oncology Group. *J Clin Oncol* 1993;11:561-569. Available at: <http://www.ncbi.nlm.nih.gov/pubmed/8445432>.
343. Chamberlain MC, Johnston SK, Van Horn A, Glantz MJ. Recurrent lymphomatous meningitis treated with intra-CSF rituximab and liposomal ara-C. *J Neurooncol* 2009;91:271-277. Available at: <http://www.ncbi.nlm.nih.gov/pubmed/18820836>.
344. Groves MD, Glantz MJ, Chamberlain MC, et al. A multicenter phase II trial of intrathecal topotecan in patients with meningeal malignancies. *Neuro Oncol* 2008;10:208-215. Available at: <http://www.ncbi.nlm.nih.gov/pubmed/18316473>.
345. Chamberlain MC, Tsao-Wei DD, Groshen S. Phase II trial of intracerebrospinal fluid etoposide in the treatment of neoplastic meningitis. *Cancer* 2006;106:2021-2027. Available at: <http://www.ncbi.nlm.nih.gov/pubmed/16583432>.
346. Zagouri F, Sergentanis TN, Bartsch R, et al. Intrathecal administration of trastuzumab for the treatment of meningeal carcinomatosis in HER2-positive metastatic breast cancer: a systematic review and pooled analysis. *Breast Cancer Res Treat* 2013;139:13-22. Available at: <http://www.ncbi.nlm.nih.gov/pubmed/23588955>.

347. Chamberlain MC. A phase II trial of intra-cerebrospinal fluid alpha interferon in the treatment of neoplastic meningitis. *Cancer* 2002;94:2675-2680. Available at: <http://www.ncbi.nlm.nih.gov/pubmed/12173336>.
348. Glantz MJ, LaFollette S, Jaeckle KA, et al. Randomized trial of a slow-release versus a standard formulation of cytarabine for the intrathecal treatment of lymphomatous meningitis. *J Clin Oncol* 1999;17:3110-3116. Available at: <http://www.ncbi.nlm.nih.gov/pubmed/10506606>.
349. Grommes C, Oxnard GR, Kris MG, et al. "Pulsatile" high-dose weekly erlotinib for CNS metastases from EGFR mutant non-small cell lung cancer. *Neuro Oncol* 2011;13:1364-1369. Available at: <http://www.ncbi.nlm.nih.gov/pubmed/21865399>.
350. Wong DA, Fornasier VL, MacNab I. Spinal metastases: the obvious, the occult, and the impostors. *Spine (Phila Pa 1976)* 1990;15:1-4. Available at: <http://www.ncbi.nlm.nih.gov/pubmed/2326692>.
351. Ibrahim A, Crockard A, Antonietti P, et al. Does spinal surgery improve the quality of life for those with extradural (spinal) osseous metastases? An international multicenter prospective observational study of 223 patients. Invited submission from the Joint Section Meeting on Disorders of the Spine and Peripheral Nerves, March 2007. *J Neurosurg Spine* 2008;8:271-278. Available at: <http://www.ncbi.nlm.nih.gov/pubmed/18312079>.
352. Byrne TN. Spinal cord compression from epidural metastases. *N Engl J Med* 1992;327:614-619. Available at: <http://www.ncbi.nlm.nih.gov/pubmed/1296600>.
353. Schmidt MH, Klimo P, Jr., Vrionis FD. Metastatic spinal cord compression. *J Natl Compr Canc Netw* 2005;3:711-719. Available at: <http://www.ncbi.nlm.nih.gov/pubmed/16194459>.
354. Helweg-Larsen S, Sorensen PS. Symptoms and signs in metastatic spinal cord compression: a study of progression from first symptom until diagnosis in 153 patients. *Eur J Cancer* 1994;30A:396-398. Available at: <http://www.ncbi.nlm.nih.gov/pubmed/8204366>.
355. Levack P, Graham J, Collie D, et al. Don't wait for a sensory level—listen to the symptoms: a prospective audit of the delays in diagnosis of malignant cord compression. *Clin Oncol (R Coll Radiol)* 2002;14:472-480. Available at: <http://www.ncbi.nlm.nih.gov/pubmed/12512970>.
356. Sundaresan N, Rothman A, Manhart K, Kelliher K. Surgery for solitary metastases of the spine: rationale and results of treatment. *Spine (Phila Pa 1976)* 2002;27:1802-1806. Available at: <http://www.ncbi.nlm.nih.gov/pubmed/12195075>.
357. North RB, LaRocca VR, Schwartz J, et al. Surgical management of spinal metastases: analysis of prognostic factors during a 10-year experience. *J Neurosurg Spine* 2005;2:564-573. Available at: <http://www.ncbi.nlm.nih.gov/pubmed/15945430>.
358. Tomita K, Kawahara N, Kobayashi T, et al. Surgical strategy for spinal metastases. *Spine (Phila Pa 1976)* 2001;26:298-306. Available at: <http://www.ncbi.nlm.nih.gov/pubmed/11224867>.
359. Tokuhashi Y, Matsuzaki H, Oda H, et al. A revised scoring system for preoperative evaluation of metastatic spine tumor prognosis. *Spine (Phila Pa 1976)* 2005;30:2186-2191. Available at: <http://www.ncbi.nlm.nih.gov/pubmed/16205345>.
360. van der Linden YM, Dijkstra SP, Vonk EJ, et al. Prediction of survival in patients with metastases in the spinal column: results based on a randomized trial of radiotherapy. *Cancer* 2005;103:320-328. Available at: <http://www.ncbi.nlm.nih.gov/pubmed/15593360>.
361. Bartels RH, Feuth T, van der Maazen R, et al. Development of a model with which to predict the life expectancy of patients with spinal epidural metastasis. *Cancer* 2007;110:2042-2049. Available at: <http://www.ncbi.nlm.nih.gov/pubmed/17853394>.

362. Choi D, Crockard A, Bungler C, et al. Review of metastatic spine tumour classification and indications for surgery: the consensus statement of the Global Spine Tumour Study Group. *Eur Spine J* 2010;19:215-222. Available at: <http://www.ncbi.nlm.nih.gov/pubmed/20039084>.

363. Eleraky M, Papanastassiou I, Vrionis FD. Management of metastatic spine disease. *Curr Opin Support Palliat Care* 2010;4:182-188. Available at: <http://www.ncbi.nlm.nih.gov/pubmed/20671554>.

364. Klimo P, Jr., Thompson CJ, Kestle JR, Schmidt MH. A meta-analysis of surgery versus conventional radiotherapy for the treatment of metastatic spinal epidural disease. *Neuro Oncol* 2005;7:64-76. Available at: <http://www.ncbi.nlm.nih.gov/pubmed/15701283>.

365. Witham TF, Khavkin YA, Gallia GL, et al. Surgery insight: current management of epidural spinal cord compression from metastatic spine disease. *Nat Clin Pract Neurol* 2006;2:87-94; quiz 116. Available at: <http://www.ncbi.nlm.nih.gov/pubmed/16932530>.

366. Patchell RA, Tibbs PA, Regine WF, et al. Direct decompressive surgical resection in the treatment of spinal cord compression caused by metastatic cancer: a randomised trial. *Lancet* 2005;366:643-648. Available at: <http://www.ncbi.nlm.nih.gov/pubmed/16112300>.

367. Patil CG, Lad SP, Santarelli J, Boakye M. National inpatient complications and outcomes after surgery for spinal metastasis from 1993-2002. *Cancer* 2007;110:625-630. Available at: <http://www.ncbi.nlm.nih.gov/pubmed/17577227>.

368. Itshayek E, Yamada J, Bilsky M, et al. Timing of surgery and radiotherapy in the management of metastatic spine disease: a systematic review. *Int J Oncol* 2010;36:533-544. Available at: <http://www.ncbi.nlm.nih.gov/pubmed/20126972>.

369. Maranzano E, Bellavita R, Rossi R, et al. Short-course versus split-course radiotherapy in metastatic spinal cord compression: results of a

phase III, randomized, multicenter trial. *J Clin Oncol* 2005;23:3358-3365. Available at: <http://www.ncbi.nlm.nih.gov/pubmed/15738534>.

370. Gerszten PC, Mendel E, Yamada Y. Radiotherapy and radiosurgery for metastatic spine disease: what are the options, indications, and outcomes? *Spine (Phila Pa 1976)* 2009;34:S78-92. Available at: <http://www.ncbi.nlm.nih.gov/pubmed/19829280>.

371. Gerszten PC, Burton SA, Ozhasoglu C, Welch WC. Radiosurgery for spinal metastases: clinical experience in 500 cases from a single institution. *Spine (Phila Pa 1976)* 2007;32:193-199. Available at: <http://www.ncbi.nlm.nih.gov/pubmed/17224814>.

372. Mendel E, Bourekas E, Gerszten P, Golan JD. Percutaneous techniques in the treatment of spine tumors: what are the diagnostic and therapeutic indications and outcomes? *Spine (Phila Pa 1976)* 2009;34:S93-100. Available at: <http://www.ncbi.nlm.nih.gov/pubmed/19829281>.

373. Sorensen S, Helweg-Larsen S, Mouridsen H, Hansen HH. Effect of high-dose dexamethasone in carcinomatous metastatic spinal cord compression treated with radiotherapy: a randomised trial. *Eur J Cancer* 1994;30A:22-27. Available at: <http://www.ncbi.nlm.nih.gov/pubmed/8142159>.

374. Vecht CJ, Haaxma-Reiche H, van Putten WL, et al. Initial bolus of conventional versus high-dose dexamethasone in metastatic spinal cord compression. *Neurology* 1989;39:1255-1257. Available at: <http://www.ncbi.nlm.nih.gov/pubmed/2771077>.

375. Heimdal K, Hirschberg H, Slettebo H, et al. High incidence of serious side effects of high-dose dexamethasone treatment in patients with epidural spinal cord compression. *J Neurooncol* 1992;12:141-144. Available at: <http://www.ncbi.nlm.nih.gov/pubmed/1560260>.

376. Kwok Y, Regine WF, Patchell RA. Radiation therapy alone for spinal cord compression: time to improve upon a relatively ineffective

status quo. J Clin Oncol 2005;23:3308-3310. Available at:
<http://www.ncbi.nlm.nih.gov/pubmed/15738546>.

377. Rades D, Stalpers LJA, Veninga T, et al. Evaluation of five radiation schedules and prognostic factors for metastatic spinal cord compression. J Clin Oncol 2005;23:3366-3375. Available at:
<http://www.ncbi.nlm.nih.gov/pubmed/15908648>.



**Discussion
update in
progress**