

The value of endoscope assistance during transcranial surgery for tuberculum sellae meningiomas

Sascha Marx, MD,¹ Stefan Clemens, MD, PhD,² and Henry W. S. Schroeder, MD, PhD¹

Departments of ¹Neurosurgery and ²Ophthalmology, University Medicine Greifswald, Germany

OBJECTIVE In tuberculum sellae meningioma (TSM) surgery, endonasal approaches are claimed to have a superior visual outcome compared with transcranial approaches. The authors question whether this is always true and analyze their series of cases of endoscope-assisted transcranial TSM surgery with special regard to the postoperative visual outcome in order to explore this issue.

METHODS All surgical procedures for TSM performed between 2003 and 2015 in the Department of Neurosurgery, University Medicine Greifswald, were retrospectively analyzed. Special attention was paid to the postoperative visual outcome.

RESULTS During the study period, 15 patients (12 female and 3 male) underwent surgery for TSM. Gross-total resection was achieved in 14 cases (93.3%) and near-total resection in 1. One patient suffered from a major stroke during surgery and had to be excluded from further analyses. No other complications occurred. Preoperatively, visual acuity was disturbed in 12 patients (80%) and visual field deficits were present in 11 patients (73.3%). In 3 patients (20%), the TSM was an incidental finding. Postoperatively, ophthalmological examination revealed an improvement of visual acuity in 10 (90.9%) of 11 patients and improvement of visual field deficits in 9 (90%) of 10 patients; no deterioration of visual acuity or visual field was seen in any patient. Visual acuity and visual field improvement was observed in all patients who had surgery within 3 years after the onset of visual disturbances. No tumor recurrence was observed during follow-up (mean 32 months, range 3–134 months). TSMs were approached via a frontolateral craniotomy in 7 patients and via a supraorbital craniotomy in 8. The use of the endoscope as an assistive device led to improved tumor visualization and consequent removal in areas that were hidden in the microscopic view in 6 patients (40%).

CONCLUSIONS The present series confirms a favorable visual outcome after TSM surgery via supraorbital or frontolateral endoscope-assisted approaches. With endoscopic visualization, major manipulation of the optic apparatus could be avoided, perhaps affecting the favorable visual outcome.

<https://thejns.org/doi/abs/10.3171/2016.11.JNS16713>

KEY WORDS tuberculum sellae meningioma; visual outcome; transcranial approach; endoscope-assisted microsurgery; pituitary surgery

TUBERCULUM sellae meningiomas (TSMs) represent a minority of all intracranial meningiomas.^{4,34} Since Harvey Cushing first described the successful removal of a TSM 100 years ago,³² neurosurgical approaches to TSMs have evolved, leading to the current transcranial and endonasal approaches.^{27,32} One major advantage claimed for the endonasal approach over transcranial approaches in TSM surgery is better visual outcome.^{6,10,12} Is the visual outcome, however, actually better with an endonasal approach? To explore this question we analyzed our series of endoscope-assisted transcranial TSM resections with special regard to postoperative visual outcome.

Methods

All cases involving surgical procedures for TSM performed since 2003 in the Department of Neurosurgery, University Medicine Greifswald, were retrospectively analyzed. Special attention was paid to the postoperative visual outcome, which was analyzed per patient and per eye. For both visual acuity and visual field, postoperative status was categorized as improved, stable, or deteriorated. In patients with data from comparable ophthalmological examinations in the pre- and postoperative course, visual acuity and visual field were graded as previously described.²³ To assess

ABBREVIATIONS MCA = middle cerebral artery; TSM = tuberculum sellae meningioma.

SUBMITTED March 20, 2016. **ACCEPTED** November 7, 2016.

INCLUDE WHEN CITING Published online April 7, 2017; DOI: 10.3171/2016.11.JNS16713.

TABLE 1. Patient characteristics

Case No.	Sex, Age (yrs)	Leading Preop Sx	Sx Duration (mos)	Tumor Size (L x W x H in mm)	Skin Incision	Use of Endoscope*	EOR	Compl
1	F, 39	Visual Sx	6	10 × 11 × 14	Behind hairline	A	GTR	None
2	F, 48	Visual Sx	8	32 × 30 × 25	Behind hairline	A	GTR	None
3	F, 49	Visual Sx	11	7 × 7 × 4	Eyebrow	A	GTR	None
4	F, 54	Visual Sx	6	14 × 13 × 10	Eyebrow	A	GTR	None
5	F, 27	Incidental	NA	25 × 21 × 17	Behind hairline	A, B	GTR	None
6	M, 64	Visual Sx	5	30 × 20 × 26	Eyebrow	A	GTR	None
7	F, 54	Visual Sx	24	26 × 28 × 20	Eyebrow	A	GTR	None
8	F, 69	Visual Sx	36	25 × 23 × 20	Eyebrow	A, B	GTR	None
9	F, 55	Visual Sx	2	27 × 23 × 26	Eyebrow	A, D	GTR	None
10	M, 72	Visual Sx	8	13 × 10 × 15	Behind hairline	A	GTR	Stroke
11	F, 61	Visual Sx	3	33 × 33 × 33	Eyebrow	A, B	GTR	None
12	F, 84	Visual Sx	132	27 × 22 × 24	Behind hairline	A	NTR	None
13	F, 30	Visual Sx	1	32 × 28 × 15	Behind hairline	A, B, C	GTR	None
14	M, 50	Incidental	NA	20 × 12 × 12	Behind hairline	A, B, C	GTR	None
15	F, 59	Incidental	NA	7 × 6 × 8	Eyebrow	A, B	GTR	None

Compl = complications; EOR = extent of resection; GTR = gross-total resection; H = height; L = length; NA = not applicable; NTR = near-total resection; Sx = symptom(s); W = width.

* A indicates final inspection; B indicates visualization and removal of tumor underneath the ipsilateral optic nerve; C indicates detection of intracanalicular tumor growth; and D indicates visualization of tumor on a steep tuberculum sellae.

the visual acuity, the modified logMAR scale was used.^{23,31} To assess visual field deficits, an ordinal scale²³ was used, as follows: 6 indicates normal visual field; 5, slight constriction; 4, loss of a single quadrant; 3, loss of 2 quadrants; 2, loss of 3 quadrants; 1, severe constriction; and 0, blindness.²³ Since short-term visual outcome is a strong predictor of long-term visual outcome after TSM surgery,²⁶ the postoperative visual acuity and visual field results that we present in this study were based on assessment performed 3–6 months after surgery unless otherwise noted.

In addition, tumor characteristics, surgical technique and nuances, extent of resection, and complications (surgical and nonsurgical) were analyzed. The tumor size was displayed as the largest diameter in all 3 dimensions (length, height, and width) on preoperative MRI. The evaluation of the extent of resection was mainly based on the surgeon's intraoperative impression, but postoperative MRI studies were evaluated by an independent neuroradiologist, and that assessment was also included in the evaluation.

Results

Patient Population

During the study period, 15 patients (12 female and 3 male) underwent surgery for TSM. The patients' mean age was 54.3 years (range 27–84 years). All surgeries were performed by the senior author (H.W.S.S.). All tumors were benign (WHO Grade I) and none had been previously treated. The mean tumor size was 22 mm × 19 mm × 18 mm. One patient (Case 3) suffered from both TSM and olfactory groove meningioma. Both lesions were removed in a single procedure. Gross-total resection was achieved in 14 patients (93.3%). In 1 patient (6.7%) a thin tumor layer had to be left in place, since it was infiltrating the

carotid artery wall (Case 12); postoperative MRI did not show residual tumor, but the resection was classified as near total. There was no sign of tumor recurrence in this patient or in any other during the follow-up period (mean 32 months, range 3–34 months).

Preoperatively, visual acuity was affected in 12 patients (80%) and 22 eyes (73.3%), and visual field deficits were present in 11 patients (73.3%) and 18 eyes (60%). In 3 patients (20%), the TSM was an incidental finding. The preoperative duration of visual deficits was less than 1 year in 9 patients, but 24, 36, and 134 months in 1 patient each. One patient (Case 10) who had bilateral visual field deficits and reduced visual acuity in the right eye preoperatively suffered from a major stroke in the middle cerebral artery (MCA) territory during surgery because of preexisting but unknown MCA stenosis and a drop of blood pressure during anesthesia. This patient died 6 years after surgery at the age of 78. A cursory examination after surgery and before discharge confirmed that he could see with both eyes, but an accurate ophthalmological examination was not possible anymore because of insufficient cooperation. Therefore, this patient was excluded from further analyses. No CSF leak or other further complication, such as seizures, pulmonary embolism, deep vein thrombosis, or pituitary dysfunction, was observed. Patient characteristics are given in Table 1.

Surgical Technique

Our surgical technique for TSM has been reported previously.³⁰ The tumors were approached via a frontolateral craniotomy in 7 cases and via a supraorbital craniotomy in 8. The frontolateral approach (4 × 4 cm) is our standard approach to anterior fossa lesions. The supraorbital approach (2 × 2.5 cm) is simply a less invasive version

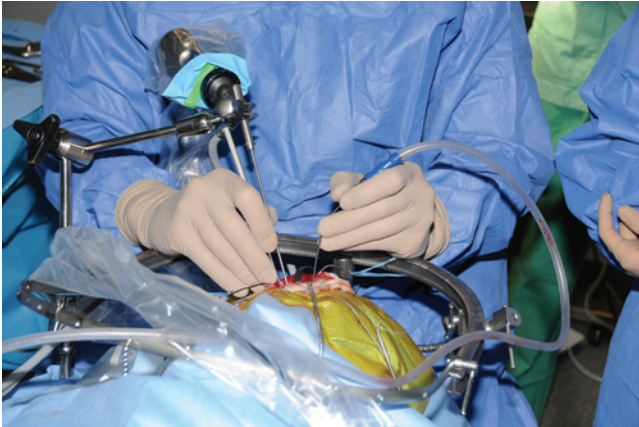


FIG. 1. Endoscope-assisted supraorbital approach. The endoscope is fixed to a mechanical holding arm to enable bimanual endoscopic dissection. Figure is available in color online only.

of the former. The most important difference is the skin incision (eyebrow versus behind the hairline). In TSM surgery we usually give the choice of the approach to the patients. In this series, the lesions were approached from the right side in all patients except one (Case 12) in whom it was approached from the left side. With proper patient positioning (body elevation 10°–15°, hyperextension of the neck, zygoma highest point) and an abundant release of CSF, the frontal lobes fall back due to gravity and only minor retraction is required during the tumor resection. Tumor growth into one or both optic canals was seen in 10 patients (66.7%). Unroofing of the ipsilateral optic canal was usually done as the first step, followed by incision of the falciform ligament and resection of the intracanalicular dura mater. After devascularization of the tumor by coagulation of the tumor base at the tuberculum and planum, the tumor is debulked. After adequate decompression of the optic apparatus has been achieved, the tumor is dissected away from the chiasm and optic nerves using a bimanual technique: the tumor is grasped with a tumor forceps and the arachnoid is peeled away from the tumor surface. Utmost care is taken to preserve the chiasm supplying vessels originating from the superior hypophyseal artery complex. Finally, the intracanalicular parts of the tumor are removed. The contralateral optic canal is unroofed as far as necessary. Since the space under the ipsilateral optic nerve is a blind corner (especially in the supraorbital approach), endoscopes are used to inspect that area. In this case series, we used 2.7-mm Hopkins II rod-lens endoscopes with an angulated eyepiece (Karl Storz GmbH & Co. KG) (Fig. 1). Endoscopes with 0°, 30°, 45°, and 70° angles of view were available. In 6 procedures, tumor tissue underneath the ipsilateral optic nerve was resected using angulated instruments under endoscopic view (Fig. 2). Without the use of the endoscopes, major manipulations of the optic apparatus would have been necessary to visualize and resect the appropriate tumor tissue. Moreover, endoscopes were used to inspect the tuberculum and the sellar diaphragm. Due to a very steep tuberculum in 1 patient, tumor remnants at the diaphragm could not be seen with the microscope. Thus, only the

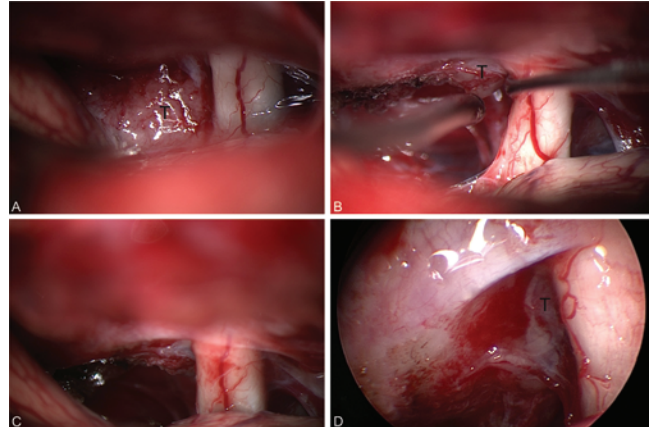


FIG. 2. Case 5. Microscopic and endoscopic images demonstrating the value of endoscope assistance during transcranial TSM surgery. The microscopic view shows the tumor (T) and the right optic nerve (A). The optic canal has not been opened since the patient had no visual disturbances and the tumor was of soft consistency. The tumor is resected under microscopic view (B). The microscopic visualization after microsurgical tumor resection shows no residual tumor (C). The endoscopic inspection with a 30° endoscope reveals residual tumor underneath the ipsilateral optic nerve without any optic nerve retraction (D). Figure is available in color online only.

endoscopic view allowed full visualization and resection of the residual tumor tissue. In 9 patients, the endoscopic view did not lead to further tumor removal but was useful to verify the extent of resection.

Postoperative Visual Outcome

The postoperative ophthalmological results presented in this paper were obtained between 3 and 6 months after surgery in 12 of 15 cases. The exceptions were Cases 1, 3, and 12. In these cases, no appropriate examinations were performed during this time period, and the presented ophthalmological results were obtained 15, 16, and 23 months after surgery, respectively. Long-term ophthalmological results from up to 110 months after surgery (mean 52.4 months) did not show any significant further changes in comparison with the presented short-term results.

Ophthalmological examination during the postoperative course revealed an improvement of visual acuity in 10 (90.9%) of 11 patients and in 18 (85.7%) of 21 eyes. (The patient who had the stroke was excluded.) Visual field deficits improved in 9 (90%) of 10 patients and 13 (81.3%) of 16 eyes. No deterioration of visual acuity or visual field was seen in any patient. The patient in Case 12 had suffered from left-sided amaurosis for 134 months, but declined surgery until the visual acuity of the right eye decreased to 0.4. Postoperatively, the visual function did not improve in this patient, but was stable. If the data from this patient with exceptionally delayed surgery after diagnosis were to be excluded, an improvement of the visual acuity and the visual field would have been seen in all patients (100%). The postoperative visual outcome per patient is given in Fig. 3.

Postoperative visual outcome was quantified by means of the modified logMAR scale for visual acuity and an

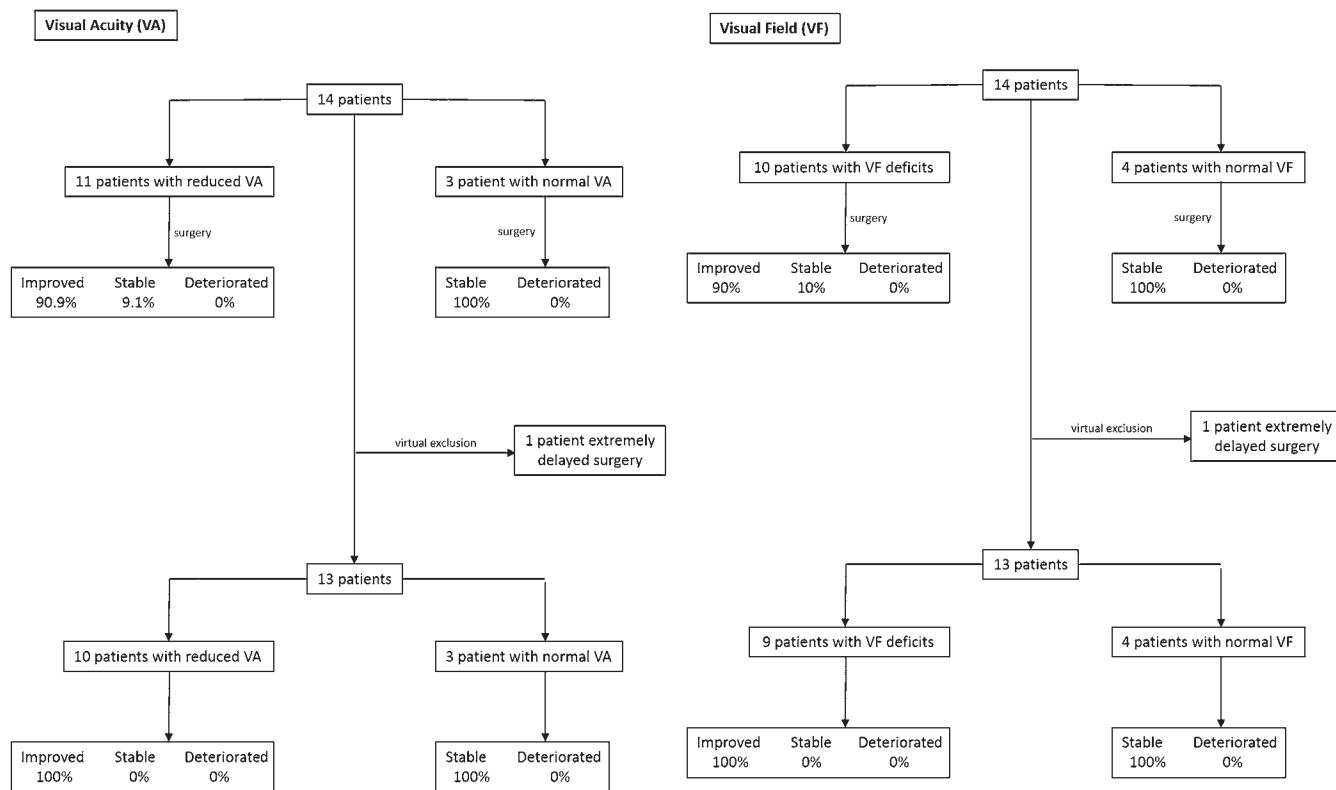


FIG. 3. Visual outcome after endoscope-assisted transcranial TSM surgery. Postoperative results (improved, stable, deteriorated) for visual acuity (VA, left) and visual field (VF, right) are shown per patient.

ordinal scale for the graduation of visual field deficits. The patient in Case 4 could not be included in this analysis, since data from comparable ophthalmological examinations from the pre- and postoperative course were not available, and the patient in Case 10 was excluded because a thorough postoperative assessment was not possible, as explained above. The median logMAR for the right eye improved from a preoperative value of 0.4 to a postoperative value of 0.1. The median logMAR for the left eye improved from a preoperative value of 0.5 to a postoperative value of 0.1. The median visual field score for the right eye improved from a preoperative value of 3 to a postoperative value of 5. The median visual field score for the left eye improved from a preoperative value of 4 to a postoperative value of 6. The logMAR and visual field score results are shown in Table 2 and Fig. 4. As examples of excellent recovery of visual field, the pre- and postoperative visual field examinations of the patients in Cases 2 and 7 are shown in Figs. 5 and 6, respectively.

Discussion

Summary of the Key Results

The present study reflects a single-center experience with endoscope-assisted transcranial TSM surgery. Functional improvement was demonstrated postoperatively in all patients with preoperative visual deficits who underwent surgery within 3 years after the onset of their visual symptoms. No postoperative deterioration of visual func-

tion was seen. Use of the endoscope allowed us to avoid major manipulation of the optic apparatus. With the exception of 1 major stroke during surgery, no complications were seen in this series. The major limitation of this study is the small number of patients.

Visual Outcome After TSM Surgery

Diminished visual function is the leading clinical sign for TSM, and a rate of 80% in the present series is in concordance with the rates reported in the literature.^{2,9,11,13,17,22,23} Gross-total resection and improvement of visual function are the major goals of surgery for TSM. There has been an evolution of microsurgical techniques leading to improved visual outcome after transcranial TSM surgery.²⁵ While series from the early 1990s reported rates of visual deterioration after TSM surgery of about 19%,¹⁴ more recent series have reported postoperative improvement or stabilization of visual function in more than 90% of patients.^{5,19,21-23} The frontolateral approach, however, seems to be superior to other transcranial approaches for TSM surgery.^{22,24}

Over approximately the past decade, the endonasal approach has been highlighted for TSM surgery by several authors,^{9,15,18} and rates for postoperative improvement of visual function have been reported in early and small series at between 66% and 100%.^{3,7,33} A recently published large series demonstrated an improvement rate of 85.7%.¹⁸ These results are comparable to those obtained in the present study. The use of endoscopes helps to minimize

TABLE 2. Quantification of preoperative and postoperative visual acuity and visual field deficits in 13 patients

Case No.	Visual Acuity (logMAR)				Visual Field Score*			
	Right Eye		Left Eye		Right Eye		Left Eye	
	Preop	Postop	Preop	Postop	Preop	Postop	Preop	Postop
1	0.22	0.1	0.3	0.1	3	5	6	6
2	2.3	0.15	1	0	0	3	4	6
3	0	0	0.5	0.3	6	6	2	3
5	0	0	0	0	6	6	6	6
6	0.5	0.2	0.5	0.2	1	5	3	6
7	0.4	0.1	1.86	0.1	1	6	1	6
8	1	0.4	0.2	0.1	3	5	6	6
9	0.2	0.1	0.5	0.1	1	5	3	5
11	1	0.3	2.7	2.7	3	5	1	1
12	0.4	0.4	3	3	3	3	0	0
13	1.4	0.1	0.7	0	1	3	6	6
14	0	0	0	0	6	6	6	6
15	0	0	0	0	6	6	6	6

The patient in Case 4 had to be excluded because no comparable ophthalmological examinations were obtainable from the pre- and postoperative course. The patient in Case 10 was excluded because postoperative testing could not be completed due to an intraoperative stroke.

* Based on ordinal scale.

manipulation of the optic apparatus and helps to preserve its vascular supply. Thus, the use of endoscopes, either in transcranial or in endonasal approaches to TSM, is likely to contribute in important ways to excellent visual outcome.

Clinical and Surgical Factors That Predict Visual Outcome After TSM Surgery

In the present series, improvement in function was documented postoperatively in every eye that could be examined except for both eyes in Case 12 and the left eye in Case 11. Independently of the surgical approach, several factors might affect the visual outcome after TSM surgery. Of these, only a few are amenable to influence by the surgeon. Intraoperatively, the left optic nerve in Case 11 was found to be parchment-like, and accordingly, postoperative recovery of its function was not expected. The

preoperative duration of symptoms is a strong predictor of visual outcome.^{20,24} Chronic compression of the optic nerve leads to diminished vascular supply and consequent demyelination.¹⁶ Even after operative decompression, recovery of the optic nerve and its function may not be possible, as seen in Case 12 in our series. Unfortunately, delay of diagnosis after the beginning of visual disturbances is often seen in patients with TSM.⁹ The results of the present study underscore the significance of the short-term visual outcome after TSM surgery.^{5,25,26} Of note, long-term ophthalmological follow-up might be biased due to the natural decrease of visual function with increasing age.

Fastidious preservation of chiasm-supplying vessels is indispensable for optimal visual outcome in TSM surgery.²⁹ Careful dissection of the arachnoid plane around the tumor with preservation of the branches of the superior hypophyseal artery complex is of the utmost importance, and it is essential to avoid coagulation close to

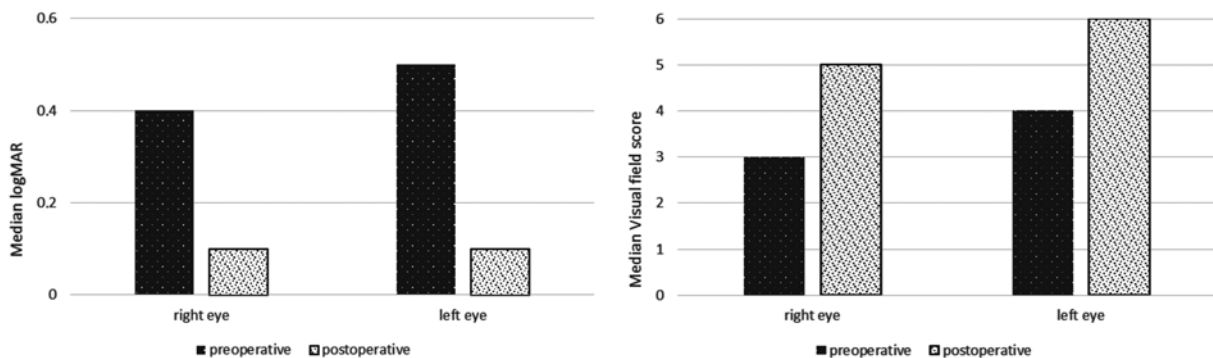


FIG. 4. Visual outcome after endoscope-assisted transcranial TSM surgery. Preoperative and postoperative results for the median logMAR (left) and median visual field score (right) are shown per eye. Case 4 had to be excluded from this analysis, because the patient's pre- and postoperative ophthalmological examinations were not comparable.

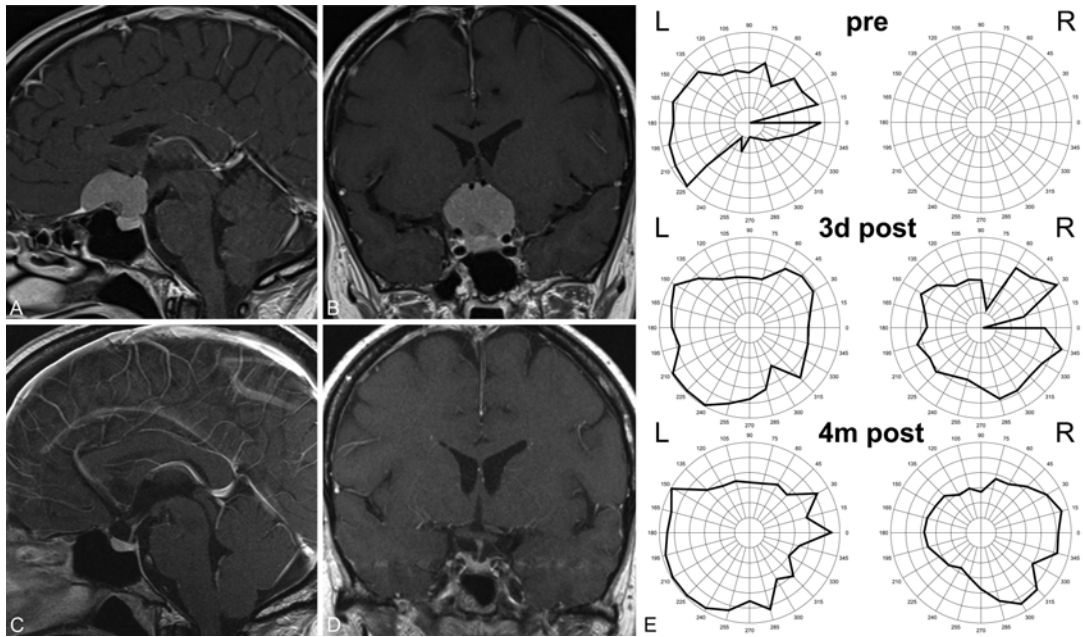


FIG. 5. Case 2. Preoperative (A and B) and postoperative (C and D) sagittal (A and C) and coronal (B and D) contrast-enhanced MR images and results of visual field testing (E) obtained in a representative case in which TSM surgery was performed via a frontolateral craniotomy with a skin incision behind the hairline. The improvement of the visual field can be seen from preoperative testing (pre) to testing performed 3 days after surgery (3d post) and 4 months after surgery (4m post).

these branches. Unfortunately, in transcranial microscopic inspection there is a blind corner underneath the ipsilateral optic nerve, requiring increased manipulation of this structure and its vascular supply if gross-total resection is warranted.^{1,13,32} With the angled view of an endoscope

(Fig. 6), however, this problem can be avoided, as shown in the present series and by others.¹¹

Unroofing of the ipsilateral optic canal and incision of the falciform ligament must usually be performed before the tumor can be addressed. This is especially important

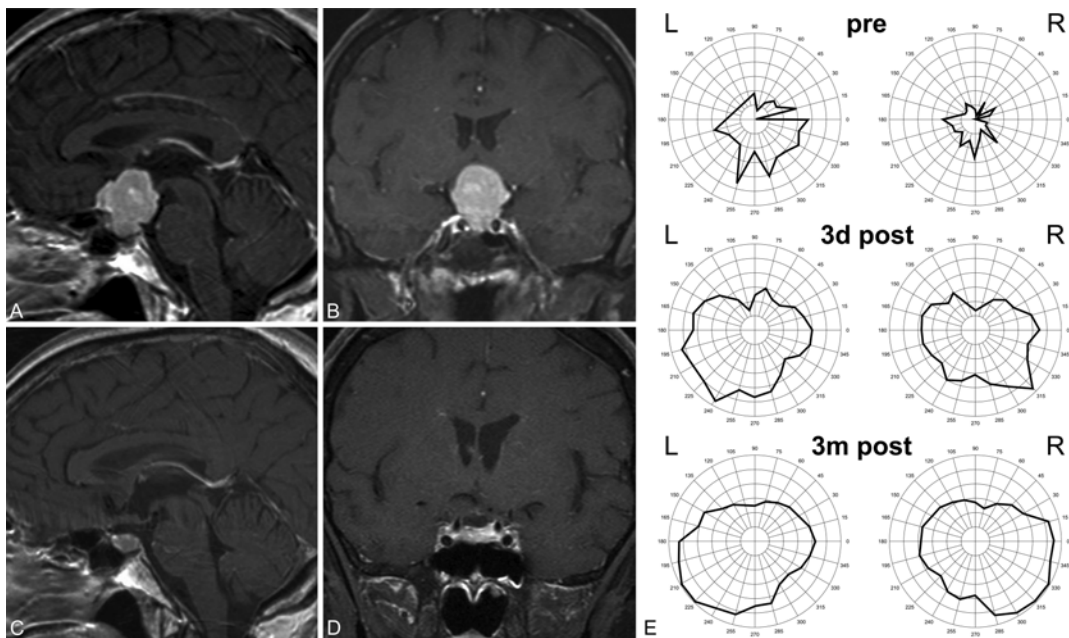


FIG. 6. Case 7. Preoperative (A and B) and postoperative (C and D) sagittal (A and C) and coronal (B and D) contrast-enhanced MR images and results of visual field testing (E) obtained in a representative case in which TSM surgery was performed via a supraorbital craniotomy with an eyebrow skin incision. The improvement of the visual field can be seen from preoperative testing (pre) to testing performed 3 days after surgery (3d post) and 4 months after surgery (4m post).

in patients who are presenting with visual loss and/or visual field deficit as well as in all cases in which the tumor is extending into the optic canal. In small and soft tumors that do not cause visual problems and do not extend into the optic canal, unroofing is not necessary. However, early decompression of the optic nerve is frequently mandatory,^{17,22,29} and unroofing of the optic canal in these patients is an independent factor for a favorable postoperative visual outcome.¹⁹ Whether the severity of preoperative visual symptoms and the tumor size influence the postoperative visual outcome is still controversial, but seems to be less relevant.^{17,23–25}

Pros and Cons of the Endoscope-Assisted Frontolateral and Supraorbital Approach in TSM Surgery

The present series confirms a low rate of CSF leaks after frontolateral or supraorbital approaches to TSM. Furthermore, no anosmia or anterior or posterior pituitary dysfunction was observed postoperatively. Compared with other transcranial approaches in TSM surgery, the frontolateral approach has the lowest rate of postoperative anosmia.⁹ Using an eyebrow or hairline skin incision, favorable cosmetic results are achievable in transcranial TSM surgery.²⁹ The patient may have a swollen eye for several days, but no special postoperative care is needed. Frontal lobe retraction is claimed to be a disadvantage in transcranial approaches to TSM.^{1,8,9,13,18,32} However, with proper patient positioning and early release of CSF, frontal lobe retraction can be kept to a minimum.

Gross-total resection is not a matter of approach,^{2,6,13,17} but of tumor characteristics. If any neurovascular structure is found to be invaded or firmly adherent, resection should be stopped so that the structure can be preserved,^{12,23,28} as done in Case 12 in the present series. Vascular injuries and perioperative strokes have been described in association with transcranial and other approaches to TSM.^{16,22}

Conclusions

The present series confirms a high gross-total resection rate, a low complication rate, and a favorable visual outcome after TSM surgery via a supraorbital or frontolateral endoscope-assisted approach. The use of the endoscope allows for less manipulation of the optic apparatus and seems to favor a good visual outcome that is comparable with outcomes reported for TSM resection via an endonasal approach.

Acknowledgments

We thank M. Matthes, MSc, for his help in preparing the illustrations.

References

- Bohman LE, Stein SC, Newman JG, Palmer JN, Adappa ND, Khan A, et al: Endoscopic versus open resection of tuberculum sellae meningiomas: a decision analysis. *ORL J Otorhinolaryngol Relat Spec* **74**:255–263, 2012
- Bowers CA, Altay T, Couldwell WT: Surgical decision-making strategies in tuberculum sellae meningioma resection. *Neurosurg Focus* **30**(5):E1, 2011
- Ceylan S, Koc K, Anik I: Extended endoscopic transphenoidal approach for tuberculum sellae meningiomas. *Acta Neurochir (Wien)* **153**:1–9, 2011
- Chi JH, McDermott MW: Tuberculum sellae meningiomas. *Neurosurg Focus* **14**(6):e6, 2003
- Chokyu I, Goto T, Ishibashi K, Nagata T, Ohata K: Bilateral subfrontal approach for tuberculum sellae meningiomas in long-term postoperative visual outcome. *J Neurosurg* **115**:802–810, 2011
- Clark AJ, Jahangiri A, Garcia RM, George JR, Sughrue ME, McDermott MW, et al: Endoscopic surgery for tuberculum sellae meningiomas: a systematic review and meta-analysis. *Neurosurg Rev* **36**:349–359, 2013
- Cook SW, Smith Z, Kelly DF: Endonasal transsphenoidal removal of tuberculum sellae meningiomas: technical note. *Neurosurgery* **55**:239–246, 2004
- Couldwell WT, Weiss MH, Rabb C, Liu JK, Apfelbaum RI, Fukushima T: Variations on the standard transsphenoidal approach to the sellar region, with emphasis on the extended approaches and parasellar approaches: surgical experience in 105 cases. *Neurosurgery* **55**:539–550, 2004
- de Divitiis E, Cavallo LM, Esposito F, Stella L, Messina A: Extended endoscopic transsphenoidal approach for tuberculum sellae meningiomas. *Neurosurgery* **61** (5 Suppl 2):229–238, 2007
- de Divitiis E, Esposito F, Cappabianca P, Cavallo LM, de Divitiis O: Tuberculum sellae meningiomas: high route or low route? A series of 51 consecutive cases. *Neurosurgery* **62**:556–563, 2008
- Fatemi N, Dusick JR, de Paiva Neto MA, Malkasian D, Kelly DF: Endonasal versus supraorbital keyhole removal of craniopharyngiomas and tuberculum sellae meningiomas. *Neurosurgery* **64** (5 Suppl 2):269–286, 2009
- Gadgil N, Thomas JG, Takashima M, Yoshor D: Endoscopic resection of tuberculum sellae meningiomas. *J Neurol Surg B Skull Base* **74**:201–210, 2013
- Gardner PA, Kassam AB, Thomas A, Snyderman CH, Carrau RL, Mintz AH, et al: Endoscopic endonasal resection of anterior cranial base meningiomas. *Neurosurgery* **63**:36–54, 2008
- Gökalp HZ, Arasil E, Kanpolat Y, Balim T: Meningiomas of the tuberculum sella. *Neurosurg Rev* **16**:111–114, 1993
- Khan OH, Krischek B, Holliman D, Klironomos G, Kucharczyk W, Vescan A, et al: Pure endoscopic expanded endonasal approach for olfactory groove and tuberculum sellae meningiomas. *J Clin Neurosci* **21**:927–933, 2014
- Kitano M, Taneda M, Nakao Y: Postoperative improvement in visual function in patients with tuberculum sellae meningiomas: results of the extended transsphenoidal and transcranial approaches. *J Neurosurg* **107**:337–346, 2007
- Komotar RJ, Starke RM, Raper DM, Anand VK, Schwartz TH: Endoscopic endonasal versus open transcranial resection of anterior midline skull base meningiomas. *World Neurosurg* **77**:713–724, 2012
- Koutourousiou M, Fernandez-Miranda JC, Steffko ST, Wang EW, Snyderman CH, Gardner PA: Endoscopic endonasal surgery for suprasellar meningiomas: experience with 75 patients. *J Neurosurg* **120**:1326–1339, 2014
- Landeiro JA, Gonçalves MB, Guimarães RD, Klescoski J, Correa JL, Lapenta MA, et al: Tuberculum sellae meningiomas: surgical considerations. *Arq Neuropsiquiatr* **68**:424–429, 2010
- Leu CH, Hu TL, Shen CC, Wang YC: Tuberculum sellae meningiomas: clinical manifestation, radiologic diagnosis, surgery and visual outcome. *Zhonghua Yi Xue Za Zhi (Taipei)* **61**:1–7, 1998
- Li-Hua C, Ling C, Li-Xu L: Microsurgical management of tuberculum sellae meningiomas by the frontolateral approach: surgical technique and visual outcome. *Clin Neurol Neurosurg* **113**:39–47, 2011

22. Mahmoud M, Nader R, Al-Mefty O: Optic canal involvement in tuberculum sellae meningiomas: influence on approach, recurrence, and visual recovery. **Neurosurgery** **67** (3 Suppl **Operative**):ons108–ons119, 2010
23. Margalit N, Shahar T, Barkay G, Gonen L, Nossek E, Rozovski U, et al: Tuberculum sellae meningiomas: surgical technique, visual outcome, and prognostic factors in 51 cases. **J Neurol Surg B Skull Base** **74**:247–258, 2013
24. Nakamura M, Roser F, Struck M, Vorkapic P, Samii M: Tuberculum sellae meningiomas: clinical outcome considering different surgical approaches. **Neurosurgery** **59**:1019–1029, 2006
25. Palani A, Panigrahi MK, Purohit AK: Tuberculum sellae meningiomas: A series of 41 cases; surgical and ophthalmological outcomes with proposal of a new prognostic scoring system. **J Neurosci Rural Pract** **3**:286–293, 2012
26. Park CK, Jung HW, Yang SY, Seol HJ, Paek SH, Kim DG: Surgically treated tuberculum sellae and diaphragm sellae meningiomas: the importance of short-term visual outcome. **Neurosurgery** **59**:238–243, 2006
27. Raco A, Bristot R, Domenicucci M, Cantore G: Meningiomas of the tuberculum sellae. Our experience in 69 cases surgically treated between 1973 and 1993. **J Neurosurg Sci** **43**:253–262, 1999
28. Romani R, Laakso A, Kangasniemi M, Niemelä M, Hernesniemi J: Lateral supraorbital approach applied to tuberculum sellae meningiomas: experience with 52 consecutive patients. **Neurosurgery** **70**:1504–1519, 2012
29. Schroeder HWS: Indications and limitations of the endoscopic endonasal approach for anterior cranial base meningiomas. **World Neurosurg** **82** (6 Suppl):S81–S85, 2014
30. Schroeder HWS: Supraorbital approach, in Cappabianca P, Cavallo LM, de Divitis O, et al (eds): **Midline Skull Base Surgery**. Cham: Springer, 2016, pp 253–268
31. Schulze-Bonsel K, Feltgen N, Burau H, Hansen L, Bach M: Visual acuities “hand motion” and “counting fingers” can be quantified with the freiburg visual acuity test. **Invest Ophthalmol Vis Sci** **47**:1236–1240, 2006
32. Soni RS, Patel SK, Husain Q, Dahodwala MQ, Eloy JA, Liu JK: From above or below: the controversy and historical evolution of tuberculum sellae meningioma resection from open to endoscopic skull base approaches. **J Clin Neurosci** **21**:559–568, 2014
33. Wang Q, Lu XJ, Ji WY, Yan ZC, Xu J, Ding YS, et al: Visual outcome after extended endoscopic endonasal transsphenoidal surgery for tuberculum sellae meningiomas. **World Neurosurg** **73**:694–700, 2010
34. Yamashita J, Handa H, Iwaki K, Abe M: Recurrence of intracranial meningiomas, with special reference to radiotherapy. **Surg Neurol** **14**:33–40, 1980

Disclosures

Dr. Schroeder reports a consultant relationship with Karl Storz GmbH & Co. KG.

Author Contributions

Conception and design: Marx, Schroeder. Acquisition of data: Marx. Analysis and interpretation of data: Marx, Schroeder. Drafting the article: Marx, Schroeder. Critically revising the article: all authors. Reviewed submitted version of manuscript: all authors. Approved the final version of the manuscript on behalf of all authors: Marx. Administrative/technical/material support: all authors. Study supervision: Clemens, Schroeder.

Correspondence

Sascha Marx, Department of Neurosurgery, University Medicine Greifswald, Sauerbruchstraße, Greifswald 17475, Germany. email: marxs@uni-greifswald.de.