

## Surgical and Radiation Treatment of Skull Base Meningiomas

a report by

**Chad D Cole, MD, MSc and William T Couldwell, MD, PhD**

*Department of Neurosurgery, University of Utah, Salt Lake City*

Meningiomas comprise approximately 20% of adult primary intracranial neoplasms.<sup>1</sup> Of these, benign meningiomas are known to have an indolent growth pattern, usually without infiltration into adjacent nervous tissue.<sup>2-5</sup> Because meningiomas have a well-circumscribed character, surgery has historically been the preferred treatment when total resection can be achieved with reasonable morbidity. Surgical resection has resulted in five-, 10-, and 15-year progression-free rates of 93, 80, and 68%, respectively.<sup>6</sup> Despite the development of multiple techniques designed to minimize morbidity while obtaining a surgical cure, however, complete resection remains difficult and is not achievable in approximately 20–30% of presenting patients because of multiple regional involvement, severe adherence to or invasion of the brainstem, involvement of cranial nerves, or encasement of the vertebrobasilar circulation.<sup>6-11</sup> Currently, controversy exists as to whether skull base meningiomas, especially those involving the petroclivus and/or cavernous sinus, are best treated with radical resection, subtotal resection followed by radiosurgical treatment of the residual lesion, or radiosurgical treatment alone.

### Petroclival Tumors and Cavernous Extension

Meningiomas of the petroclival region usually involve the petrous apex and the upper two-thirds of the clivus.<sup>10</sup> Most are complex and, with modest enlargement, may involve multiple regions. Clival extension is usually unilateral for those tumors involving the upper and midclival regions.<sup>10</sup> However, additional complexity exists for those centrally located lesions with respect to the clivus that have bilateral cavernous sinus involvement and/or extradural extension into the sphenoid sinus.<sup>10</sup>

Petroclival meningiomas are among the most difficult tumors of the cranial base for which to obtain surgical cure. Therefore, treatment must take into account the natural history of the tumor, degree of extension, neurovascular involvement, and the patient's level of disability.<sup>12,13</sup> Despite significant improvements<sup>10,14-17</sup> in the surgical treatment of petroclival meningiomas, tumor may be left behind because of the invasion of the cavernous sinus, encroachment or encasement of cranial nerves, involvement of cerebral arteries, or invasion of the brainstem pial membrane. On this note, the management of tumors with neurovascular involvement has changed considerably over the past few years. Appropriately, cautious subtotal resection has become the preferred treatment to reduce post-operative morbidity, along with the addition of radiation treatment of tumor remnants.<sup>18-21</sup>

Meningiomas along the medial sphenoid wing that invade the cavernous sinus are also a treatment challenge because of the possibility of tumor

infiltration of the traversing cranial nerves and internal carotid artery and, to a lesser degree, the involvement of the adjacent pituitary gland.<sup>22</sup> The goal of surgical cure must therefore take into account local invasion of neurovascular structures within the cavernous sinus. As a consequence, several authors have emphasized the use of subtotal resection to limit the risk for permanent post-operative cranial nerve or the potential for vascular injury over complete resection.<sup>7,9,12,23</sup> The long-term outcome after subtotal resection of meningiomas within the cavernous sinus alone is, however, associated with an unacceptably high symptomatic recurrence rate.<sup>24</sup>

### Radiosurgical Treatment

Despite the high symptomatic recurrence rate and microsurgical improvements over the past few years, subtotal resection of meningiomas along the skull base, particularly those within the petroclival and cavernous sinus locations, remains a desired surgical outcome because such limited resection lends an acceptable level of morbidity.<sup>7,11,25-27</sup> Because of the unacceptable morbidity of radical resection, along with the high incidence of recurrence, adjuvant techniques for treating these tumors have been developed.

Early studies from the 1980s demonstrated that external-beam field radiation therapy could provide durable local tumor control for those benign meningiomas treated with subtotal resection through improved progression-free survival rates.<sup>28-30</sup> As more conformal therapies were developed, higher radiation doses could be administered while sparing dose to surrounding neural structures, resulting in an additional

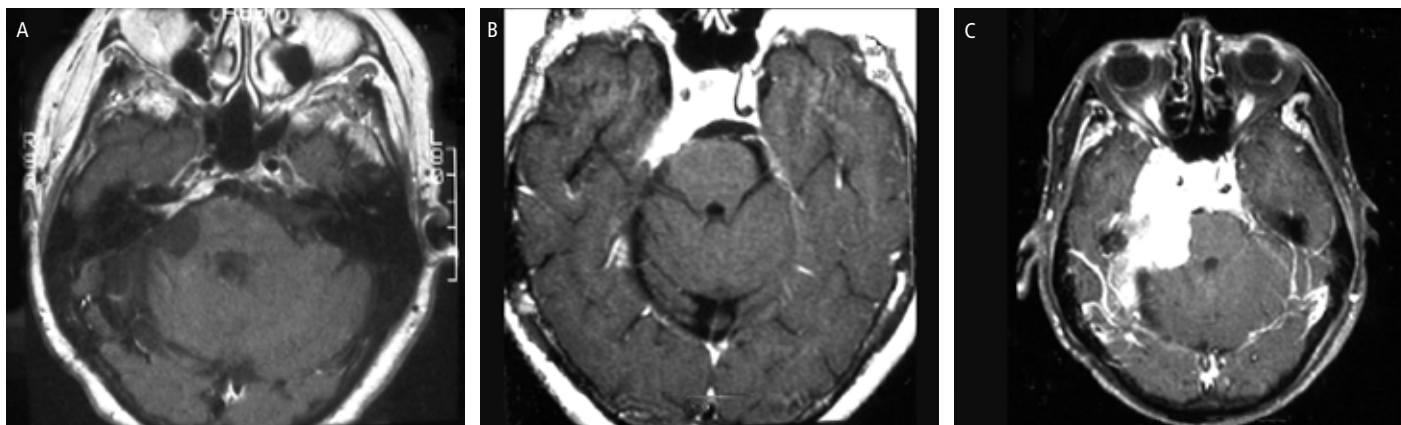
Chad D Cole, MD, MSc, is in his fourth year of residency training in neurosurgery in the Department of Neurosurgery at the University of Utah, Salt Lake City. He has published 30 peer-reviewed articles. Dr Cole obtained his MD at the University of Utah and his MSc at Brigham Young University.



William T Couldwell, MD, PhD, is a Professor and Chairman of the Department of Neurosurgery at the University of Utah, positions he has held since 2001. He is a member of the Board of Directors of the American Association of Neurological Surgeons (AANS) and is a Director of the American Board of Neurosurgery. He serves on the Editorial Board of several journals and is Chairman of the Editorial Board of the *Journal of Neurosurgery*. Professor Couldwell received his MD and PhD from McGill University. He subsequently undertook residency training in neurosurgery at the University of Southern California.

E: [neuropub@hsc.utah.edu](mailto:neuropub@hsc.utah.edu)

**Figure 1: Magnetic Resonance Images Obtained in a 56-year-old Woman Who Had Undergone Resection of a Right Sphenopetroclival Meningioma, Revealing Tumor Progression**



A: Ten years later, a follow-up image showed a small tumor recurrence, medial and superior to the internal auditory canal, which was treated with gamma knife therapy. B: The lesion remained stable for eight years, at which time the patient experienced paresthesia on the right side of her face, right-sided facial spasms and progressive ataxia. C: A follow-up image obtained two years later demonstrated tumor progression.

Figure reproduced from Couldwell et al., 2007.<sup>43</sup>

improvement in the 10-year progression-free survival rate. In a more recent study, Mendenhall et al.<sup>31</sup> have shown five-, 10-, and 15-year local control rates of 95, 92, and 92%, respectively, for meningiomas treated with radiation therapy subsequent to subtotal resection.

With the addition of 3D treatment planning, improvements in conformality have come about through the use of stereotactic radiosurgery (SRS) (single conformal treatment) and stereotactic radiotherapy (SRT) (fractionated

Radiation therapy has gained wide acceptance in the treatment of incompletely resected meningiomas, as well as a primary treatment option for inoperable tumors.

conformal treatments).<sup>32</sup> SRS is useful in the treatment of meningiomas at locations in which surgery may cause damage to neurovascular structures, especially those involving the petroclivus region and cavernous sinus.<sup>32</sup> Fractionated SRT is more useful for those tumors that arise near critical structures such as the brainstem or optic chiasm.<sup>32</sup> The use of highly focused single-fraction radiation to irregular tumor volumes, along with steep dose gradients in radiosurgery, significantly protects adjacent critical structures from delayed radiation-induced injury.

SRS has become a popular alternative or adjuvant to resection in order to reduce the risk for tumor recurrence of skull base meningiomas.<sup>25,33-35</sup> The efficacy of this method is clearly demonstrated by radiosurgical control rates, which have been reported to be extremely high: approaching or exceeding 90% in many contemporary studies involving either linear accelerator-based systems or gamma knife surgery (GKS).<sup>2,3,25,31,36-41</sup> The efficacy of stereotactic radiosurgery as an alternative to aggressive resection was confirmed in a recent study published by Davidson et al.<sup>42</sup>

They found that for those patients treated with GKS with an initial subtotal resection or with recurrent disease, the five- and 10-year actuarial progression-free survival rate was 100 and 94%, respectively.<sup>42</sup> They state that the progression-free survival rate might have been 100% had a single patient had her tumor growth area more adequately covered by the treatment plan.

Many have also considered radiosurgery to be an excellent stand-alone treatment of skull base meningiomas of less than 3cm. The caveat of such notable outcomes appears to be associated with the histological subtypes of the tumors. Stafford et al.<sup>5</sup> found that the five-year local control rate of meningiomas treated radiosurgically either primarily or subsequent to surgical treatment was 93, 68, and 0% in patients with benign, atypical, and malignant subtypes, respectively. Furthermore, the five-year cause-specific survival rate in patients with benign meningiomas was 100% compared with 83% in patients with atypical meningiomas and 0% in patients with a malignant meningioma after radiosurgery. Despite reports documenting outstanding radiosurgical growth control rates (as an alternative to or part of a staged therapy with microsurgery), radiosurgical treatment fails in some cases, and little is known about the natural history of tumors that fail to stabilize after radiosurgery. There is very scant literature on the growth patterns of such tumors.<sup>43</sup> Couldwell et al.<sup>43</sup> have reported that aggressive regrowth of meningiomas can follow failed radiosurgery, even in a substantially delayed fashion (see *Figure 1*). In several patients, meningiomas recurred several years after radiosurgical treatment (up to 14 years), indicating that consistent and extended follow-up evaluations should be performed in all cases of meningiomas, even benign meningiomas, after radiosurgery. Given this late regrowth potential, there is the distinct possibility of an increasing rate of treatment failure over time after radiosurgery.<sup>43</sup> In this analysis of failed radiosurgically treated meningiomas, tumor regrowth occurred both within and beyond the field of treatment.<sup>43</sup>

### Conclusion

Gross total resection remains the preferred treatment for benign meningiomas that can be resected with reasonable morbidity and for

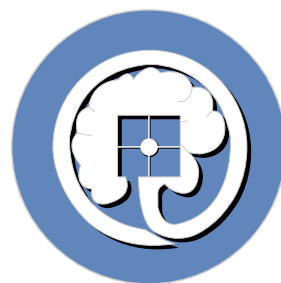
*American Society for*

# *Stereotactic and Functional Neurosurgery*



The mission of the American Society of Stereotactic and Functional Neurosurgery is to foster the use of stereotactic and functional neurological methods for the treatment of diseases of the nervous system. Our goal is to advance stereotactic and functional neurosurgery and related sciences, to improve patient care, to support meaningful basic and clinical research, to provide leadership in undergraduate and graduate education and continuing education, and to provide administrative facilities necessary to meet these goals. Further, the Society will provide a forum for the review of the basic form and function of the human nervous system in order to improve stereotactic and/or functional neurosurgical procedures that alleviate human disease and suffering through diagnosis or treatment of the function of the nervous system. We will also establish standards for the performance of stereotactic surgery through the meeting relevant to stereotactic and functional neurosurgery.

*Please visit us at <http://assfn.org>*



patients requiring immediate decompression for symptomatic relief. However, preliminary (10-year) results of radiosurgical treatment of small meningioma remnants or small inoperable tumors have influenced the management of these tumors. Radiation therapy has gained wide acceptance in the treatment of incompletely resected meningiomas, as well as a primary treatment option for inoperable tumors. Furthermore, SRS is a convenient single-day alternative to surgery for meningiomas located along the skull base, particularly those along the petroclival region or within the cavernous sinus, where attempted resection may place critical neurovascular structures at risk.

Although there are reports of long-term progression-free survival, radiation treatment of meningiomas fails in some cases. With the increasing number of patients undergoing SRS for benign tumors, careful attention is warranted, as some lesions will progress despite 'adequate' treatment. Therefore, extended (exceeding 10 years) follow-up deserves consideration in all patients after radiosurgery. ■

### Acknowledgments

We thank Kristin Kraus, MSc, for editorial assistance in preparing this paper.

## Editor's Recommendation

### Natural History of Meningioma Development in Mice Reveals: A Synergy of Nf2 and p16<sup>Ink4a</sup> Mutations

Kalamirides M, et al., *Brain Pathol*, 2008;18(1):62–70.

Reported in a previous paper, the authors inactivated Nf2 in homozygous conditional knockout mice by adenoviral Cre delivery and demonstrated that Nf2 loss in arachnoid cells is rate-limiting for meningioma formation. In this paper, it is reported that additional nullizygosity for p16<sup>Ink4a</sup> increases the frequency of meningioma and meningotheial proliferation in these mice without modifying the tumor grade. Also, through screening of a large cohort of mutant mice through magnetic resonance imaging, the authors were able to detect meningotheial proliferation and meningioma development. It is hoped that these findings will provoke future studies in which therapeutic interventions can be tested as pre-clinical assessment of their potential clinical application. ■

- Whittle IR, Smith C, Navoo P, et al., Meningiomas, *Lancet*, 2004;363:1535–43.
- Iwai Y, Yamanaka K, Ishiguro T, Gamma knife radiosurgery for the treatment of cavernous sinus meningiomas, *Neurosurgery*, 2003;52:517–24, discussion 523–4.
- Kondziolka D, Flickinger JC, Perez B, Judicious resection and/or radiosurgery for parasagittal meningiomas: outcomes from a multicenter review. Gamma Knife Meningioma Study Group, *Neurosurgery*, 1998;43:405–13, discussion 413–14.
- Shin M, Kurita H, Sasaki T, et al., Analysis of treatment outcome after stereotactic radiosurgery for cavernous sinus meningiomas, *J Neurosurg*, 2001;95:435–9.
- Stafford SL, Pollock BE, Foote RL, et al., Meningioma radiosurgery: tumor control, outcomes, and complications among 190 consecutive patients, *Neurosurgery*, 2001;49:1029–37, discussion 1037–8.
- Mirimanoff RO, Dosoretz DE, Linggood RM, et al., Meningioma: analysis of recurrence and progression following neurosurgical resection, *J Neurosurg*, 1985;62:18–24.
- DeMonte F, Smith HK, al-Mefty O, Outcome of aggressive removal of cavernous sinus meningiomas, *J Neurosurg*, 1994;81:245–51.
- Stafford SL, Perry A, Suman VJ, et al., Primarily resected meningiomas: outcome and prognostic factors in 581 Mayo Clinic patients, 1978 through 1988, *Mayo Clin Proc*, 1998;73:936–42.
- De Jesus O, Sekhar LN, Parikh HK, et al., Long-term follow-up of patients with meningiomas involving the cavernous sinus: recurrence, progression, and quality of life, *Neurosurgery*, 1996;39:915–19, discussion 919–20.
- Natarajan SK, Sekhar LN, Schessel D, et al., Petroclival meningiomas: multimodality treatment and outcomes at long-term follow-up, *Neurosurgery*, 2007;60:965–79, discussion 979–81.
- O'Sullivan MG, van Loveren HR, Tew Jr JM, The surgical resectability of meningiomas of the cavernous sinus, *Neurosurgery*, 1997;40:238–44, discussion 245–7.
- Sekhar LN, Swamy NK, Jaiswal V, et al., Surgical excision of meningiomas involving the clivus: preoperative and intraoperative features as predictors of postoperative functional deterioration, *J Neurosurg*, 1994;81:860–68.
- Jung HW, Yoo H, Paek SH, et al., Long-term outcome and growth rate of subtotally resected petroclival meningiomas: experience with 38 cases, *Neurosurgery*, 2000;46:567–74, discussion 574–5.
- Russell JR, Bucy PC, Meningiomas of the posterior fossa, *Surg Gynecol Obstet*, 1953;96:183–92.
- Couldwell WT, Fukushima T, Giannotta SL, et al., Petroclival meningiomas: surgical experience in 109 cases, *J Neurosurg*, 1996;84:20–28.
- Mayberg MR, Symon L, Meningiomas of the clivus and apical petrous bone. Report of 35 cases, *J Neurosurg*, 1986;65:160–67.
- Samii M, Ammirati M, Mahran A, et al., Surgery of petroclival meningiomas: report of 24 cases, *Neurosurgery*, 1989;24:12–17.
- Nicolato A, Foroni R, Pellegrino M, et al., Gamma knife radiosurgery in meningiomas of the posterior fossa. Experience with 62 treated lesions, *Minim Invasive Neurosurg*, 2001;44:211–17.
- Dufour H, Muracciole X, Metellus P, et al., Long-term tumor control and functional outcome in patients with cavernous sinus meningiomas treated by radiotherapy with or without previous surgery: is there an alternative to aggressive tumor removal?, *Neurosurgery*, 2001;48:285–94, discussion 294–6.
- George B, Ferrario CA, Blanquet A, et al., Cavernous sinus exenteration for invasive cranial base tumors, *Neurosurgery*, 2003;52:772–80, discussion 780–82.
- Pamir MN, Kilic T, Bayrakli F, et al., Changing treatment strategy of cavernous sinus meningiomas: experience of a single institution, *Surg Neurol*, 2005;64(Suppl. 2):S58–66.
- Sen C, Hague K, Meningiomas involving the cavernous sinus: histological factors affecting the degree of resection, *J Neurosurg*, 1997;87:535–43.
- Ringel F, Cedzich C, Schramm J, Microsurgical technique and results of a series of 63 sphenoidal meningiomas, *Neurosurgery*, 2007;60:214–21, discussion 221–2.
- Mathiesen T, Lindquist C, Kihlstrom L, et al., Recurrence of cranial base meningiomas, *Neurosurgery*, 1996;39:2–7, discussion 8–9.
- Aichholzer M, Bertalanffy A, Dietrich W, et al., Gamma knife radiosurgery of skull base meningiomas, *Acta Neurochir (Wien)*, 2000;142:647–52, discussion 652–3.
- Kotapka MJ, Kalia KK, Martinez AJ, et al., Infiltration of the carotid artery by cavernous sinus meningioma, *J Neurosurg*, 1994;81:252–5.
- Levine ZT, Buchanan RI, Sekhar LN, et al., Proposed grading system to predict the extent of resection and outcomes for cranial base meningiomas, *Neurosurgery*, 1999;45:221–30.
- Barbaro NM, Gutin PH, Wilson CB, et al., Radiation therapy in the treatment of partially resected meningiomas, *Neurosurgery*, 1987;20:525–8.
- Miralbell R, Linggood RM, de la Monte S, et al., The role of radiotherapy in the treatment of subtotally resected benign meningiomas, *J Neurooncol*, 1992;13:157–64.
- Taylor Jr BW, Marcus Jr RB, Friedman WA, et al., The meningioma controversy: postoperative radiation therapy, *Int J Radiat Oncol Biol Phys*, 1988;15:299–304.
- Mendenhall WM, Morris CG, Amdur RJ, et al., Radiotherapy alone or after subtotal resection for benign skull base meningiomas, *Cancer*, 2003;98:1473–82.
- Elia AE, Shih HA, Loeffler JS. Stereotactic radiation treatment for benign meningiomas, *Neurosurg Focus*, 2007;23:4:E5.
- Lunsford LD, Contemporary management of meningiomas: radiation therapy as an adjuvant and radiosurgery as an alternative to surgical removal?, *J Neurosurg*, 1994;80:187–90.
- Duma CM, Lunsford LD, Kondziolka D, et al., Stereotactic radiosurgery of cavernous sinus meningiomas as an addition or alternative to microsurgery, *Neurosurgery*, 1993;32:699–704, discussion 704–5.
- Maruyama K, Shin M, Kurita H, et al., Proposed treatment strategy for cavernous sinus meningiomas: a prospective study, *Neurosurgery*, 2004;55:1068–75.
- Hakim R, Alexander 3rd E, Loeffler JS, et al., Results of linear accelerator-based radiosurgery for intracranial meningiomas, *Neurosurgery*, 1998;42:446–53, discussion 453–4.
- Ide M, Yamamoto M, Hagiwara S, et al., Rapid regrowth of intracranial clear cell meningioma after craniotomy and gamma knife radiosurgery: case report, *Neuro Med Chir (Tokyo)*, 2004;44:321–5.
- Kawashima M, Suzuki SO, Ikezaki K, et al., Different responses of benign and atypical meningiomas to gamma-knife radiosurgery: report of two cases with immunohistochemical analysis, *Brain Tumor Pathol*, 2001;18:61–6.
- Marosi C, Hassler M, Rossler K. Guidelines to the treatment of meningioma, *Forum (Genova)*, 2003;13:76–89.
- Muthukumar N, Kondziolka D, Lunsford LD, et al., Stereotactic radiosurgery for tentorial meningiomas, *Acta Neurochir (Wien)*, 1998;140:315–20, discussion 320–21.
- Pollock BE, Stafford SL, Link MJ. Gamma knife radiosurgery for skull base meningiomas, *Neurosurg Clin N Am*, 2000;11:659–66.
- Davidson L, Fishback D, Russin JJ, et al., Postoperative gamma knife surgery for benign meningiomas of the cranial base, *Neurosurg Focus*, 2007;23:4:E6.
- Couldwell WT, Cole CD, Al-Mefty O. Patterns of skull base meningioma progression after failed radiosurgery, *J Neurosurg*, 2007;106:30–35.