

# **Guidelines for Diagnosis and Treatment of Moyamoya Disease (Spontaneous Occlusion of the Circle of Willis)**

Research Committee on the Pathology and Treatment of Spontaneous Occlusion of the Circle of Willis; Health Labour Sciences Research Grant for Research on Measures for Intractable Diseases

## **CHAPTER I: CONCEPTS OF THE DISEASE**

### **Concepts of the Disease**

The characteristics of moyamoya disease (spontaneous occlusion of the circle of Willis, cerebrovascular “moyamoya” disease) on cerebral angiography were reported for the first time in 1957,<sup>8)</sup> and the concept of moyamoya disease as a separate disease entity was established in the 1960s.<sup>1-3,6,7)</sup> Pathologically, moyamoya disease is characterized by chronic progressive stenosis of the terminal portion of the bilateral internal carotid arteries, which leads to the formation of an abnormal vascular network composed of collateral pathways at the base of the brain (moyamoya vessels at the base of the brain) (‘moyamoya’ is the Japanese term for a “puff of smoke,” which has been used to describe the appearance of these collateral vessels on cerebral angiograms<sup>6)</sup>). Eventually, with bilateral internal carotid artery occlusion, the moyamoya vessels at the base of the brain derived from the internal carotid arteries disappear, and the entire brain is perfused by the external carotid artery system and the vertebralbasilar artery system.<sup>1-3,5-7)</sup> This disease is included in the list of diseases for Research on Measures for Intractable Diseases and the Specified Disease Treatment Research Program specified by the Ministry of Health, Labour and Welfare. Currently, the diagnostic criteria for moyamoya disease (spontaneous occlusion of the circle of Willis) laid down by the research committee are as follows.<sup>4)</sup>

### **Diagnostic Criteria<sup>3)</sup>**

- (1) Cerebral angiography is considered essential for the diagnosis, and must show at least the following findings:
  - (i) Stenosis or occlusion of the terminal portion of the intracranial internal carotid artery or proximal portions of the anterior and/or the middle cerebral artery.
  - (ii) Abnormal vascular networks in the vicinity of the occlusive or stenotic lesions in the arterial phase.
  - (iii) Bilaterality of findings (i) and (ii).
- (2) However, when magnetic resonance imaging (MRI) and magnetic resonance angiographic (MRA) findings meet all of the following criteria, cerebral angiography can be omitted. See the “Guidelines for Diagnostic Imaging by MRI and MRA.”
  - (i) MRA shows stenosis or occlusion of the terminal portion of the intracranial internal carotid artery or proximal portions of the anterior and/or the middle cerebral artery.
  - (ii) MRA shows abnormal vascular networks in the basal ganglia.  
Note: When 2 or more visible flow voids are present in the basal ganglia on MRI, at least unilaterally, they can be deemed as representing an abnormal vascular network.
  - (iii) Bilaterality of findings (i) and (ii).
- (3) Moyamoya disease is an illness of unknown etiology. The differential diagnosis of this disease includes similar cerebrovascular lesions associated with the following underlying diseases, which should, therefore, be excluded: (i) atherosclerosis, (ii) autoimmune disease, (iii) meningitis, (iv) brain tumors, (v) Down’s syndrome, (vi) von Recklinghausen’s disease, (vii) head injury, (viii) cerebrovascular lesions after head irradiation, and (ix) others.
- (4) Pathological findings that can be used as references for the diagnosis
  - (i) Thickening of the arterial intima, mainly in the terminal portion of the internal carotid arteries, and narrowing or blockage of the lumen caused by this change, usually bilateral. Occasionally, lipid deposits are also present in the thickened intima.
  - (ii) Arteries such as the anterior, middle, and

posterior cerebral arteries forming the circle of Willis occasionally show varying degrees of stenosis or occlusion associated with fibrocellular thickening of the intima, waviness of the internal elastic lamina, and thinning of the media.

- (iii) Numerous small vascular channels (perforating and anastomotic branches) can be seen around the circle of Willis.
- (iv) Pia mater may also show reticular conglomerates of small vessels.

### Diagnostic Assessment

Moyamoya disease should be classified as definitive or probable based on the above-mentioned items (1) to (4). When autopsy is performed in the absence of cerebral angiography, the condition should be diagnosed based on the criteria in item (4).

**Definitive moyamoya disease:** All criteria listed in (1) or (2) and in (3) should be met. In children, however, the criteria in item (1) or (2) (i) and (ii) on one side, and visible stenosis around the terminal portion of the internal carotid arteries on the other side are sufficient for a definitive diagnosis.

**Probable moyamoya disease:** All criteria are fulfilled except item (1) (iii) and/or item (2) (iii) among the criteria of (1) or (2) and (3).

## CHAPTER II: EPIDEMIOLOGY

Moyamoya disease (spontaneous occlusion of the circle of Willis) is a disease that occurs frequently in Asian countries, including Japan, but is rare in Western countries. Epidemiological data reported from Japan are extremely valuable worldwide.

Early epidemiological surveys in Japan include an evaluation in 376 patients performed by Kudo<sup>5)</sup> in the early 1970s and an evaluation in 518 patients conducted by Mizukawa et al.<sup>6)</sup> Thereafter, a research committee on spontaneous occlusion of the circle of Willis was established in 1977. Since 1983, case registration and follow-up investigation have been carried out each year at medical institutions to which the committee members belong and their related facilities throughout Japan. As of 2006, there were a total of 962 patients, including 785 with a definitive diagnosis of moyamoya disease, 60 with a probable diagnosis, and 62 with quasi-moyamoya disease, registered in the database of this research committee on spontaneous occlusion of the circle of Willis.<sup>7)</sup>

In addition to accumulation of cases in the database at the committee members' institutions, three

### References

- 1) Kudo T: [Occlusion of the internal carotid artery and the type of recovery of cerebral blood circulation]. *Rinsho Shinkeigaku* 1: 199-200, 1960 (Japanese)
- 2) Kudo T: Spontaneous occlusion of the circle of Willis. A disease apparently confined to Japanese. *Neurology* 18: 485-496, 1968
- 3) Nishimoto A, Takeuchi S: Abnormal cerebrovascular network related to the internal carotid arteries. *J Neurosurg* 29: 255-260, 1968
- 4) Research Committee on Spontaneous Occlusion of the Circle of Willis (Moyamoya Disease): [Research on Specified Diseases of the Ministry of Health, Labour and Welfare 1998 Research Report: Latest Diagnostic and Treatment Guidelines]. 1998 (Japanese)
- 5) Suzuki J, Kodama N: Cerebrovascular "Moyamoya" disease. 2. Collateral routes to forebrain via ethmoid sinus and superior nasal meatus. *Angiology* 2: 223-236, 1971
- 6) Suzuki J, Takaku A: Cerebrovascular "moyamoya" disease. Disease showing abnormal net-like vessels in base of brain. *Arch Neurol* 20: 288-299, 1969
- 7) Suzuki J, Takaku A, Asahi M, Kowada M: [Examination of disease groups showing abnormal reticular vascular images at the base of the brain that frequently occur in Japanese people]. *No To Shinkei* 17: 767-776, 1965 (Japanese)
- 8) Takeuchi K, Shimizu K: [Hypogenesis of bilateral internal carotid arteries]. *No To Shinkei* 9: 37-43, 1957 (Japanese)

large-scale national epidemiological surveys were conducted in 1984, 1990, and 1994.

### Number of Patients and Male-to-Female Ratio

In a national epidemiological survey conducted by Wakai et al.<sup>8)</sup> in 1994, approximately 3,900 people were estimated to be suffering from moyamoya disease (To be more precise, this was the number of patients examined). Moyamoya disease affects 3.16 people per 100,000 persons, and occurs at an incidence of 0.35 people per 100,000 population. According to the "number of patients having a certificate for medical care for specified (intractable) disease: Occlusive disease in circle of Willis," the number of patients with moyamoya disease markedly increased from 5,227 patients in 1994 to 10,812 patients in 2005. If a national survey were conducted again now, it is expected that the number of patients would have grown further from that in 1994. This may be attributable to the spreading awareness of and familiarity with the concepts of

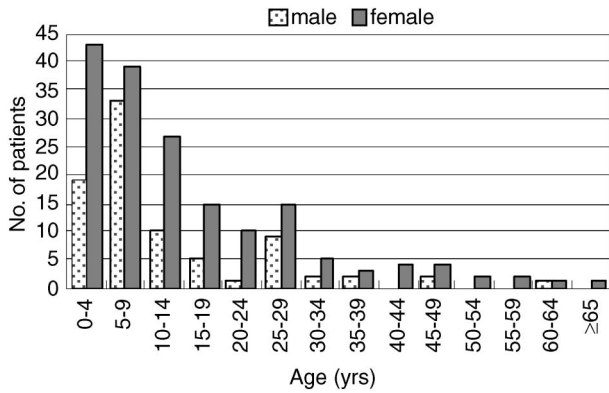


Fig. 1 Age of onset by sex.<sup>7)</sup>

moyamoya disease, as well as the establishment of the “Guidelines for Diagnostic Imaging by MRI and MRA” in 1995, which enabled the diagnosis of moyamoya disease based on only the MRA findings.

The male:female ratio reported from various studies is nearly consistent,<sup>7,8)</sup> 1:1.8 to 1.9. The disease is more common in women. In addition, a positive family history has been reported in about 10.0% of the patients.<sup>8)</sup>

### Age of Onset

The 1994 national survey<sup>8)</sup> and 2006 database evaluation<sup>7)</sup> showed a similar trend in relation to the age at onset of moyamoya disease: a bimodal peak consisting of a major peak in the first decade of life and a moderate peak in the late 20s to 30s (Fig. 1). However, a recent report has indicated a higher age as compared with that mentioned above as the peak age at onset.<sup>1)</sup>

The various disease types by which the initial attack can manifest are presented in detail in Chapter IV: Symptoms. The 2006 database evaluation<sup>7)</sup> has reported a unimodal peak age at onset in the late 20s for initial attacks of the hemorrhagic type, but a bimodal peak for initial attacks of other disease types (Fig. 2). However, according to another report, the peak age range of onset for initial attacks of the hemorrhagic type is the 5th to 6th decades of life (Chapter IV, Fig. 3).

### Asymptomatic Moyamoya Disease

In recent years, asymptomatic cases of moyamoya disease and moyamoya disease manifesting with only non-specific symptoms, such as headache, have drawn attention. The increase in the number of such patients could be attributable, at least in part, to the current widespread availability of MRI and the in-

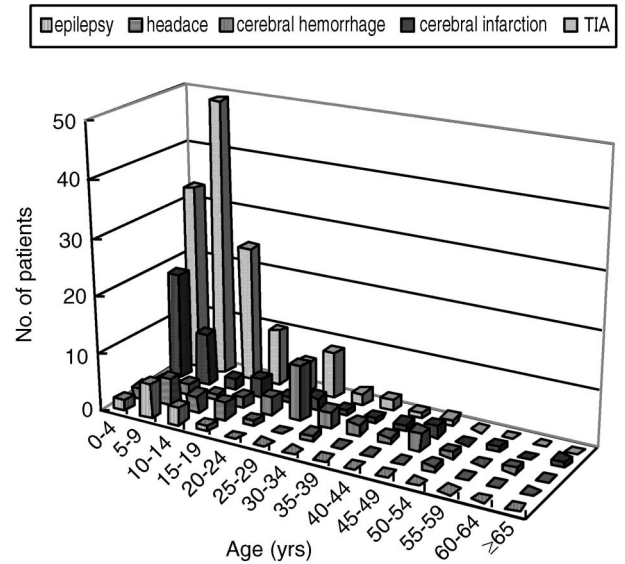


Fig. 2 Age of onset by disease type of the initial attack.<sup>7)</sup> TIA: transient ischemic attack.

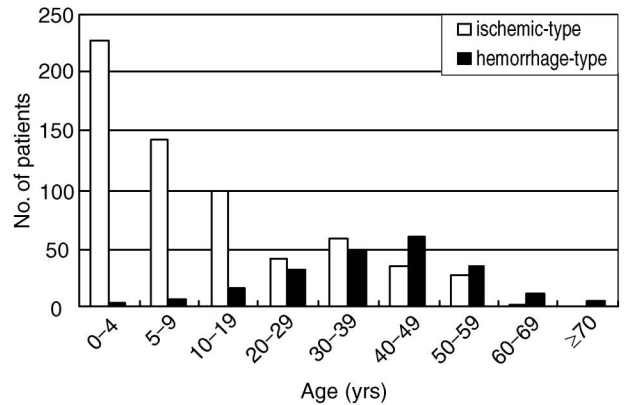


Fig. 3 Age of onset of ischemic-type and hemorrhagic-type moyamoya disease (n = 1127).

crease in the number of people undergoing medical checkup procedures for the brain.

Ikeda et al.<sup>3)</sup> performed MRI/MRA in 11,402 healthy people (male n = 7,570, female n = 3,832) who underwent a medical checkup for the brain and estimated a prevalence rate for moyamoya disease of 50.7 people per 100,000 healthy (asymptomatic) population. In an epidemiological survey conducted by Baba et al. in Hokkaido,<sup>1)</sup> the prevalence rate of moyamoya disease was estimated as 10.5 people per 100,000 persons. This prevalence rate is higher than that reported from the previous national survey. While the possibility of including patients with atherosclerosis cannot be ruled out, it could include a considerable number of patients with latent

moyamoya disease (asymptomatic or only minor symptoms).

### Distribution of Moyamoya Disease in the World

Goto and Yonekawa<sup>2)</sup> reviewed papers published between 1972 to 1989 and reported that 1,063 patients had been notified as being affected by moyamoya disease in the world excluding Japan, and that of these, 625 patients were Asian (Korean n = 289, Chinese n = 245), 201 were European, and 176 were South or North American. The 1990 national survey reported an estimated 3,000 Japanese patients. Even allowing for differences in the rate of recognition of the disease, moyamoya disease appears to be a common illness in Asia, with the maximum number of cases from Japan. What is of even greater interest is that many patients of moyamoya disease reported from Europe and South/North America are Asian or African people, with the disease only rarely reported in Caucasians. Ikezaki et al.<sup>4)</sup> also reported 451 patients from 29 institutions in South Korea in a 1995 survey.

#### References

- 1) Baba T, Houkin K, Kuroda S: Novel epidemiological features of moyamoya disease. *J Neurol Neurosurg Psychiatry* 79: 900–904, 2008
- 2) Goto Y, Yonekawa Y: Worldwide distribution of moyamoya disease. *Neurol Med Chir (Tokyo)* 32:

883–886, 1992

- 3) Ikeda K, Iwasaki Y, Kashihara H, Hosozawa K, Anan K, Tamura M, Satoyoshi E, Ikeda H: Adult moyamoya disease in the asymptomatic Japanese population. *J Clin Neurosci* 13: 334–338, 2006
- 4) Ikezaki K, Han DH, Kawano T, Kinukawa N, Fukui M: A clinical comparison of definite moyamoya disease between South Korea and Japan. *Stroke* 28: 2513–2517, 1997
- 5) Kudo T: [The cause of spontaneous occlusion of the circle of Willis], in Tazaki Y (ed): [Adult Diseases Medical Examination Course, vol 3. Stroke]. Tokyo, Kanehara, 1975, pp 253–259 (Japanese)
- 6) Mizukawa N, Ueda K, Takeuchi S, Nishimoto A: [Abnormal vascular network at the brain base: General theory: Statistical observation and problems]. *Igaku No Ayumi* 9: 279, 1974 (Japanese)
- 7) Ohki K, Hoshino H, Suzuki N, Nogawa S, Yamaguchi K: [2006 Database evaluation by the Research Committee on Moyamoya Disease (Spontaneous Occlusion of the Circle of Willis)], in: [Research on Spontaneous Occlusion of the Circle of Willis of the Ministry of Health, Labour and Welfare (Group Leader: Hashimoto N) 2006 Study Report]. 2007, pp 19–25 (Japanese)
- 8) Wakai K, Tamakoshi A, Ikezaki K, Fukui M, Kawamura T, Aoki R, Kojima M, Lin Y, Ohno Y: Epidemiological features of moyamoya disease in Japan: findings from a nationwide survey. *Clin Neurol Neurosurg* 99 Suppl 2: S1–5, 1997
- 9) Yamaguchi K, Nogawa S, Fukuuchi Y: [National survey on spontaneous occlusion of the circle of Willis (moyamoya disease)]. *Shinkei Naika* 54: 319–327, 2001 (Japanese)

## CHAPTER III: PATHOLOGY/ETIOLOGY

### Pathology

The main finding at autopsy is stenosis or occlusion of the terminal portion of the internal carotid arteries. Moyamoya vessels are assumed to represent collateral circulation which has developed to compensate for the cerebral ischemia occurring due to stenosis. In the early stage of the disease (stage I according to Suzuki's classification), moyamoya vessels are rarely observed. Degeneration of the smooth muscle cells in the media and the resultant death of the vascular smooth muscle cells cause thinning of the media. The waviness and duplication of the internal elastic lamina, accumulation of necrotic cell components in the interstitium, and proliferation of the vascular smooth muscle cells induce thickening of the intima and narrowing of the intravascular lumen. These are the processes assumed to be involved in the formation of the occlusive lesions.<sup>7)</sup>

These changes noted in the terminal portion of the

internal carotid arteries suggest the possibility of similar occurrence in the systemic arteries.<sup>11)</sup> Qualitative abnormalities of the vascular smooth muscle cells are considered to be an underlying reason for the internal carotid artery occlusion. Transcription factors such as tumor growth factor- $\beta$  and growth factors such as basic fibroblast growth factor and human growth factor have also been implicated.<sup>10)</sup>

Genetic factors are also considered to be closely involved; however, because penetrance is incomplete and depends on the age, accumulation of the effects of genetic factors is believed to induce vascular smooth muscle cell death and proliferation.<sup>9)</sup>

### Familial Moyamoya Disease

Both familial moyamoya disease, referring to the accumulation of affected patients among relatives, and sporadic moyamoya disease, where no affected per-

son is identified among relatives, have been reported. Familial moyamoya disease has been reported to account for approximately 10% of all cases of moyamoya disease.<sup>6)</sup> Nonetheless, with the recent advances and spread of MRA, a non-invasive test, the number of cases of asymptomatic moyamoya disease among the relatives of patients has been increasing.<sup>4)</sup>

### Genetic Factors

For familial moyamoya disease, gene loci have been identified in 3p24-p26<sup>1)</sup> and 8q23<sup>8)</sup> in a genomewide analysis, and in 6q25 (D6S441)<sup>2)</sup> and 17q25<sup>12)</sup> in a chromosomal search. In families with strong genetic factors, in which affected people are identified in 3 or more generations, the disease assumes an autosomal dominant inheritance pattern,<sup>6)</sup> and a significant linkage to 17q25.3 has been noted in these families.<sup>5)</sup> At present, it is thought that the responsible genes are present in multiple gene loci, representing locus heterogeneity.

Cases of unilateral moyamoya disease progressing to bilateral moyamoya disease,<sup>3)</sup> and of progression of major artery stenosis on the side contralateral to the initial disease have been reported. Therefore, the possibility that major artery stenosis, unilateral moyamoya disease, and narrow-defined bilateral moyamoya disease are also a series of sequential lesions, established based on the same genetic susceptibility has been suggested for familial moyamoya disease.<sup>5)</sup> In addition, familial moyamoya disease is an autosomal dominantly inherited disease with incomplete penetrance, and various stages of the disease are noted in the same family. Consequently, interactions between genetic factors and aging or environmental factors are assumed to be necessary for the development of the disease.

### References

- 1) Ikeda H, Sasaki T, Yoshimoto T, Fukui M, Arinami T: Mapping of a familial moyamoya disease gene to chromosome 3p24.2-p26. *Am J Hum Genet* 64: 533-537, 1999
- 2) Inoue TK, Ikezaki K, Sasazuki T, Matsushima T, Fukui M: Linkage analysis of moyamoya disease on chromosome 6. *J Child Neurol* 15: 179-182, 2000
- 3) Kelly ME, Bell-Stephens TE, Marks MP, Do HM, Steinberg GK: Progression of unilateral moyamoya disease: A clinical series. *Cerebrovasc Dis* 22: 109-115, 2006
- 4) Kuroda S, Ishikawa T, Houkin K, Nanba R, Hokari M, Iwasaki Y: Incidence and clinical features of disease progression in adult moyamoya disease. *Stroke* 36: 2148-2153, 2005
- 5) Mineharu Y, Liu W, Inoue K, Matsuura N, Inoue S, Takenaka K, Ikeda H, Houkin K, Takagi Y, Kikuta K, Nozaki K, Hashimoto N, Koizumi A: Autosomal dominant moyamoya disease maps to chromosome 17q25.3. *Neurology* 70: 2357-2363, 2008
- 6) Mineharu Y, Takenaka K, Yamakawa H, Inoue K, Ikeda H, Kikuta KI, Takagi Y, Nozaki K, Hashimoto N, Koizumi A: Inheritance pattern of familial moyamoya disease: autosomal dominant mode and genomic imprinting. *J Neurol Neurosurg Psychiatry* 77: 1025-1029, 2006
- 7) Oka K, Yamashita M, Sadoshima S, Tanaka K: Cerebral haemorrhage in Moyamoya disease at autopsy. *Virchows Arch A Pathol Anat Histol* 392: 247-261, 1981
- 8) Sakurai K, Horiuchi Y, Ikeda H, Ikezaki K, Yoshimoto T, Fukui M, Arinami T: A novel susceptibility locus for moyamoya disease on chromosome 8q23. *J Hum Genet* 49: 278-281, 2004
- 9) Takagi Y, Kikuta K, Sadamasa N, Nozaki K, Hashimoto N: Caspase-3-dependent apoptosis in middle cerebral arteries in patients with moyamoya disease. *Neurosurgery* 59: 894-901, 2006
- 10) Takahashi A, Sawamura Y, Houkin K, Kamiyama H, Abe H: The cerebrospinal fluid in patients with moyamoya disease (spontaneous occlusion of the circle of Willis) contains high level of basic fibroblast growth factor. *Neurosci Lett* 160: 214-216, 1993
- 11) Weber C, Tato F, Brandl T, Kellner W, Hoffmann U: Adult moyamoya disease with peripheral artery involvement. *J Vasc Surg* 34: 943-946, 2001
- 12) Yamauchi T, Tada M, Houkin K, Tanaka T, Nakamura Y, Kuroda S, Abe H, Inoue T, Ikezaki K, Matsushima T, Fukui M: Linkage of familial moyamoya disease (spontaneous occlusion of the circle of Willis) to chromosome 17q25. *Stroke* 31: 930-935, 2000

## CHAPTER IV: SYMPTOMS

### Disease Type Manifested at the Initial Attack

Moyamoya disease may occur at any age from childhood to adulthood. In general, the initial manifestation is cerebral ischemic symptoms in children and intracranial hemorrhage symptoms in addition to ischemic symptoms in adults. The distribution of the age of development of the ischemic type and hemorrhagic type of moyamoya disease in 1,127 definitive moyamoya disease patients registered in the national survey conducted by the Research Committee on Moyamoya Disease until 2000 is illustrated in Fig. 3.<sup>9)</sup> The symptoms and course vary according to the age and the disease type manifested at the initial attack, and varying degrees of severity of symptoms have been noted, such as transient attacks and attacks which resulted in fixed neurological deficits. With the recent increase in the availability of MRI, many patients who were incidentally identified as having moyamoya disease during the asymptomatic stage<sup>4)</sup> or with only the complaint of headache<sup>2)</sup> have been reported.

The Research Committee on Moyamoya Disease classified the initial attacks into 6 types in 1979: “hemorrhagic-type,” “epileptic-type,” “infarction-type,” “transient ischemic attack (TIA)-type,” “frequent TIA-type” (twice or more often per month), and “other.” Subsequently, the “asymptomatic-type” was added, and in 2003 “headache-type” was also added. The proportions of patients with each of the disease types at the initial attack in 962 patients registered from 2003 to 2006 are listed in Table 1.<sup>8)</sup> The data belong mainly to patients from medical institutions to which the committee members belonged. In a complete survey in Hokkaido, the fre-

**Table 1 Disease type manifested at the initial attack (n = 962)**

Disease type	No. of patients
TIA	353 (37%)
Frequent TIA	63 (7%)
Cerebral infarction	165 (17%)
Intracerebral hemorrhage	186 (19%)
Headache	57 (6%)
Epilepsy	29 (3%)
Asymptomatic	32 (3%)
Others	13 (1%)
Details unknown	64 (7%)

TIA: transient ischemic attack.

quency of the asymptomatic-type has been reported to have increased further, and the percentage of adult patients has also been suggested to have possibly increased as compared with the figure reported previously.<sup>1)</sup>

### Frequency of Each Symptom

The frequency of each initial symptom in the 1,127 definitive moyamoya disease patients registered until 2000 is presented in Table 2 for the patients with the hemorrhagic-type and ischemic-type (infarction-type, TIA-type, and frequent TIA-type) of initial attack. For both types, muscle weakness, consciousness disturbance, headache, speech disorder, and sensory disturbance were the most frequent, however, the incidence of consciousness disturbance and headache was higher and the incidence of muscle weakness lower for patients with the hemorrhagic-type than for the ischemic-type initial attacks ( $p < 0.01$ ).<sup>9)</sup>

### Characteristics of Symptoms According to the Age and Disease Type

Symptoms vary according to the age and disease type. In children, the disease often manifests initially with cerebral ischemic symptoms, particularly after hyperventilation caused by strenuous exercise, crying, harmonica playing, and eating a hot meal. Symptoms such as cataplexy (quadriplegia, hemiplegia, and monoplegia), sensory disturbance, consciousness disturbance, seizure, and headache occur in a paroxysmal and recurrent manner. The symptoms always appear on the same side in many

**Table 2 Initial symptom (n = 1127)**

Initial symptom	Hemorrhagic type (%)	Ischemic type (%)
Muscle weakness	58.6	79.8*
Consciousness disturbance	70.4*	14.1
Headache	64.6*	18.8
Seizure	8.5	8.0
Psychiatric symptom	8.7	2.5
Speech disorder	24.5	20.1
Sensory disturbance	18.4	19.3
Involuntary movement	3.3	3.0
Intellectual disturbance	5.3	6.2
Visual impairment	2.0	3.2
Visual field defect	3.9	5.0

\*Significantly more frequent as compared with the others ( $p < 0.05$ ).

patients, but occasionally, the affected side interchanges between the right and left sides. In addition, some patients develop involuntary movements such as chorea<sup>5)</sup> and limb shaking. Such cerebral ischemia attacks may persist or resolve. In patients with repeated cerebral ischemia attacks, cerebral atrophy occurs, leading to mental dysfunction or diminished intelligence,<sup>6)</sup> or sequelae of cerebral infarction may remain. In moyamoya disease, the posterior cerebral arteries often remain patent until the advanced stage of the disease,<sup>3)</sup> however, in some patients, posterior cerebral artery disorder may result in visual impairment or visual field defect.<sup>7)</sup> In pediatric patients, particularly those aged less than 5 years old, intracranial bleeding rarely occurs, unlike in adult patients.

In adult patients, especially those aged 25 years or older, moyamoya disease frequently manifests with sudden-onset intracranial hemorrhage (intraventricular, subarachnoid space, or intracerebral hemorrhage), causing symptoms such as consciousness disturbance, headache, muscle weakness, and speech disorder, according to the site of hemorrhage. Intracranial hemorrhage is often small intraventricular hemorrhage so that the symptoms may abate, however, it may also cause fixed neurological deficits or progress to a more serious condition and lead to death. In addition, the patients are at a high risk of rebleeding, and approximately a half of the patients die as a result of bleeding.

In addition to these symptoms, moyamoya disease may also manifest as cerebral ischemia attacks in adult patients as in pediatric patients. In such patients, age-related vascular changes are also present. This may cause cerebral infarction, resulting in permanent impairment in many cases.

As previously described, with the recent widespread availability of MRI, an increasing number of patients with only headache or even entirely asymptomatic patients are detected to have moyamoya disease. The characteristics of the headache vary, and may be migraine-like throbbing pain or the dull headache noted in tension-type headache. The precise mechanism is not yet fully understood.

## References

- 1) Baba T, Kuroda S, Hokin K: [Recent trend of notified patients with moyamoya disease: Complete survey in Hokkaido 2002–2006], in: [Study on the Pathology and Treatment of Spontaneous Occlusion of the Circle of Willis (Chief Researcher: Hashimoto N) 2006 Comprehensive/Subdivided Study Report]. 2007, pp 4–5 (Japanese)
- 2) Fukuuchi Y (ed): [Research Committee on Moyamoya Disease (Spontaneous Occlusion of the Circle of Willis): New database—importance of headache as a symptom], in: [Study on the Etiology and Pathology of Spontaneous Occlusion of the Circle of Willis (Chief Researcher: Yoshimoto T) 2002–2004 General Study Report]. 2005, pp 9–13 (Japanese)
- 3) Kudo T: Spontaneous occlusion of the circle of Willis. A disease apparently confined to Japanese. *Neurology* 18: 485–496, 1968
- 4) Kuroda S, Hashimoto N, Yoshimoto T, Iwasaki Y: Radiological findings, clinical course, and outcome in asymptomatic moyamoya disease: results of multicenter survey in Japan. *Stroke* 38: 1430–1435, 2007
- 5) Lyoo CH, Oh SH, Joo JY, Chung TS, Lee MS: Hemidystonia and hemichoreoathetosis as an initial manifestation of moyamoya disease. *Arch Neurol* 57: 1510–1512, 2000
- 6) Matsushima Y, Aoyagi M, Nariai T, Takada Y, Wakimoto H, Oki J, Srivatanakul K, Hirakawa K, Motoki K: [Long-term prognosis of intelligence in childhood moyamoya patients evaluated by Wechsler tests. I. Determination of standard changes in intelligence of non-operated patients]. *Shoni No Noshinkei* 21: 224–231, 1996 (Japanese)
- 7) Miyamoto S, Kikuchi H, Karasawa J, Nagata I, Ihara I, Yamagata S: Study of the posterior circulation in moyamoya disease. Part 2: Visual disturbances and surgical treatment. *J Neurosurg* 65: 454–460, 1986
- 8) Ohki K, Hoshino H, Suzuki N, Nogawa S, Yamaguchi K: [2006 Database evaluation by the Research Committee on Moyamoya Disease (Spontaneous Occlusion of the Circle of Willis)], in: [Research on Spontaneous Occlusion of the Circle of Willis of the Ministry of Health, Labour and Welfare (Group Leader: Hashimoto N)]. 2007, pp 19–25 (Japanese)
- 9) Yamaguchi K, Nogawa S, Fukuuchi Y: [National survey on spontaneous occlusion of the circle of Willis (moyamoya disease)]. *Shinkei Naika* 54: 319–327, 2001 (Japanese)

## CHAPTER V: SIMILAR CONDITIONS

### Quasi-moyamoya Disease

#### 1. Definition

Quasi-moyamoya disease refers to the presence of stenosis or occlusion of the terminal portion of the internal carotid artery or proximal portion of the anterior and/or middle cerebral arteries accompanied by an abnormal vascular network detected in association with an underlying disease. Even in cases with unilateral lesions, if an underlying disease is present, the condition is considered as quasi-moyamoya disease.

This condition is also called “rui-moyamoya disease” in Japanese and “quasi-moyamoya disease” in English (synonym of “moyamoya syndrome” or “akin to moyamoya disease”). Unilateral moyamoya disease without underlying disease should be considered as probable moyamoya disease and be differentiated from quasi-moyamoya disease.

#### 2. Supplemental notes

The following illnesses have been reported as underlying diseases: atherosclerosis, autoimmune disease (systemic lupus erythematosus, antiphospholipid antibody syndrome, periarteritis nodosa, and Sjögren’s syndrome), meningitis, von Recklinghausen’s disease, brain tumors, Down’s syndrome, head injury, irradiation, hyperthyroidism, stenoccephaly, Turner’s syndrome, Alagille’s syndrome, William’s syndrome, Noonan’s syndrome, Marfan’s syndrome, tuberous sclerosis, Hirschsprung’s disease, glycogen storage disease type I, Prader-Willi syndrome, Wilms tumor, primary oxalosis, sickle cell disease, Fanconi’s anemia, spherocytosis, eosinophilic granuloma, type II plasminogen deficiency, leptospirosis, pyruvate kinase deficiency, protein someone deficiency, protein C deficiency, fibromuscular hyperplasia, osteogenesis imperfecta, polycystic kidney, oral contraceptives, and drug poisoning (cocaine, etc.).

#### 3. Evidence

Quasi-moyamoya disease can affect people of all races. Concurrent occurrence with underlying congenital disease is frequent in children, while that with acquired underlying disease is common in adults.<sup>6,11)</sup> Quasi-moyamoya disease may manifest as epilepsy or headache, or be asymptomatic.<sup>6,11)</sup> Copresence of symptoms associated with mental retardation due to underlying disease and those associated with cerebrovascular disorder results in a complicated clinical condition.<sup>6)</sup>

Cerebral angiographic findings vary widely from those very similar to definitive moyamoya disease to rather different, such as atherosclerotic lesions.<sup>3,6)</sup> In a study of quasi-moyamoya disease associated with von Recklinghausen’s disease, unilateral lesions were noted in 30% of the cases.<sup>3)</sup> In quasi-moyamoya disease after irradiation, the affected arteries were enhanced by a contrast agent, whereas no significant contrast enhancement was noted in patients with definitive moyamoya disease.<sup>1)</sup> In moyamoya disease associated with irradiation, collateral circulation involving the external carotid arteries is well developed.<sup>3)</sup> Pathological findings also vary according to the underlying disease. In quasi-moyamoya disease concurrently associated with von Recklinghausen’s disease, inflammatory cell infiltration is noted in the lesions.<sup>4)</sup> The findings of quasi-moyamoya disease secondary to meningitis were similar to those of definitive moyamoya disease.<sup>2)</sup>

The treatment of quasi-moyamoya disease is like that of definitive moyamoya disease. For quasi-moyamoya disease associated with hormonal abnormalities, such as hyperthyroidism, or with autoimmune disorder, correction of the hormonal abnormality and immunosuppressive therapy, respectively, are reported to be effective.<sup>2,5)</sup> For quasi-moyamoya disease associated with von Recklinghausen’s disease, Down’s syndrome, or irradiation, revascularization (direct and indirect) has been demonstrated to be effective.<sup>7,8,12)</sup> The effect of revascularization on the prevention of rebleeding in patients with quasi-moyamoya disease has not yet been clarified. In quasi-moyamoya disease, unilateral involvement may progress to bilateral disease.<sup>9)</sup> The nature of the underlying diseases influences the prognosis of patients with quasi-moyamoya disease.<sup>10)</sup>

#### References

- 1) Aoki S, Hayashi N, Abe O, Shirouzu I, Ishigame K, Okubo T, Nakagawa K, Ohtomo K, Araki T: Radiation-induced arteritis: thickened wall with prominent enhancement on cranial MR images report of five cases and comparison with 18 cases of Moyamoya disease. *Radiology* 223: 683-688, 2002
- 2) Czartoski T, Hallam D, Lacy JM, Chun MR, Becker K: Postinfectious vasculopathy with evolution to moyamoya syndrome. *J Neurol Neurosurg Psychiatry* 76: 256-259, 2005
- 3) Horn P, Pfister S, Buelmann E, Vajkoczy P, Schmiedek P: Moyamoya-like vasculopathy (moyamoya syndrome) in children. *Childs Nerv Syst* 20: 382-391, 2004



- 4) Hosoda Y, Ikeda E, Hirose S: Histopathological studies on spontaneous occlusion of the circle of Willis (cerebrovascular moyamoya disease). *Clin Neurol Neurosurg* 99 Suppl 2: S203-208, 1997
- 5) Im SH, Oh CW, Kwon OK, Kim JE, Han DH: Moyamoya disease associated with Graves disease: special considerations regarding clinical significance and management. *J Neurosurg* 102: 1013-1017, 2005
- 6) Inoue T, Matsushima T, Fujii K, Fukui M, Hasuo K, Matsuo H: [Akin moyamoya disease in children]. *No Shinkei Geka* 21: 59-65, 1993 (Japanese)
- 7) Ishikawa T, Houkin K, Yoshimoto T, Abe H: Vasoconstructive surgery for radiation-induced vasculopathy in childhood. *Surg Neurol* 48: 620-626, 1997
- 8) Jea A, Smith ER, Robertson R, Scott RM: Moyamoya syndrome associated with Down syndrome: outcome after surgical revascularization. *Pediatrics* 116: e694-e701, 2005
- 9) Kelly ME, Bell-Stephens TE, Marks MP, Do HM, Steinberg GK: Progression of unilateral moyamoya disease: A clinical series. *Cerebrovasc Dis* 22: 109-115, 2006
- 10) Kestle JR, Hoffman HJ, Mock AR: Moyamoya phenomenon after radiation for optic glioma. *J Neurosurg* 79: 32-35, 1993
- 11) Rosser TL, Vezina G, Packer RJ: Cerebrovascular abnormalities in a population of children with neurofibromatosis type 1. *Neurology* 64: 553-555, 2005
- 12) Scott RM, Smith JL, Robertson RL, Madsen JR, Soriano SG, Rockoff MA: Long-term outcome in children with moyamoya syndrome after cranial revascularization by pial synangiosis. *J Neurosurg* 100: 142-149, 2004

## Unilateral Cases

### 1. Definition

Unilateral moyamoya disease is also referred to as probable moyamoya disease and refers to the presence of unilateral stenosis or occlusion of the terminal portion of the internal carotid arteries accompanied by the formation of moyamoya vessels around that region. These unilateral changes may occur concurrently with other underlying diseases, such as hyperthyroidism, intracranial arteriovenous malformation, Down's syndrome, Apert's syndrome, von Recklinghausen's disease, postirradiation of the head, systemic lupus erythematosus, and Sjögren's syndrome; when these underlying diseases are present, the condition is classified as quasi-moyamoya disease and not as unilateral moyamoya disease.<sup>9)</sup> In children, unilateral moyamoya disease associated with stenosis of the terminal portion of the internal carotid arteries on the other side should be considered as definitive moyamoya disease and

not as unilateral moyamoya disease.<sup>2)</sup>

### 2. Epidemiology

In a primary survey conducted in 2,998 Japanese institutions in 2006, the frequency of unilateral moyamoya disease was 10.6% among 2,635 patients with moyamoya disease, including initially diagnosed and re-diagnosed patients.<sup>13)</sup> A family history is occasionally present for patients with unilateral moyamoya disease.<sup>10)</sup> An analysis of 15 families having a family history of the disease in 3 or more generations revealed 5 patients with concurrent unilateral moyamoya disease in addition to 43 patients with definitive moyamoya disease, and suggested the possibility that the disease was inherited by the same autosomal dominant inheritance pattern. Because of this, unilateral moyamoya disease with a family history is also viewed as a subtype of moyamoya disease.<sup>12)</sup> In addition, unilateral moyamoya disease is also distinguished from definitive moyamoya disease without a positive family history or increased basic fibroblast growth factor levels in the cerebrospinal fluid.<sup>5)</sup>

### 3. Symptoms and diagnostic methods

The symptoms of unilateral moyamoya disease are basically the same as those of definitive moyamoya disease. In addition to cerebral ischemic symptoms,<sup>14)</sup> cerebral hemorrhage,<sup>1)</sup> concurrent cerebral aneurysm,<sup>6)</sup> involuntary movement,<sup>15)</sup> etc. may be noted. A definitive diagnosis is made based on cerebral angiography, and the severity of cerebral ischemia is determined by brain perfusion scintigraphy.<sup>4)</sup>

### 4. Progression from unilateral to bilateral moyamoya disease

The reported frequency of progression from unilateral to bilateral moyamoya disease varies from 10% to 39% among reports.<sup>7)</sup> In a study where 10 patients with unilateral moyamoya disease were followed up for 10 years, the condition progressed to bilateral disease in only 1 (10%) pediatric patient; thus, progression to bilateral disease appears to be rare.<sup>5)</sup> In another study conducted on children, however, unilateral disease progressed to bilateral disease in 2 of 6 patients (33%)<sup>11)</sup> and in a study of 64 patients with unilateral moyamoya disease followed up for 1 to 7 years, progression to bilateral disease was noted in 17 (27%) patients, and such progression to bilateral disease within 5 years was frequent in children with early-onset of moyamoya disease (age at onset 10 years or less).<sup>9)</sup> In a follow-up study of 12 pediatric patients and 5 adult patients, progression to bilateral disease was noted in only 6 (39%)

pediatric patients during a 20-month follow-up period.<sup>3)</sup>

In contrast, in a recent follow-up study of 28 patients with unilateral moyamoya disease, the condition progressed to bilateral disease in 7 (25%) patients, and 5 of these patients were adults. Thus, progression to bilateral disease may be noted not only in pediatric patients, but also in adult patients. The statistically significant risk factors for progression to bilateral disease have been suggested to be the presence of equivocal or mild stenotic changes in the internal carotid artery, middle cerebral artery, or anterior cerebral artery of the other side.<sup>8)</sup>

### References

- 1) Cultrera F, Giuffrida M, Alberio N, Chiaramonte I: Hemorrhagic unilateral moyamoya: report of one case. *Neurologia* 19: 277-279, 2004
- 2) Fukui M: Guidelines for the diagnosis and treatment of spontaneous occlusion of the circle of Willis ('moyamoya' disease). Research Committee on Spontaneous Occlusion of the Circle of Willis (Moyamoya Disease) of the Ministry of Health and Welfare, Japan. *Clin Neurol Neurosurg* 99 Suppl 2: S238-240, 1997
- 3) Hirotsune N, Meguro T, Kawada S, Nakashima H, Ohmoto T: Long-term follow-up study of patients with unilateral moyamoya disease. *Clin Neurol Neurosurg* 99 Suppl 2: S178-181, 1997
- 4) Honda N, Machida K, Takishima T, Kaizu H, Sugimoto E: Iodine-123 IMP SPECT before and after bypass surgery in a patient with occlusion of left anterior and middle cerebral arteries with basal abnormal telangiectasis (unilateral Moyamoya disease). *Ann Nucl Med* 1: 43-46, 1987
- 5) Houkin K, Abe H, Yoshimoto T, Takahashi A: Is "unilateral" moyamoya disease different from moyamoya disease? *J Neurosurg* 85: 772-776, 1996
- 6) Kasamo S, Asakura T, Yamamoto Y, Kobayashi E: Unilateral moyamoya disease associated with multiple aneurysms. A case report and review of the literature. *Neurol Med Chir (Tokyo)* 24: 30-34, 1984
- 7) Kawano T, Fukui M, Hashimoto N, Yonekawa Y: Follow-up study of patients with "unilateral" moyamoya disease. *Neurol Med Chir (Tokyo)* 34: 744-747, 1994
- 8) Kelly ME, Bell-Stephens TE, Marks MP, Do HM, Steinberg GK: Progression of unilateral moyamoya disease: A clinical series. *Cerebrovasc Dis* 22: 109-115, 2006
- 9) Kitagawa K: ["Guidelines for diagnosis of quasi-moyamoya disease" subdivided study report], in: [Health Labour Sciences Research Grant for Research on Measures for Intractable Diseases 2006 Comprehensive/Subdivided Study Report]. 2007, p 68 (Japanese)
- 10) Kusaka N, Tamiya T, Adachi Y, Katayama S, Namba S, Tokunaga K, Sugi K, Date I, Ohmoto T: Adult unilateral moyamoya disease with familial occurrence in two definite cases: a case report and review of the literature. *Neurosurg Rev* 29: 82-87, 2006
- 11) Matsushima T, Inoue T, Natori Y, Fujii K, Fukui M, Hasuo K, Kuwabara Y: Children with unilateral occlusion or stenosis of the ICA associated with surrounding moyamoya vessels—"unilateral" moyamoya disease. *Acta Neurochir (Wien)* 131: 196-202, 1994
- 12) Mineharu Y, Inoue K, Inoue S, Yamada S, Nozaki K, Hashimoto N, Koizumi A: Model-based linkage analyses confirm chromosome 19q13.3 as a susceptibility locus for intracranial aneurysm. *Stroke* 38: 1174-1178, 2007
- 13) Nagata I: ["Pathology and treatment of unilateral moyamoya disease" subdivided study report], in: [Health Labour Sciences Research Grant for Research on Measures for Intractable Diseases 2006 Comprehensive/Subdivided Study Report]. 2007, p 38 (Japanese)
- 14) Nagata S, Matsushima T, Morioka T, Matsukado K, Mihara F, Sasaki T, Fukui M: Unilaterally symptomatic moyamoya disease in children: long-term follow-up of 20 patients. *Neurosurgery* 59: 830-837, 2006
- 15) Nijdam JR, Luijten JA, van Gijn J: Cerebral haemorrhage associated with unilateral Moyamoya syndrome. *Clin Neurol Neurosurg* 88: 49-51, 1986

## CHAPTER VI: DIAGNOSIS

### Cerebral Angiography, MRI, etc.

#### 1. Recommendations

Cerebral angiography is essential for a definitive diagnosis of moyamoya disease (Chapter I, Diagnostic Criteria).<sup>2)</sup> MRI can provide a definitive diagnosis when the following findings are fulfilled on time of flight imaging conducted using a scanner with a magnetostatic intensity of  $\geq 1.5$  T (especially 3.0 T)<sup>2-4,9)</sup>:

(1) On MRA, stenosis or occlusion of the terminal

portion of the intracranial internal carotid artery or proximal portion of the anterior and/or middle cerebral arteries.

(2) On MRA, abnormal vascular networks in the basal ganglia.

Note: When 2 or more visible flow voids in the basal ganglia are present at least unilaterally on MRI, they can be deemed as representing an abnormal vascular network.

(3) Bilaterality of findings (1) and (2).

Stage classification can also be made based on the

**Table 3 Stage classification**

Stage	Cerebral angiographic findings
I	narrowing of the carotid fork
II	initiation of the moyamoya (dilated major cerebral artery and a slight moyamoya vessel network)
III	intensification of the moyamoya (disappearance of the middle and anterior cerebral arteries, and thick and distinct moyamoya vessels)
IV	minimization of the moyamoya (disappearance of the posterior cerebral artery, and narrowing of individual moyamoya vessels)
V	reduction of the moyamoya (disappearance of all the main cerebral arteries arising from the internal carotid artery system, further minimization of the moyamoya vessels, and an increase in the collateral pathways from the external carotid artery system)
VI	disappearance of the moyamoya (disappearance of the moyamoya vessels, with cerebral blood flow derived only from the external carotid artery and the vertebrobasilar artery systems)

MR findings in some cases; and is useful in consideration of the safety of examination (Appendix 1, recommendation grade C1).<sup>2)</sup>

## 2. Explanation

In principle, the diagnosis of moyamoya disease is made based on the following:

- (1) stenosis or occlusion of the terminal portion of the intracranial internal carotid artery or the proximal portion of the anterior and/or middle cerebral arteries;
- (2) abnormal vascular networks in the vicinity of the occlusive or stenotic lesions in the arterial phase; and
- (3) bilaterality of findings (1) and (2).

Cerebral angiography is essential for the diagnosis, but the above MR findings are, as an exception, recognized as diagnostic criteria (Appendix 1, evidence level III). However, the diagnostic criteria (1)-(3) should be considered as the standard for designation as an intractable disease by the Ministry of Health, Labour and Welfare. When assuming surgical treatment, conventional cerebral angiography should be performed as far as possible (evidence level III).<sup>2)</sup>

Stage classification based on the cerebral angiographic findings is well known (Table 3).<sup>7,8)</sup> On the other hand, a classification based on the MRA findings has been proposed (Table 4).<sup>6)</sup> In this system, the stage is determined by simply assigning scores to the MRA findings and then totaling the scores. The stage classification using this method corresponds well to the conventional classification based on an-

**Table 4 Classification and scoring based on the magnetic resonance angiographic (MRA) findings**

MRA findings	Score
1) Internal carotid artery	
normal	0
stenosis of C <sub>1</sub>	1
discontinuity of the C <sub>1</sub> signal	2
invisible	3
2) Middle cerebral artery	
normal	0
stenosis of M <sub>1</sub>	1
discontinuity of the M <sub>1</sub> signal	2
invisible	3
3) Anterior cerebral artery	
normal A <sub>2</sub> and its distal	0
A <sub>2</sub> and its distal signal decrease	1
invisible	2
4) Posterior cerebral artery	
normal P <sub>2</sub> and its distal	0
P <sub>2</sub> and its distal signal decrease	1
invisible	2

A total score of 1) to 4) is calculated individually for the right and left sides.

MRA total score	MRA stage
0-1	1
2-4	2
5-7	3
8-10	4

giography, and has been reported to have high sensitivity and specificity (evidence level III).<sup>6)</sup>

MRA stage 1 identified using the above approach corresponds to stages I and II of the angiographic classification, stage 2 corresponds to stage III, stage 3 corresponds to stage IV, and stage 4 corresponds to stages V and VI; so the classification is practical (evidence level III).<sup>6)</sup> MRA is effective for assessing the effects of surgical intervention and observing the angiographic changes after treatment (evidence level III).<sup>5)</sup> MRI perfusion imaging is also a useful and simple tool for cerebral blood flow (CBF) evaluation (evidence level III).<sup>1)</sup>

## References

- 1) Fujimura M, Mugikura S, Shimizu H, Tominaga T: [Diagnostic value of perfusion-weighted MRI for evaluating postoperative alteration of cerebral hemodynamics following STA-MCA anastomosis in patients with moyamoya disease]. *No Shinkei Geka* 34: 801-809, 2006 (Japanese)
- 2) Fukui M: Guidelines for the diagnosis and treatment

of spontaneous occlusion of the circle of Willis ('moyamoya' disease). Research Committee on Spontaneous Occlusion of the Circle of Willis (Moyamoya Disease) of the Ministry of Health and Welfare, Japan. *Clin Neurol Neurosurg* 99 Suppl 2: S238-240, 1997

- 3) Fushimi Y, Miki Y, Kikuta K, Okada T, Kanagaki M, Yamamoto A, Nozaki K, Hashimoto N, Hanakawa T, Fukuyama H, Togashi K: Comparison of 3.0- and 1.5-T three-dimensional time-of-flight MR angiography in moyamoya disease: preliminary experience. *Radiology* 239: 232-237, 2006
- 4) Houkin K, Aoki T, Takahashi A, Abe H: Diagnosis of moyamoya disease with magnetic resonance angiography. *Stroke* 25: 2159-2164, 1994
- 5) Houkin K, Nakayama N, Kuroda S, Ishikawa T, Nonaka T: How does angiogenesis develop in pediatric moyamoya disease after surgery? A prospective study with MR angiography. *Childs Nerv Syst* 20: 734-741, 2004
- 6) Houkin K, Nakayama N, Kuroda S, Nonaka T, Shonai T, Yoshimoto T: Novel magnetic resonance angiography stage grading for moyamoya disease. *Cerebrovasc Dis* 20: 347-354, 2005
- 7) Suzuki J, Kodama N: Cerebrovascular "Moyamoya" disease. 2. Collateral routes to forebrain via ethmoid sinus and superior nasal meatus. *Angiology* 22: 223-236, 1971
- 8) Suzuki J, Takaku A: Cerebrovascular "moyamoya" disease. Disease showing abnormal net-like vessels in base of brain. *Arch Neurol* 20: 288-299, 1969
- 9) Yamada I, Suzuki S, Matsushima Y: Moyamoya disease: comparison of assessment with MR angiography and MR imaging versus conventional angiography. *Radiology* 196: 211-218, 1995

## CBF-Single Photon Emission Computed Tomography (SPECT) and Positron Emission Tomography (PET), etc.

### 1. Recommendation

Evaluation of the cerebral hemodynamics by SPECT and PET is useful for diagnosis and assessment of the severity of cerebral ischemia in patients with ischemic-type moyamoya disease (Appendix 1, recommendation grade B).

### 2. Explanation

#### 2-1. Clinical significance of the examinations

CBF-SPECT and PET have been applied for evaluating the cerebral hemodynamics in patients with moyamoya disease. Assessment of the hemodynamic severity of cerebral ischemia using these diagnostic tools is clinically meaningful for determining the indications of cerebral revascularization and assessment of the therapeutic effects and prognosis, mainly in patients with moyamoya disease.

#### 2-2. Cerebral hemodynamics in patients with moyamoya disease

Evaluation of the cerebral hemodynamics using PET has been reported to reveal hemodynamically-induced cerebral ischemia and typical misery perfusion in both pediatric and adult patients with moyamoya disease<sup>2,6,8)</sup> (Appendix 1, evidence level III). This clinicopathological condition is characterized by cerebral ischemia, which induces a series of compensatory responses to maintain the cerebral metabolic rate of oxygen, including increase in the oxygen extraction fraction (decrease in the cerebral metabolic reserve), because CBF cannot be maintained by only the cerebral vasodilatory response (increase in cerebral blood volume, decrease in cerebrovascular reserve) owing to the marked decrease in the cerebral perfusion pressure. In regard to CBF-SPECT, with the development of the CBF tracers (iodine-123 N-isopropyl-p-iodoamphetamine, technetium-99m hexamethyl propylene amine oxime, and technetium-99m ethyl cysteinate dimer) and advances in the quantitative analysis procedures since the mid-1990s, both the CBF at rest and the CBF under acetazolamide-activation can be measured quantitatively; these advances in the techniques of SPECT have also enabled assessment of the hemodynamic severity of cerebral ischemia in patients with moyamoya disease<sup>11)</sup> (evidence level III). In atherothrombotic stroke, stage 2 hemodynamic cerebral ischemia, defined as  $\leq 80\%$  of the normal resting CBF and  $\leq 10\%$  of cerebrovascular reserve [(CBF under acetazolamide-activation/resting CBF - 1)  $\times 100\%$ ] as measured by quantitative SPECT is considered to be equivalent to the misery perfusion demonstrated by PET. Severity assessment using the same index has also been found to be useful in moyamoya disease patients, but no direct comparisons of the indices obtained using the two examinations have been made. Acetazolamide-activated SPECT should be performed carefully in pediatric patients with moyamoya disease assumed to have severe ischemia, because cerebral ischemia may deteriorate during the examination.

#### 2-3. Cerebral hemodynamics and outcome

A high recurrence rate in patients with misery perfusion demonstrated by PET, or stage 2 hemodynamic cerebral ischemia demonstrated by CBF-SPECT after a cerebral ischemic attack, has already been identified among patients with atherothrombotic stroke. For pediatric patients with moyamoya disease, a high recurrence rate of cerebral ischemic attacks has also been reported when the cerebrovascular reserve is markedly decreased<sup>13)</sup> (Appendix 1, evidence level IIb). In

pediatric patients, the outcome is poor in the group showing inadequate improvement of the cerebrovascular reserve after revascularization, and a high probability of residual neurological deficit and recurrent ischemic attacks during the course have been reported<sup>12)</sup> (evidence level IIa).

#### **2-4. Indications of cerebral revascularization based on evaluation of the cerebral hemodynamics**

In general, cerebral revascularization (extracranial-intracranial bypass) is indicated in patients with misery perfusion (on PET) or stage 2 hemodynamic cerebral ischemia (on CBF-SPECT), as it can be expected to improve the cerebral perfusion pressure. For moyamoya disease, because the clinical condition of cerebral ischemia progresses not only in children but also in adults<sup>4)</sup> (evidence level IIa), cerebral revascularization is considered when CBF-SPECT demonstrates decreased cerebrovascular reserve in patients with moyamoya disease manifesting as cerebral ischemia<sup>11)</sup> (evidence level III). Nonetheless, cerebral revascularization can be delayed until the development of ischemic symptoms in pediatric patients with only unilateral symptoms, as long as the cerebral ischemia on the asymptomatic side is not severe<sup>9)</sup> (evidence level III). In contrast, even if the cerebrovascular reserve is not decreased, cerebral revascularization has been performed for preventing rebleeding in patients with moyamoya disease manifesting as cerebral hemorrhage. However, there are practically no studies that can be used as evidence. Currently, an investigation of the cerebral hemodynamics is ongoing in the Japanese Adult Moyamoya (JAM) Trial in adult patients with moyamoya disease manifesting as cerebral hemorrhage in Japan<sup>7)</sup> (evidence level III).

#### **2-5. Cerebral hemodynamics after cerebral revascularization**

Long-term improvement of the cerebral hemodynamics after cerebral revascularization has been commonly reported, however, the number of reports on the improved postoperative outcome is limited<sup>12)</sup> (evidence level IIb). A hyperperfusion phenomenon, with transient deterioration of the neurological symptoms, has been reported to occur, sometimes immediately after cerebral revascularization in adult patients with moyamoya disease<sup>1)</sup> (evidence level III).

#### **2-6. Cerebral angiographic findings and cerebral hemodynamics**

Evaluation of the cerebral angiographic findings and cerebral hemodynamics in adult patients with moyamoya disease manifesting as cerebral ischemia

has revealed that cerebral ischemia is more severe in patients with a marked increase over a wide extent of basal moyamoya vessels than in those with less pronounced formation of moyamoya vessels; thus, the degree of development of moyamoya vessels as visualized on cerebral angiograms may well be an index for assessing the severity of cerebral ischemia<sup>10)</sup> (evidence level III).

#### **2-7. Re-build-up phenomenon on electroencephalogram and cerebral hemodynamics**

Electroencephalography performed in pediatric patients with moyamoya disease manifesting as cerebral ischemia has revealed the characteristic finding of the re-build-up phenomenon, assumed to be associated with a delay in recovery of the cortical CBF after hyperventilation loading.<sup>3)</sup> Examination by CBF-SPECT has revealed a marked decrease in the cerebrovascular reserve in the region showing the re-build-up phenomenon and also evident improvement of the cerebral hemodynamics in the region where the re-build-up phenomenon disappeared after cerebral revascularization<sup>5)</sup> (evidence level III).

#### **References**

- 1) Fujimura M, Kaneta T, Mugikura S, Shimizu H, Tominaga T: Temporary neurologic deterioration due to cerebral hyperperfusion after superficial temporal artery-middle cerebral artery anastomosis in patients with adult-onset moyamoya disease. *Surg Neurol* 67: 273-282, 2007
- 2) Ikezaki K, Matsushima T, Kuwabara Y, Suzuki SO, Nomura T, Fukui M: Cerebral circulation and oxygen metabolism in childhood moyamoya disease: a perioperative positron emission tomography study. *J Neurosurg* 81: 843-850, 1994
- 3) Kodama N, Aoki Y, Hiraga H, Wada T, Suzuki J: Electroencephalographic findings in children with moyamoya disease. *Arch Neurol* 36: 16-19, 1979
- 4) Kuroda S, Ishikawa T, Houkin K, Nanba R, Hokari M, Iwasaki Y: Incidence and clinical features of disease progression in adult moyamoya disease. *Stroke* 36: 2148-2153, 2005
- 5) Kuroda S, Kamiyama H, Isobe M, Houkin K, Abe H, Mitsumori K: Cerebral hemodynamics and "re-build-up" phenomenon on electroencephalogram in children with moyamoya disease. *Childs Nerv Syst* 11: 214-219, 1995
- 6) Kuwabara Y, Ichiya Y, Sasaki M, Yoshida T, Masuda K, Ikezaki K, Matsushima T, Fukui M: Cerebral hemodynamics and metabolism in moyamoya disease—a positron emission tomography study. *Clin Neurol Neurosurg* 99 Suppl 2: S74-78, 1997
- 7) Miyamoto S: Study design for a prospective randomized trial of extracranial-intracranial bypass surgery for adults with moyamoya disease and hemor-

- rhagic onset—the Japan Adult Moyamoya Trial Group. *Neurol Med Chir (Tokyo)* 44: 218–219, 2004
- 8) Morimoto M, Iwama T, Hashimoto N, Kojima A, Hayashida K: Efficacy of direct revascularization in adult Moyamoya disease: haemodynamic evaluation by positron emission tomography. *Acta Neurochir (Wien)* 141: 377–384, 1999
  - 9) Nagata S, Matsushima T, Morioka T, Matsukado K, Mihara F, Sasaki T, Fukui M: Unilaterally symptomatic moyamoya disease in children: long-term follow-up of 20 patients. *Neurosurgery* 59: 830–837, 2006
  - 10) Piao R, Oku N, Kitagawa K, Imaizumi M, Matsushita K, Yoshikawa T, Takasawa M, Osaki Y, Kimura Y, Kajimoto K, Hori M, Hatazawa J: Cerebral hemodynamics and metabolism in adult moyamoya disease: comparison of angiographic collateral circulation. *Ann Nucl Med* 18: 115–121, 2004
  - 11) Saito N, Nakagawara J, Nakamura H, Teramoto A: Assessment of cerebral hemodynamics in childhood moyamoya disease using a quantitative and a semi-quantitative IMP-SPECT study. *Ann Nucl Med* 18: 323–331, 2004
  - 12) So Y, Lee HY, Kim SK, Lee JS, Wang KC, Cho BK, Kang E, Lee DS: Prediction of the clinical outcome of pediatric moyamoya disease with postoperative basal/acetazolamide stress brain perfusion SPECT after revascularization surgery. *Stroke* 36: 1485–1489, 2005
  - 13) Touho H, Karasawa J, Ohnishi H: Preoperative and postoperative evaluation of cerebral perfusion and vasodilatory capacity with 99mTc-HMPAO SPECT and acetazolamide in childhood Moyamoya disease. *Stroke* 27: 282–289, 1996

## CHAPTER VII: TREATMENT

### Surgical Treatment

#### 1. Recommendations

Surgical revascularization is effective for moyamoya disease manifesting as cerebral ischemic symptoms (Appendix 1, recommendation grade B).

#### 2. Explanation

##### 2-1. Candidates for surgery

Surgical revascularization for moyamoya disease patients with cerebral ischemic attacks has been reported to reduce the frequency of TIAs and the risk of cerebral infarction, and improve the postoperative activities of daily living (ADL) and long-term prognosis of higher brain functions<sup>1,4,9,10,12,13,15,16</sup> (Appendix 1, evidence level IIb). Improvement of the cerebral hemodynamics and metabolism has been reported following revascularization surgery in patients with hemodynamic compromise, noted on preoperative evaluation, by SPECT or PET<sup>6,10,15</sup> (evidence level IIb).

##### 2-2. Surgical procedures

In regard to the revascularization procedures for moyamoya disease, direct revascularizations such as superficial temporal artery-middle cerebral artery anastomosis, indirect pial synangiosis such as encephalo-myo-synangiosis, encephalo-duro-arterio-synangiosis, encephalo-arterio-synangiosis, encephalo-duro-synangiosis, and multiple burr hole surgery have been employed. Both direct and indirect revascularizations or a combination of these two types of procedures have been reported to improve cerebral hemodynamics, ameliorating the severity/frequency of ischemic attacks, reducing the risk of

cerebral infarction, and improving the postoperative ADL and long-term prognosis of the higher brain functions in the patients<sup>1,4,6,9,10,12,13,15,16</sup> (evidence level IIb). The effect of only the indirect procedure is not very significant in adult patients, but direct revascularization is often effective.<sup>14</sup> In pediatric patients, surgical revascularization, regardless of whether direct or indirect revascularization was performed, has been reported to improve the prognosis<sup>7,11</sup> (evidence level IIb).

##### 2-3. Perioperative management

During the perioperative period, the blood pressure should be maintained, normocapnia should be ensured, and adequate body fluid balance should be maintained, while paying attention to ischemic complications, including on the non-surgical side<sup>8</sup> (evidence level III). When neurological symptoms may appear during the acute phase after revascularization, clinical conditions such as cerebral hyperperfusion syndrome should be considered in evaluating the cerebral hemodynamics<sup>2</sup> (evidence level III).

##### 2-4. Postoperative evaluation

Postoperative assessment of improvement of the CBF and of the cerebrovascular reserve capacity by PET and/or SPECT is considered to be useful for evaluating the effect of revascularization.<sup>6,10,15</sup> Both cerebral angiography and MRA have been reported to be useful for evaluation of development of the bypass flow<sup>3,5</sup> (evidence level III).

### References

- 1) Choi JU, Kim DS, Kim EY, Lee KC: Natural history of moyamoya disease: comparison of activity of daily

- living in surgery and non surgery groups. *Clin Neurol Neurosurg* 99 Suppl 2: S11–18, 1997
- 2) Fujimura M, Kaneta T, Mugikura S, Shimizu H, Tominaga T: Temporary neurologic deterioration due to cerebral hyperperfusion after superficial temporal artery-middle cerebral artery anastomosis in patients with adult-onset moyamoya disease. *Surg Neurol* 67: 273–282, 2007
  - 3) Honda M, Kitagawa N, Tsutsumi K, Morikawa M, Nagata I, Kaminogo M: Magnetic resonance angiography evaluation of external carotid artery tributaries in moyamoya disease. *Surg Neurol* 64: 325–330, 2005
  - 4) Houkin K, Kuroda S, Nakayama N: Cerebral revascularization for moyamoya disease in children. *Neurosurg Clin N Am* 12: 575–584, ix, 2001
  - 5) Houkin K, Nakayama N, Kuroda S, Ishikawa T, Nonaka T: How does angiogenesis develop in pediatric moyamoya disease after surgery? A prospective study with MR angiography. *Childs Nerv Syst* 20: 734–741, 2004
  - 6) Ikezaki K, Matsushima T, Kuwabara Y, Suzuki SO, Nomura T, Fukui M: Cerebral circulation and oxygen metabolism in childhood moyamoya disease: a perioperative positron emission tomography study. *J Neurosurg* 81: 843–850, 1994
  - 7) Ishikawa T, Houkin K, Kamiyama H, Abe H: Effects of surgical revascularization on outcome of patients with pediatric moyamoya disease. *Stroke* 28: 1170–1173, 1997
  - 8) Iwama T, Hashimoto N, Yonekawa Y: The relevance of hemodynamic factors to perioperative ischemic complications in childhood moyamoya disease. *Neurosurgery* 38: 1120–1126, 1996
  - 9) Kawaguchi T, Fujita S, Hosoda K, Shose Y, Hamano S, Iwakura M, Tamaki N: Multiple burr-hole operation for adult moyamoya disease. *J Neurosurg* 84: 468–476, 1996
  - 10) Kuroda S, Houkin K, Kamiyama H, Abe H, Mitsumori K: Regional cerebral hemodynamics in childhood moyamoya disease. *Childs Nerv Syst* 11: 584–590, 1995
  - 11) Matsushima T, Inoue T, Suzuki SO, Fujii K, Fukui M, Hasuo K: Surgical treatment of moyamoya disease in pediatric patients—comparison between the results of indirect and direct revascularization procedures. *Neurosurgery* 31: 401–405, 1992
  - 12) Matsushima Y, Aoyagi M, Nariai T, Takada Y, Wakimoto H, Ohki J, Akimoto H, Srivatanakul K, Hirakawa K: [Long-term prognosis of intelligence in childhood moyamoya patients evaluated by Wechsler tests: II. Childhood moyamoya patients who underwent encephalo-duro-arterio-synangiosis (EDAS) more than 10 years previously]. *Shoni No Noshinkei* 21: 232–238, 1996 (Japanese)
  - 13) Miyamoto S, Nagata I, Karasawa J, Kikuchi H, Akiyama Y, Nozaki K, Hashimoto N: [Surgical treatment for moyamoya disease. Long-term prognosis after direct bypass in moyamoya disease]. *No Socchu No Geka* 28: 111–114, 2000 (Japanese)
  - 14) Mizoi K, Kayama T, Yoshimoto T, Nagamine Y: Indirect revascularization for moyamoya disease: is there a beneficial effect for adult patients? *Surg Neurol* 45: 541–549, 1996
  - 15) Morimoto M, Iwama T, Hashimoto N, Kojima A, Hayashida K: Efficacy of direct revascularization in adult Moyamoya disease: haemodynamic evaluation by positron emission tomography. *Acta Neurochir (Wien)* 141: 377–384, 1999
  - 16) Scott RM, Smith JL, Robertson RL, Madsen JR, Soriano SG, Rockoff MA: Long-term outcome in children with moyamoya syndrome after cranial revascularization by pial synangiosis. *J Neurosurg* 100: 142–149, 2004

## Medical Treatment

### 1. Recommendations

Oral administration of antiplatelet agents is recommended as a medical treatment for moyamoya disease, however, adequate scientific evidence for this recommendation is still lacking (Appendix 1, recommendation grade C1).

### 2. Explanation

The medical treatment of moyamoya disease is roughly classified into treatment for the acute phase of stroke, treatment for preventing recurrence in the chronic phase of stroke, and treatment of asymptomatic moyamoya disease.

#### 2-1. Acute phase

Intravenous tissue plasminogen activator (tPA) therapy is contraindicated for moyamoya disease manifesting as cerebral ischemia (“Guidelines for Proper Treatment with Intravenous tPA (Alteplase) Therapy” by the Japan Stroke Society).<sup>4)</sup> In adult patients with moyamoya disease manifesting as cerebral infarction, the use of edaravone, a cerebroprotective agent, and of antithrombotic drugs such as ozagrel, argatroban, aspirin, and heparin has been recommended, as specified for the treatment of atherothrombotic cerebral infarction.<sup>5)</sup> Although there is only insufficient evidence, these drugs are considered to be effective in patients with cerebral infarction caused by moyamoya disease (Appendix 1, evidence level III). For patients with large infarcts causing cerebral edema and intracranial hypertension, glycerol is reportedly effective (evidence level III). Furthermore, supportive treatment, such as antipyretics for fever, anticonvulsants for convulsions, adequate control of blood sugar, oxygen supplementation for maintenance of arterial oxygen saturation, and prophylactic administration of antiulcer agents for severe cases, is consi-

dered to be important in patients in the acute phase of cerebral infarction in general (evidence level III). When mechanical ventilatory support is necessary, the partial pressure of carbon dioxide in the arterial blood should be kept above 40 mmHg. In regard to blood pressure control, as in the treatment of other cerebral infarction, the blood pressure should not be lowered during the acute phase, as a rule (evidence level III).

Treatment of moyamoya disease manifesting as cerebral infarction in children has rarely been reported. Antiplatelet therapy with aspirin (1 to 5 mg/kg) has been reported to be effective (evidence level III). Similar to the case in adult patients with moyamoya disease manifesting as ischemia, administration of edaravone, a cerebroprotective agent, and of ozagrel and argatroban, antithrombotic drugs, can be considered for pediatric patients. Anticonvulsants should be used for the treatment of convulsions. The use of aspirin can be considered while keeping in mind that it may increase the risk of development of Reye's syndrome in pediatric patients.<sup>1,7)</sup>

For adult patients with moyamoya disease manifesting as bleeding, antihypertensive therapy is likely to be effective, in accordance with the treatment of cerebral hemorrhage, when the systolic blood pressure is  $\geq 180$  mmHg, diastolic blood pressure is  $\geq 105$  mmHg, or the mean blood pressure is  $\geq 130$  mmHg. Any antiplatelets in use should be discontinued, any anticoagulant therapy should be immediately stopped, and the use of vitamin K and blood products (fresh frozen plasma and factor IX complex) should be considered (evidence level III).

## 2-2. Prevention of recurrence in the chronic phase

The indications of surgical treatment for the prevention of recurrence should be examined first in patients with moyamoya disease manifesting with cerebral ischemic attack. Medically, oral administration of aspirin is recommended, but attention is required, because long-term aspirin treatment may convert the disease type from ischemic to the hemorrhagic type (evidence level III). Whether or not regular follow up for the development of microbleeds using MRI T2\* might be effective for the prevention of bleeding is a topic that needs to be examined in the future.<sup>2)</sup> When patients cannot tolerate aspirin, or aspirin does not appear to be beneficial for the ischemic attack, use of clopidogrel, a thienopyridine drug, is recommended. Clopidogrel also has good tolerability and safety profiles in children.<sup>6)</sup> However, long-term combination of aspirin and clopidogrel is believed to increase the risk of bleed-

ing complications. Especially, in patients with severe moyamoya disease showing marked cerebral atrophy, or the moyamoya vessels with weakened walls are present in abundance, combined use of two or more antiplatelet agents has been reported to elevate the risk of cerebral hemorrhage (evidence level III).<sup>6)</sup>

Risk factors for stroke should be managed in accordance with general cases: antihypertensive therapy for hypertension, lipid-lowering therapy for dyslipidemia, adequate blood sugar control for diabetes mellitus, smoking cessation, and weight reduction advice for obese people. In terms of lifestyle guidance, hyperventilation often induces the symptoms of moyamoya disease; therefore, pediatric patients should avoid hot meals (noodles, soup, etc.), strenuous exercise, playing wind instruments such as a flute, and blowing balloons (evidence level III). In infants, crying also induces symptoms, therefore crying should be avoided.

## 2-3. Medical management of asymptomatic moyamoya disease

Even asymptomatic patients diagnosed as having moyamoya disease are at an elevated risk of developing cerebrovascular events during follow up, regardless of whether the disease is the ischemic type or the hemorrhagic type.<sup>3)</sup> Unlike in quasi-moyamoya disease with underlying disease (e.g. atherosclerosis and angiitis), there are no effective procedures for preventing vascular lesions in patients with moyamoya disease of unknown cause; therefore, surgical treatment for the prevention of future stroke can be considered even in asymptomatic patients. Medically, the management of risk factors and lifestyle guidance should be implemented in accordance with the prevention of recurrence in the chronic phase (evidence level III). In adults, the use of antiplatelet agents should not be considered for asymptomatic patients, because nearly a half of the patients with moyamoya disease suffer bleeding.

## References

- 1) DeVeber G: In pursuit of evidence-based treatments for paediatric stroke: the UK and Chest guidelines. *Lancet Neurol* 4: 432-436, 2005
- 2) Kikuta K, Takagi Y, Nozaki K, Hanakawa T, Okada T, Mikuni N, Miki Y, Fushimi Y, Yamamoto A, Yamada K, Fukuyama H, Hashimoto N: Asymptomatic microbleeds in moyamoya disease: T2\*-weighted gradient-echo magnetic resonance imaging study. *J Neurosurg* 102: 470-475, 2005
- 3) Kuroda S, Hashimoto N, Yoshimoto T, Iwasaki Y: Radiological findings, clinical course, and outcome in asymptomatic moyamoya disease: results of multicenter survey in Japan. *Stroke* 38: 1430-1435, 2007



- 4) Members of Subcommittee for Guidelines for Intravenous tPA (Alteplase) Therapy, Committee for Medical Improvement and Social Insurance Japan Stroke Society (Subcommittee Leader: Yamaguchi T): [Guidelines for proper treatment with intravenous tPA (alteplase) therapy. Oct. 2005]. *Nosotchu* 27: 327-354, 2005 (Japanese)
- 5) Shinohara Y, Yoshimoto T, Fukuuchi Y, Ishigami S (eds); Committee for Japanese Guidelines for the Management of Stroke: [*Japanese Guidelines for the Management of Stroke 2004*]. Tokyo, Kyowa Kikaku, 2004 (Japanese)
- 6) Soman T, Rafay MF, Hune S, Allen A, MacGregor D, deVeber G: The risks and safety of clopidogrel in pediatric arterial ischemic stroke. *Stroke* 37: 1120-1122, 2006
- 7) Toriyama T, Kageyama M, Kimura F, Yamada T, Ishibashi A: [Post-marketing surveillance on edaravone (Radicut Inj. 30 mg) for cerebral infarction in children]. *Shonika Rinsho* 61: 155-164, 2008 (Japanese)

## Treatment for Patients With Moyamoya Disease Manifesting as Hemorrhage

### 1. Recommendations

Revascularization can be considered for patients with hemorrhagic-type moyamoya disease, but adequate scientific evidence is still lacking (Appendix 1, recommendation grade C1).

### 2. Explanation

Intracranial bleeding in patients with moyamoya disease is the most significant factor worsening the survival and functional prognosis of the patients<sup>3)</sup> (Appendix 1, evidence level III). Hemorrhage is assumed to be caused by collapse of the dilated vessels of the collateral circulation (moyamoya vessels), due to hemodynamic loading and rupture of the peripheral aneurysms often formed on moyamoya vessels. The rebleeding rate in patients with hemorrhagic-type moyamoya disease is reportedly 7.09%/year<sup>7)</sup> (evidence level III).

No treatment policy for the prevention of rebleeding has yet been established. Cerebral angiography performed after direct revascularization in patients with moyamoya disease has shown reduction in the number of moyamoya vessels and/or disappearance of the peripheral aneurysm<sup>4,8)</sup> (evidence level III). Based on the assumption that the hemodynamic loading on these collateral vessels is reduced, it has been hypothesized that direct revascularization may prevent or reduce the incidence of rebleeding. In patients with ischemic-type moyamoya disease undergoing direct revascularization, the frequency of conversion to the hemorrhagic type of the disease on long-term follow up has been reported to be reduced

as compared with that in patients treated conservatively<sup>10)</sup> (evidence level III).

It has been reported that the rebleeding rate is significantly lower in patients with hemorrhagic-type moyamoya disease undergoing revascularization procedures as compared with that in patients receiving only conservative medical treatment<sup>5)</sup> (evidence level III); there are other reports suggesting that the frequency of rebleeding and ischemic attacks is significantly decreased after direct revascularization in patients with hemorrhagic-type moyamoya disease<sup>6,11)</sup> (evidence level III). On the other hand, there are also a number of reports denying the beneficial effect of revascularization for the prevention of rebleeding<sup>2,12,13)</sup> (evidence level III). It has been reported that the effect of indirect revascularization on hemorrhagic-type moyamoya disease is inferior to that on the ischemic type of the disease, and that neovascularization or a decrease in the number of moyamoya vessels cannot be achieved in many cases<sup>1)</sup> (evidence level III). However, a beneficial effect of revascularization on the prevention of cerebrovascular events, including ischemic attacks, has been reported in patients with hemorrhagic-type moyamoya disease<sup>6)</sup>; thus, it appears that revascularization may be more effective for hemorrhagic-type moyamoya disease patients with ischemic attacks.

A randomized, controlled trial (RCT) to demonstrate the effect of direct revascularization on the prevention of rebleeding in patients with moyamoya disease was initiated in Japan in 2001, and is currently ongoing (JAM Trial)<sup>10)</sup> (evidence level Ib). The JAM Trial is a multicenter study in which patients with hemorrhagic-type moyamoya disease are randomly assigned to a group undergoing direct bilateral revascularization of the cerebral hemispheres or a group administered only conservative medical treatment, and then the patients of both groups are followed up for at least 5 years.

### References

- 1) Aoki N: Cerebrovascular bypass surgery for the treatment of Moyamoya disease: unsatisfactory outcome in the patients presenting with intracranial hemorrhage. *Surg Neurol* 40: 372-377, 1993
- 2) Fujii K, Ikezaki K, Irikura K, Miyasaka Y, Fukui M: The efficacy of bypass surgery for the patients with hemorrhagic moyamoya disease. *Clin Neurol Neurosurg* 99 Suppl 2: S194-195, 1997
- 3) Han DH, Kwon OK, Byun BJ, Choi BY, Choi CW, Choi JU, Choi SG, Doh JO, Han JW, Jung S, Kang SD, Kim DJ, Kim HI, Kim HD, Kim MC, Kim SC, Kim SC, Kim Y, Kwun BD, Lee BG, Lim YJ, Moon JG, Park HS, Shin MS, Song JH, Suk JS, Yim MB; Korean Society for Cerebrovascular Disease: A co-operative

- study: clinical characteristics of 334 Korean patients with moyamoya disease treated at neurosurgical institutes (1976–1994). The Korean Society for Cerebrovascular Disease. *Acta Neurochir (Wien)* 142: 1263–1274, 2000
- 4) Houkin K, Kamiyama H, Abe H, Takahashi A, Kuroda S: Surgical therapy for adult moyamoya disease. Can surgical revascularization prevent the recurrence of intracerebral hemorrhage? *Stroke* 27: 1342–1346, 1996
  - 5) Karasawa J, Hosoi K, Morisako T: [Revascularization for hemorrhagic Moyamoya disease], in: [Research Committee on Spontaneous Occlusion of the Circle of Willis (Moyamoya Disease) of the Ministry of Health, Labour and Welfare Annual Report 2000]. 2001, pp 55–58 (Japanese)
  - 6) Kawaguchi S, Okuno S, Sakaki T: Effect of direct arterial bypass on the prevention of future stroke in patients with the hemorrhagic variety of moyamoya disease. *J Neurosurg* 93: 397–401, 2000
  - 7) Kobayashi E, Saeki N, Oishi H, Hirai S, Yamaura A: Long-term natural history of hemorrhagic moyamoya disease in 42 patients. *J Neurosurg* 93: 976–980, 2000
  - 8) Kuroda S, Houkin K, Kamiyama H, Abe H: Effects of surgical revascularization on peripheral artery aneurysms in moyamoya disease: report of three cases. *Neurosurgery* 49: 463–468, 2001
  - 9) Miyamoto S: Study design for a prospective randomized trial of extracranial-intracranial bypass surgery for adults with moyamoya disease and hemorrhagic onset—the Japan Adult Moyamoya Trial Group. *Neurol Med Chir (Tokyo)* 44: 218–219, 2004
  - 10) Miyamoto S, Akiyama Y, Nagata I, Karasawa J, Nozaki K, Hashimoto N, Kikuchi H: Long-term outcome after STA-MCA anastomosis for moyamoya disease. *Neurosurg Focus* 5(5): e5, 1998
  - 11) Nakagawa I, Kawaguchi S, Iida J, Sakaki T: [Direct bypass of STA-MCA anastomosis prevents future stroke in patients with the hemorrhagic type of moyamoya disease]. *No Socchu No Geka* 32: 416–420, 2004 (Japanese)
  - 12) Suzuki S, Maeyama R, Nagatomi H, Kuromatsu C, Ito M, Matsunaga M, Matsuno H, Matsubara T, Kamikaseda K: [Surgical treatment for adult patients with moyamoya disease. With special reference to hemorrhagic type]. *No Socchu No Geka* 20: 463–467, 1992 (Japanese)
  - 13) Yoshida Y, Yoshimoto T, Shirane R, Sakurai Y: Clinical course, surgical management, and long-term outcome of moyamoya patients with rebleeding after an episode of intracerebral hemorrhage: An extensive follow-up study. *Stroke* 30: 2272–2276, 1999

## CHAPTER VIII: PROGNOSIS (NATURAL HISTORY)

### Pediatric Moyamoya Disease

Episodes of transient cerebral ischemia occur most frequently a few years after the onset of moyamoya disease, thereafter the frequency usually decreases. However, the frequency increases with time after the disease onset in patients with intellectual disturbance and dysfunction, and the severity also deteriorates.<sup>31)</sup> In younger infants, cerebral infarction, especially cortical infarction, occurs often, and the presence/absence of cerebral infarction is assumed to be the most important factor associated with the functional prognosis.<sup>16,20,30)</sup> In children, the disease stage progresses in many patients, but the speed of progression becomes gradual during puberty.<sup>2,3)</sup> It has been reported that during long-term follow up, unilateral lesions often change to bilateral lesions, and that TIA arising from the cerebral hemispheres occurs in 65% of patients who were originally asymptomatic.<sup>37)</sup> When the disease persists until adulthood, the ADL is favorable in only a small number of patients,<sup>12)</sup> and intracranial hemorrhage may result in death in a few patients.<sup>2,43)</sup>

There are no reported RCTs conducted to examine the effect of cerebral revascularization. However, following cerebral revascularization, it is assumed that the TIAs would decrease in frequency

or disappear altogether, that recurrent cerebral infarction would be quite rare regardless of the surgical procedure employed, and that the functional prognosis would be better as compared with that in untreated patients.<sup>1,5,9,14,16,26,27,34,35,40,41)</sup> Cerebral revascularization has been shown to result in a reduced frequency/severity of headache, but it has also been reported that even after surgery, irrespective of the improvement of the cerebral circulatory dynamics, headache may persist or even appear anew.<sup>32,42)</sup> Higher brain functions are also an important factor influencing the prognosis, and decrease in the intelligence quotient often becomes evident 5 years or more after the disease onset.<sup>11)</sup> Cerebral revascularization is believed to improve the intellectual prognosis.<sup>33)</sup>

### Adult Moyamoya Disease

A higher recurrence rate of cerebrovascular events and a poorer prognosis have been reported in adult patients with untreated moyamoya disease than in those undergoing surgical treatment, regardless of the disease type manifested at the initial attack.<sup>6,7)</sup> As for the case of pediatric patients, cerebral revascularization should be considered.

In recent years, disease progression has been

found to be more frequent than previously assumed.<sup>8,10,17,18)</sup> Irrespective of the symptomatic/asymptomatic status of the patients or of a definitive/probable diagnosis, disease progression has been reported to occur in approximately 20% of the cases in the non-surgically treated hemisphere, and TIA/cerebral infarction or intracranial hemorrhage has been reported to occur in about half of the cases. Disease progression is known to be more likely to occur in women.<sup>29)</sup> With regard to the complications during pregnancy and delivery in women with moyamoya disease, serious stroke events, such as intracranial hemorrhage, have been reported to occur occasionally. Evidence-based management policies have not yet been established. Rigorous management during pregnancy, delivery, and puerperium in an environment of active collaboration between the obstetrician and neurosurgeon is recommended.<sup>24,44)</sup>

### 1. Adult ischemic-type moyamoya disease

As for the case of children with the disease, there are no RCTs conducted to examine the efficacy of cerebral revascularization in adult patients with moyamoya disease. A marked decrease in the frequency of TIA and cerebral infarction has been reported after cerebral revascularization. Nonetheless, intracranial hemorrhage and cerebral infarction attributable to disease progression in the non-surgically treated hemisphere may occur in a few patients during the follow-up period; therefore, long-term follow up is believed to be important after surgery for ensuring that a good prognosis is maintained.<sup>19,23,26,39,45)</sup>

### 2. Adult hemorrhagic-type moyamoya disease

The estimated mortality of patients presenting with intracranial hemorrhage at the initial attack ranges from 6.8% to 20%. Rebleeding worsens the functional prognosis and increases the mortality.<sup>21,47)</sup> Rebleeding may occur at the same site as that in the initial episode, or at a different site.<sup>15)</sup>

It has been reported that following conservative treatment, rebleeding may occur 2 to 20 years after the initial bleeding in 30% to 65% of the patients, and that the incidence tends to increase with increasing duration of the follow-up period.<sup>4,21,22,36,47)</sup> The risk of rebleeding is reportedly higher in patients with abnormal dilation of the anterior choroidal artery or posterior communicating artery branches.<sup>13,36)</sup> The disappearance of aneurysms formed in moyamoya vessels after cerebral revascularization has also been reported.<sup>28)</sup>

The effect of revascularization on the prevention of rebleeding is unknown at present. However, long-

term follow up is considered to be essential, regardless of whether or not a patient has been treated by cerebral revascularization.

## Asymptomatic Moyamoya Disease

In recent years, with the advances and spread of non-invasive diagnostic imaging, the number of patients diagnosed as having moyamoya disease even before the onset of symptoms has been growing. A recent follow-up investigation by the Research Committee revealed that the disease progresses with age, and that as many as 20% and 40% of patients with cerebral infarction and cerebral circulatory disturbance, respectively, are at high risk for cerebral ischemia.<sup>25)</sup>

The prognosis of asymptomatic moyamoya disease remains unknown for the most part. According to a previous report, 4 of 33 patients developed TIA, and 2 patients died of intracranial hemorrhage,<sup>46)</sup> and 1 of 10 patients developed cerebral infarction with the progression of the disease.<sup>38)</sup> In a recent follow-up investigation, the disease progressed in 5 of 34 untreated patients, and the risks of cerebral infarction and intracranial hemorrhage were reported to be 3.2%/year. While cerebral infarction occurred more frequently in patients found to have cerebral ischemia on medical examination, no cerebrovascular events reportedly occurred in 6 patients who underwent cerebral revascularization.<sup>25)</sup> Therefore, patients with asymptomatic moyamoya disease are also considered to be potentially at risk for cerebrovascular events. When the disease is conservatively followed up, careful long-term observation of the course using MRI/MRA is considered to be necessary.

### References

- 1) Chiu D, Shedden P, Bratina P, Grotta JC: Clinical features of moyamoya disease in the United States. *Stroke* 29: 1347-1351, 1998
- 2) Ezura M, Yoshimoto T, Fujiwara S, Takahashi A: [Long-term follow-up of moyamoya disease (5 to 27 years)]. *Shoni No Noshinkei* 18: 461-465, 1993 (Japanese)
- 3) Ezura M, Yoshimoto T, Fujiwara S, Takahashi A, Shirane R, Mizoi K: Clinical and angiographic follow-up of childhood-onset moyamoya disease. *Childs Nerv Syst* 11: 591-594, 1995
- 4) Fujii K, Ikezaki K, Irikura K, Miyasaka Y, Fukui M: The efficacy of bypass surgery for the patients with hemorrhagic moyamoya disease. *Clin Neurol Neurosurg* 99 Suppl 2: S194-195, 1997
- 5) Golby AJ, Marks MP, Thompson RC, Steinberg GK: Direct and combined revascularization in pediatric moyamoya disease. *Neurosurgery* 45: 50-60, 1999

- 6) Hallemeier CL, Rich KM, Grubb RL Jr, Chicoine MR, Moran CJ, Cross DT 3rd, Zipfel GJ, Dacey RG Jr, Derdeyn CP: Clinical features and outcome in North American adults with moyamoya phenomenon. *Stroke* 37: 1490-1496, 2006
- 7) Han DH, Kwon OK, Byun BJ, Choi BY, Choi CW, Choi JU, Choi SG, Doh JO, Han JW, Jung S, Kang SD, Kim DJ, Kim HI, Kim HD, Kim MC, Kim SC, Kim SC, Kim Y, Kwun BD, Lee BG, Lim YJ, Moon JG, Park HS, Shin MS, Song JH, Suk JS, Yim MB; Korean Society for Cerebrovascular Disease: A co-operative study: clinical characteristics of 334 Korean patients with moyamoya disease treated at neurosurgical institutes (1976-1994). *The Korean Society for Cerebrovascular Disease. Acta Neurochir (Wien)* 142: 1263-1274, 2000
- 8) Houkin K, Abe H, Yoshimoto T, Takahashi A: Is "unilateral" moyamoya disease different from moyamoya disease? *J Neurosurg* 85: 772-776, 1996
- 9) Houkin K, Ishikawa T, Yoshimoto T, Abe H: Direct and indirect revascularization for moyamoya disease surgical techniques and peri-operative complications. *Clin Neurol Neurosurg* 99 Suppl 2: S142-145, 1997
- 10) Ikezaki K, Inamura T, Kawano T, Fukui M: Clinical features of probable moyamoya disease in Japan. *Clin Neurol Neurosurg* 99 Suppl 2: S173-177, 1997
- 11) Imaizumi C, Imaizumi T, Osawa M, Fukuyama Y, Takeshita M: Serial intelligence test scores in pediatric moyamoya disease. *Neuropediatrics* 30: 294-299, 1999
- 12) Imaizumi T, Hayashi K, Saito K, Osawa M, Fukuyama Y: Long-term outcomes of pediatric moyamoya disease monitored to adulthood. *Pediatr Neurol* 18: 321-325, 1998
- 13) Irikura K, Miyasaka Y, Kurata A, Tanaka R, Fujii K, Yada K, Kan S: A source of haemorrhage in adult patients with moyamoya disease: the significance of tributaries from the choroidal artery. *Acta Neurochir (Wien)* 138: 1282-1286, 1996
- 14) Ishikawa T, Houkin K, Kamiyama H, Abe H: Effects of surgical revascularization on outcome of patients with pediatric moyamoya disease. *Stroke* 28: 1170-1173, 1997
- 15) Iwama T, Morimoto M, Hashimoto N, Goto Y, Todaoka T, Sawada M: Mechanism of intracranial rebleeding in moyamoya disease. *Clin Neurol Neurosurg* 99 Suppl 2: S187-190, 1997
- 16) Karasawa J, Touho H, Ohnishi H, Miyamoto S, Kikuchi H: Long-term follow-up study after extracranial-intracranial bypass surgery for anterior circulation ischemia in childhood moyamoya disease. *J Neurosurg* 77: 84-89, 1992
- 17) Kawano T, Fukui M, Hashimoto N, Yonekawa Y: Follow-up study of patients with "unilateral" moyamoya disease. *Neurol Med Chir (Tokyo)* 34: 744-747, 1994
- 18) Kelly ME, Bell-Stephens TE, Marks MP, Do HM, Steinberg GK: Progression of unilateral moyamoya disease: A clinical series. *Cerebrovasc Dis* 22: 109-115, 2006
- 19) Kim DS, Yoo DS, Huh PW, Kang SG, Cho KS, Kim MC: Combined direct anastomosis and encephaloduroarteriogaleosynangiosis using inverted superficial temporal artery-galeal flap and superficial temporal artery-galeal pedicle in adult moyamoya disease. *Surg Neurol* 66: 389-395, 2006
- 20) Kim SK, Seol HJ, Cho BK, Hwang YS, Lee DS, Wang KC: Moyamoya disease among young patients: its aggressive clinical course and the role of active surgical treatment. *Neurosurgery* 54: 840-846, 2004
- 21) Kobayashi E, Saeki N, Oishi H, Hirai S, Yamaura A: Long-term natural history of hemorrhagic moyamoya disease in 42 patients. *J Neurosurg* 93: 976-980, 2000
- 22) Kohno K, Nagato S, Oka Y, Ohue S, Nakagawa K, Ohta S, Kumon Y, Sakaki S: [Evaluation of long-term prognosis and cerebral blood flow in adult patients with moyamoya disease with and without vascular reconstructive surgery]. *No Shinkei Geka Journal* 6: 456-463, 1997 (Japanese)
- 23) Kohno K, Oka Y, Kohno S, Ohta S, Kumon Y, Sakaki S: Cerebral blood flow measurement as an indicator for an indirect revascularization procedure for adult patients with moyamoya disease. *Neurosurgery* 42: 752-758, 1998
- 24) Komiyama M, Yasui T, Kitano S, Sakamoto H, Fujitani K, Matsuo S: Moyamoya disease and pregnancy: case report and review of the literature. *Neurosurgery* 43: 360-369, 1998
- 25) Kuroda S, Hashimoto N, Yoshimoto T, Iwasaki Y: Radiological findings, clinical course, and outcome in asymptomatic moyamoya disease: results of multicenter survey in Japan. *Stroke* 38: 1430-1435, 2007
- 26) Kuroda S, Houkin K, Ishikawa T, Nakayama N, Nanba R, Kamiyama H, Nakagawa Y, Iwasaki Y, Abe H: [Overall outcome after surgical revascularization in childhood and adult moyamoya disease]. *No Socchu No Geka* 30: 369-374, 2002 (Japanese)
- 27) Kuroda S, Houkin K, Ishikawa T, Takahashi A, Kamiyama H, Nakagawa Y, Abe H: [Long-term outcome after surgical revascularization in childhood moyamoya disease]. *No Socchu No Geka* 28: 421-426, 2000 (Japanese)
- 28) Kuroda S, Houkin K, Kamiyama H, Abe H: Effects of surgical revascularization on peripheral artery aneurysms in moyamoya disease: report of three cases. *Neurosurgery* 49: 463-468, 2001
- 29) Kuroda S, Ishikawa T, Houkin K, Nanba R, Hokari M, Iwasaki Y: Incidence and clinical features of disease progression in adult moyamoya disease. *Stroke* 36: 2148-2153, 2005
- 30) Kuroda S, Nanba R, Ishikawa T, Houkin K, Kamiyama H, Iwasaki Y: [Clinical manifestations of infantile moyamoya disease]. *No Shinkei Geka* 31: 1073-1078, 2003 (Japanese)
- 31) Kurokawa T, Tomita S, Ueda K, Narazaki O, Hanai T, Hasuo K, Matsushima T, Kitamura K: Prognosis of occlusive disease of the circle of Willis (moyamoya disease) in children. *Pediatr Neurol* 1: 274-277, 1985

- 32) Matsushima Y, Aoyagi M, Nariai T, Nojiri T, Ohno K: [Headache in pediatric moyamoya patients: pre- and postoperative changes]. *Shoni No Noshinkei* 25: 442-447, 2000 (Japanese)
- 33) Matsushima Y, Aoyagi M, Nariai T, Takada Y, Hirakawa K: Long-term intelligence outcome of post-encephalo-duro-arterio-synangiosis childhood moyamoya patients. *Clin Neurol Neurosurg* 99 Suppl 2: S147-150, 1997
- 34) Miyamoto S, Akiyama Y, Nagata I, Karasawa J, Nozaki K, Hashimoto N, Kikuchi H: Long-term outcome after STA-MCA anastomosis for moyamoya disease. *Neurosurg Focus* 5(5): e5, 1998
- 35) Miyamoto S, Nagata I, Karasawa J, Kikuchi H, Akiyama Y, Nozaki K, Hashimoto N: [Long-term prognosis after direct bypass in moyamoya disease (<Topics> Surgical treatment for moyamoya disease)]. *No Socchu No Geka* 28: 111-114, 2000 (Japanese)
- 36) Morioka M, Hamada J, Todaka T, Yano S, Kai Y, Ushio Y: High-risk age for rebleeding in patients with hemorrhagic moyamoya disease: long-term follow-up study. *Neurosurgery* 52: 1049-1055, 2003
- 37) Nagata S, Matsushima T, Morioka T, Matsukado K, Mihara F, Sasaki T, Fukui M: Unilaterally symptomatic moyamoya disease in children: long-term follow-up of 20 patients. *Neurosurgery* 59: 830-837, 2006
- 38) Nanba R, Kuroda S, Takeda M, Shichinohe H, Nakayama N, Ishikawa T, Houkin K, Iwasaki Y: [Clinical features and outcomes of 10 asymptomatic adult patients with moyamoya disease]. *No Shinkei Geka* 31: 1291-1295, 2003 (Japanese)
- 39) Okada Y, Shima T, Nishida M, Yamane K, Yamada T, Yamanaka C: Effectiveness of superficial temporal artery-middle cerebral artery anastomosis in adult moyamoya disease: cerebral hemodynamics and clinical course in ischemic and hemorrhagic varieties. *Stroke* 29: 625-630, 1998
- 40) Sainte-Rose C, Oliveira R, Puget S, Beni-Adani L, Boddaert N, Thorne J, Wray A, Zerah M, Bourgeois M: Multiple bur hole surgery for the treatment of moyamoya disease in children. *J Neurosurg* 105: 437-443, 2006
- 41) Scott RM, Smith JL, Robertson RL, Madsen JR, Soriano SG, Rockoff MA: Long-term outcome in children with moyamoya syndrome after cranial revascularization by pial synangiosis. *J Neurosurg* 100: 142-149, 2004
- 42) Seol HJ, Wang KC, Kim SK, Hwang YS, Kim KJ, Cho BK: Headache in pediatric moyamoya disease: review of 204 consecutive cases. *J Neurosurg* 103: 439-442, 2005
- 43) Suzuki S, Maeyama R, Nagatomi H, Kuromatsu C, Ito M, Matsunaga M, Matsuno H, Matsubara T, Kamikaseda K: [Surgical treatment for adult patients with moyamoya disease. With special reference to hemorrhagic type]. *No Socchu No Geka* 20: 463-467, 1992 (Japanese)
- 44) Takahashi J, Ikeda T, Iihara K, Miyamaoto S: [A nationwide survey on pregnancy and delivery management in association with moyamoya disease (<Special issue> Management of pregnancy and delivery in neurosurgical patients)]. *No Shinkei Geka Journal* 18: 367-375, 2009 (Japanese)
- 45) Wanifuchi H, Takeshita M, Izawa M, Aoki N, Kagawa M: Management of adult moyamoya disease. *Neurol Med Chir (Tokyo)* 33: 300-305, 1993
- 46) Yamada M, Fujii K, Fukui M: [Clinical features and outcomes in patients with asymptomatic moyamoya disease—from the results of nation-wide questionnaire survey]. *No Shinkei Geka* 33: 337-342, 2005 (Japanese)
- 47) Yoshida Y, Yoshimoto T, Shirane R, Sakurai Y: Clinical course, surgical management, and long-term outcome of moyamoya patients with rebleeding after an episode of intracerebral hemorrhage: An extensive follow-up study. *Stroke* 30: 2272-2276, 1999

### Appendix 1: Classification of Evidence Levels and Recommendation Grades in the Guidelines

#### Classification of evidence levels in the Guidelines

Evidence level	Contents
Ia	meta-analysis of RCTs (results of RCTs are practically consistent)
Ib	RCT
IIa	well-designed controlled study (non-randomized)
IIb	well-designed quasi-experimental study
III	well-designed non-experimental, descriptive study (comparison/correlation/case study)
IV	report/comments/experience of specialists

#### Classification of recommendation grades in the Guidelines

Recommendation grade	Contents
A	strongly recommended
B	recommended
C1	can be considered, but adequate scientific rationale lacking
C2	not recommendable because of absence of scientific rationale
D	not recommended

This classification is according to that adopted in the “2004 Guidelines for Stroke Treatment” by the Japan Stroke Society. RCT: randomized, controlled trial.

**Appendix 2: Precautions for the Use of the Guidelines**

- (1) The clinical condition needs to be assessed in individual patients, and the Guidelines are not uniformly applicable to all individual patients. Therefore, the judgment of the treating physician who most accurately understands the patient's clinical condition should be afforded priority in the management of patients with moyamoya disease.
- (2) The Guidelines should not be referred to without careful consideration, used as data for evaluation of medical examinations, or for medical accidents or lawsuits. Attention should be paid to the fact that the Guidelines include drugs not approved or therapies not authorized in Japan and drugs used for purposes other than the original intent.
- (3) The number of patients is small and the cause of moyamoya disease is still unknown. Therefore, there are many aspects of the disease that still remain unresolved and for which adequate amounts of evidence have not yet been collected. Therefore, it must be borne in mind while using the Guidelines that there may be many inaccuracies and that the contents may not always necessarily be up to date or the current best practice.

---

**Appendix 3: Research Committee on the Pathology and Treatment of Spontaneous Occlusion of the Circle of Willis; 2005 to 2008 Health Labour Sciences Research Grant for Research on Measures for Intractable Diseases**
**Chief Researcher:**

Nobuo HASHIMOTO, Department of Neurosurgery, Kyoto University Graduate School of Medicine  
(Current) National Cardiovascular Center

**Researchers:**

Teiji TOMINAGA, Department of Neurosurgery, Tohoku University Graduate School of Medicine  
 Susumu MIYAMOTO, Department of Neurosurgery, Kyoto University Graduate School of Medicine  
 Izumi NAGATA, Department of Neurosurgery, Nagasaki University Graduate School of Biomedical Sciences  
 Kiyohiro HOUKIN, Department of Neurosurgery, Hokkaido University Graduate School of Medicine  
 Norihiro SUZUKI, Department of Neurology, Keio University School of Medicine  
 Akio KOIZUMI, Department of Health and Environmental Sciences, Kyoto University, Graduate School of Medicine, School of Public Health  
 Shigeru NOGAWA, Department of Internal Medicine, Tokyo Dental College Ichikawa General Hospital  
 Jyoji NAKAGAWARA, Department of Neurosurgery, Nakamura Memorial Hospital  
 Kazuo KITAGAWA, Department of Neurology, Osaka University, Graduate School of Medicine  
 Satoshi KURODA, Department of Neurosurgery, Hokkaido University Graduate School of Medicine  
 Kenichiro KIKUTA, Department of Neurosurgery, Fukui University Graduate School of Medicine

**Research Collaborators:**

Miki FUJIMURA, Department of Neurosurgery, Sendai Medical Center  
 Jun TAKAHASHI, Department of Neurosurgery, Kyoto University, Graduate School of Medicine  
 Kentaro HAYASHI, Department of Neurosurgery, Nagasaki University Graduate School of Biomedical Sciences  
 Koichi OKI, Department of Neurology, Keio University School of Medicine  
 Haruhiko HOSHINO, Department of Neurology, Tokyo Saiseikai Central Hospital

**Secretariat:**

Yasushi TAKAGI, Department of Neurosurgery, Kyoto University Graduate School of Medicine